


# *European Journal of Musculoskeletal Diseases*



Dosso Dossi, *Apollo e Dafne*, 1525 circa, olio su tela 191x116 cm, Galleria Borghese, Roma (dettaglio).



Published by  
Biolife

[www.biolife-publisher.it](http://www.biolife-publisher.it)



---

Eur J Musculoskel Dis 2020 May-Aug issue 2

CONTENTS

<b>DIAGNOSIS AND SUBSEQUENT TREATMENT WITH OXYGENOZONE THERAPY OF BAASTRUP'S DISEASE.</b> M. Bonetti, G.M. Ottaviani, A. Fontana, G. Pellicanò, L. Della Gatta and M. Muto	49-54
<b>LINGUAL PASSIVE SELF-LIGATING STRAIGHT WIRE WITH SQUARE SLOT BRACKETS AND ACTIVE RETAINERS: COMPARISON BETWEEN LINGUAL ORTHODONTIC TECHNIQUES FOR THE RESOLUTION OF ANTERIOR DENTAL CROWDING.</b> A. Pinto, V. Mazzetti and A.M. Pujia	55-61
<b>THE PRECISION OF INDIRECT BONDING PERFORMED BY OPERATORS WITH DIFFERENT EXPERIENCE: A PROSPECTIVE STUDY.</b> M. Morini, B. Hadroviq and P. Carls.....	63-69
<b>ULTRASOUND EVALUATION OF BONE GROWTH IN ORTHODONTICS: A CONTROLLED CLINICAL TRIAL.</b> P. Caccianiga*, G. Caccianiga and A. Leonida.....	71-77
<b>EVALUATION OF PHONETIC ALTERATIONS IN PATIENTS TREATED WITH F22 ALIGNERS.</b> V. Falconi, L. Borgia and A. Beretta.....	79-84
<b>DESQUAMATIVE GINGIVITIS: A CASE REPORT.</b> F. Fiori.....	85-87
<b>SINUS FLOW: A MINIMALLY INVASIVE TECHNIQUE FOR CRESTAL ACCESS TO THE MAXILLARY SINUS.</b> M.A. Lopez and F. Altamura.....	89-93



Article

## DIAGNOSIS AND SUBSEQUENT TREATMENT WITH OXYGEN-OZONE THERAPY OF BAASTRUP'S DISEASE

M. Bonetti<sup>1</sup>, G.M. Ottaviani<sup>2</sup>, A. Fontanta<sup>1</sup>, G. Pellicano<sup>3</sup>, L. Della Gatta<sup>4</sup> and M. Muto<sup>4</sup>

<sup>1</sup>Neuroradiology Service, Clinical Institute, Città di Brescia, Brescia, Italy

<sup>2</sup>Department of Emergency and Urgency, Civil Hospitals of Brescia, Brescia, Italy

<sup>3</sup>Neuroradiology Service, A.O.U.C., Florence, Italy

<sup>4</sup>Department of Neuroradiology, Cardarelli Hospital, Naples Italy

†These authors contributed equally.

*Correspondence to:*

Matteo Bonetti, MD

Neuroradiology Service, Clinical Institute, Città di Brescia, Brescia, Italy

e-mail: dottorbonetti@gmail.com

### ABSTRACT

In recent years, several studies have demonstrated the utility of oxygen-ozone in reducing the size of herniated discs, proving the validity of this treatment on back pain due to hernias (1-19). In this study, the authors evaluate the therapeutic results obtained in the treatment of 56 patients suffering from non-discogenic low back pain caused by Baastrup's syndrome after radiological diagnostic confirmation by magnetic resonance imaging (MRI) completed with Fat / Sat sequences before and after administration of paramagnetic contrast (20-22).

**KEYWORDS:** *oxygenKE, ozone, ozone therapy, Baastrup's syndrome, Baastrup's disease, kissing spine syndrome*

### INTRODUCTION

The Baastrup's Syndrome described for the first time by Danish radiologist Christian Baastrup in 1933 - also known by the Anglo-Saxon term "kissing spines" - is characterized by the presence of arthrosis between the spinous processes of the vertebral column, which leads to the formation of real "neo-joints" (23-29). It is also often the cause of low back pain refractory to common treatments with anti-inflammatory and anti-pain drugs. It mainly affects women - with an F: M = 4: 1 ratio - and is usually diagnosed towards the third decade of age. The diagnosis is radiological: the standard X-ray shows an extreme hyperlordosis of the lumbar tract up to the mutual contact of the spinous processes and degeneration of the same (23-27) (Fig. 1).

The course of the disease is progressive, and in case of accentuation of the lumbago, it is indicated to complete the investigations with an MRI with Fat / Sat sequences and possible administration of gadolinium in order to highlight any inflammatory focal points in the acute phase (20-22) (Fig. 2 a, b).

Received: 02 April 2020

Accepted: 28 June 2020

ISSN: 2038-4106

Copyright © by BIOLIFE 2020

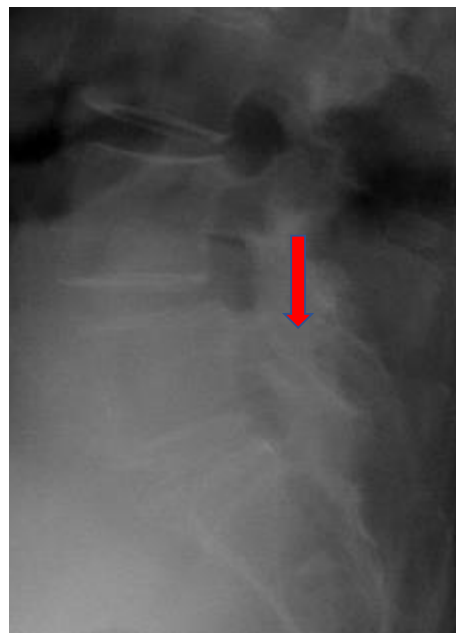
This publication and/or article is for individual use only and may not be further reproduced without written permission from the copyright holder. Unauthorized reproduction may result in financial and other penalties. **Disclosure: All authors report no conflicts of interest relevant to this article.**

A precise diagnosis conducted after careful, objective examination and supported by a precise evaluation using Nuclear Magnetic Resonance (MRI) is essential to establish the best possible therapy based on the severity and stage of progression of the disease.

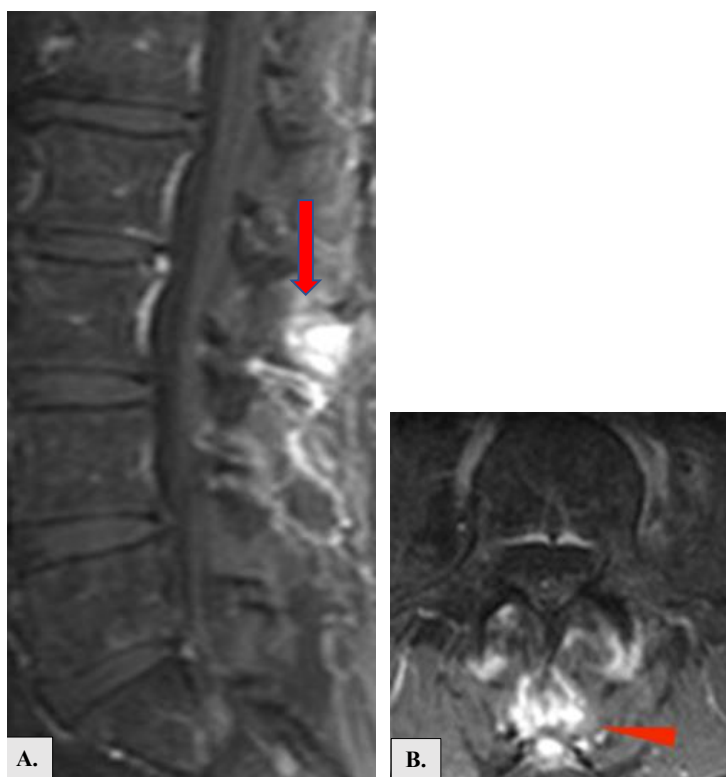Treatment for this disease usually involves two-stage therapy. The first stage consists of physiotherapy manipulation, which, with movements and massages, restores lordosis and stretches the degraded muscles. Physiotherapy is necessary to strengthen and stretch the muscles through decontracting massages, thermotherapy and targeted exercises. In this phase, painkillers, anti-inflammatories, and muscle relaxants could be administered to improve the effect of physiotherapy therapy. If all these treatments do not have an effect, it is necessary to proceed with classic surgery or through Interspinous Process Distraction (26).

Oxygen-ozone therapy was introduced in 1985 and has been widely proven as a valid method for the treatment of herniated discs (1-19). Over the years, numerous series have reported positive results ranging from 75% up to almost 90% in treating low back pain complicated or not by disc-radicular impingement sciatica due to disc herniation (1-19).

In this note, we report the results of the selected treatment of patients with low back pain not due to hernias and/or disc protrusions. We focused our attention on the pathology of the posterior compartment, which may be responsible for this symptomatology in Baastrup's Syndrome, pictures after diagnostic confirmation with lumbosacral MRI completed with Fat / Sat sequences before and after administration of paramagnetic contrast medium.



**Fig 1.** Standard X-Ray (LL view): Baastrup's Syndrome (arrow).



**Fig 2. a, b)** MRI sag. and ax. with Fat / Sat sequences after administration of paramagnetic contrast agent: inflammation of the interspinous ligament **a)**: arrow; **b)**: arrowhead.

## MATERIALS AND METHODS

In this study, we present the treatment with injections of a gaseous mixture of oxygen-ozone from January 2017 to February 2020 in 56 patients (38 F-18M, age 51/79 years). Targeted infiltrations were carried out with this therapy in patients suffering from Baastrup's Syndrome in the acute phase, subject to diagnostic confirmation by Magnetic Resonance (MRI) of the acute stage of the disease with evidence of pathological impregnation of contrast medium at the point of inflammation.

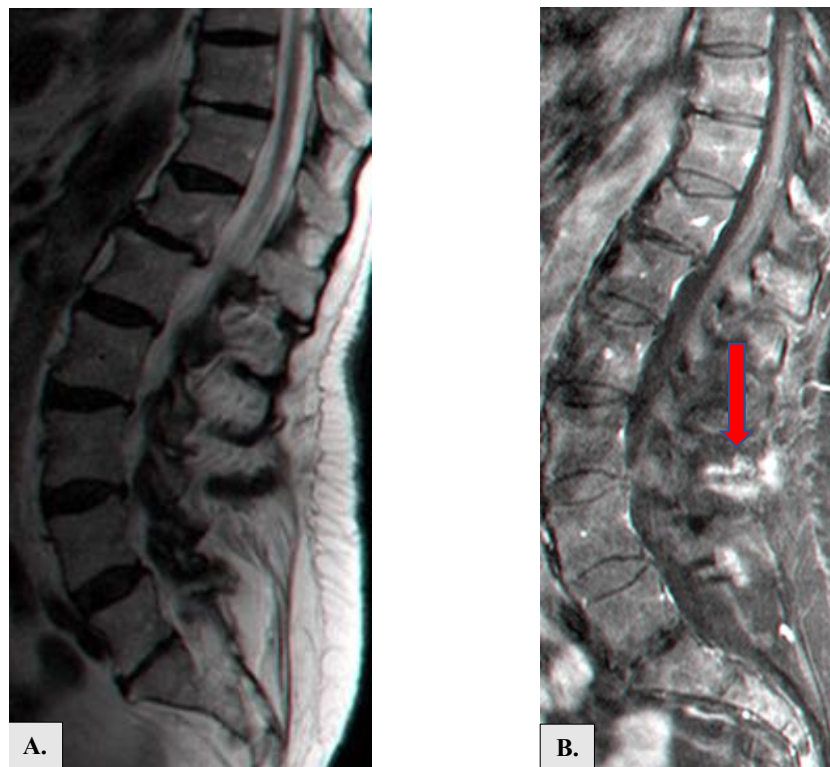In all 56 patients, the diagnosis of Baastrup's Syndrome to be treated was confirmed by magnetic resonance imaging (MRI). The MRI investigations were carried out with Siemens Magnetom AERA 1.5 T software SYNGO MR D13 at the Clinical Institute of the City of Brescia and the neuroradiology service of the Careggi Hospital in Florence. At the same time, a GE Healthcare Signa Voyager 1.5 T equipment was used in the neuroradiology department of the Cardarelli in Naples; all investigations were performed with standard sequences and then completed the examination with the use of Fat/Sat sequences without and with the administration of contrast medium (Fig. 3 a, b).

### *Infiltration technique*

All treatments were performed under CT guidance. After being informed about the procedure and possible complications, the patient signs the informed consent. Preliminary CT scans are performed with the patient prone to confirm the pathology and the level to be treated. At this point, the skin is disinfected using special preparations for general skin antisepsis (Citro jod 100 registration No. 1805 of the Ministry of Health based on iodine polyvinylpyrrolidone).

A preliminary CT scan is performed to identify the skin approach point. Local anaesthesia is performed with ethyl chloride spray, and then, again using the CT guide, a spinal needle is placed, typically using needles of varying calibre between 22 and 25 G. The perfect positioning of the needle in the interspinous space in the case of Baastrup's Syndrome is checked with a CT scan. A 10 ml syringe in polyethylene is then filled with the gaseous mixture at a 25 µg/ml concentration.

The gaseous mixture is then injected, generally injecting a variable volume from 3 ccs to 5 ccs of the O<sub>2</sub>-O<sub>3</sub> gaseous



**Fig. 3.** *A): MRI sag. T2 and Fat / Sat after contrast medium. B): after administration of contrast medium, impregnation is evident from the local inflammatory state of the interspinous ligament L3-L 4 (arrow).*

mixture. After the infiltration, other CT scans are performed to document the correct distribution of the gaseous mixture. All material used must be sterile and single-use (2, 7).

The 56 patients we treated had initially been diagnosed with the pathology by radiographs of the spine and subsequently confirmed with MRI without and with gadolinium with Fat/Sat sequences capable of documenting the inflammatory state at the level of the interspinous ligament. All the patients suffered from pain in the lower dorsal and lumbosacral tract, in which arthritic manifestations were advanced, and all showed an associated analgesic contracture of the paravertebral musculature.

Infiltrations of 4 cc of a gaseous mixture of oxygen-ozone at a concentration of 25  $\mu\text{g}$  / ml with 23 G needles were carried out in correspondence with the inflamed interspinous ligaments as documented by the MRI investigation, followed by intramuscular paravertebral infiltrations always at 25  $\mu\text{g}$  / ml in the tract affected by the disease. In 22 patients enrolled in our study (39.2%), we then performed a control MRI without and with the administration of an intravenous contrast medium between 15 days and one month from therapy.

## RESULTS

In all 56 cases, at the check-up carried out one week after treatment, all patients reported a clear improvement in painful symptoms, while 6 months later, all subjects showed a partial recrudescence of pain; 12 (21.4%) reported that the clinical picture had returned substantially similar to what was present at the beginning of treatment.

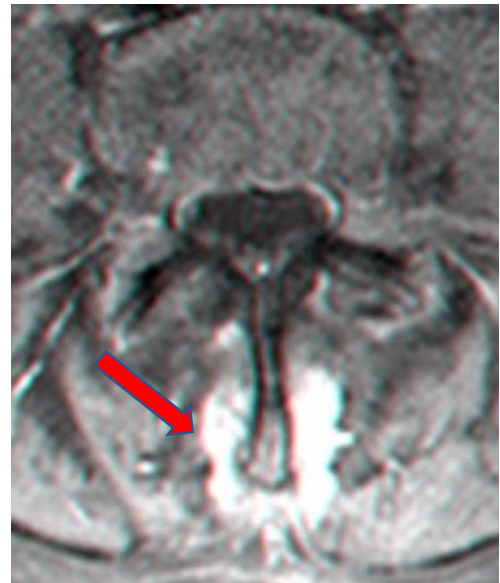Of the 56 patients treated, in the 22 in which we performed the control MRI with Fat/Sat sequences before and after administration of intravenous contrast medium in 18 (81.8%), the MRI allowed documenting the complete resolution of the inflammatory state of the interspinous ligament treated (Fig. 4, 5). In 23 cases (41.07%), it was decided to carry out a second treatment which immediately led to a clear reduction in painful symptoms.

In all the patients we treated, we were advised to follow a physiotherapy protocol for preventive purposes. In 18 cases (32.1%), the physiatrist colleague advised patients to include in their therapeutic path the possibility of performing thermal treatments; in particular, he advised carrying out cycles of balneo-mud therapy (1/2 times a year) to maintain the good therapeutic result obtained.

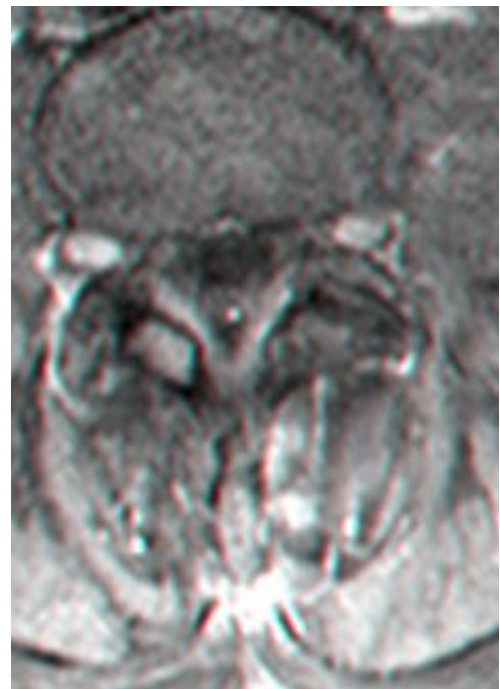
## DISCUSSION

Baastrup's syndrome (or lumbar interspinous arthrosis) consists of a degenerative process associated with the development of a pseudo-articulation between the spinous processes and the appearance of arthritic phenomena. It is defined as a particular variant of arthrosis in the axial plane.

It is a condition generated by mutual contact (of the adjacent spinous processes (hence the name of "Kissing spine syndrome")), which produces a mechanical overload and changes in the bone surfaces. It is observed more frequently



**Fig 4.** Baastrup's Syndrome: RM ax. Fat / sat after gadolinium before treatment. Inflammation of the interspinous ligament (arrow).



**Fig 5.** Baastrup's disease: RM ax. Fat / sat with gadolinium after treatment. Complete resolution of the inflammatory state of the interspinous ligament.

between the third, fourth, and fifth lumbar vertebrae (23-27). Based on our experience, the excellent therapeutic results obtained in patients suffering from Baastrup's Syndrome are undoubtedly attributable to the known mechanisms of action of the oxygen-ozone mixture at the site of the disease.

The oxygen-ozone gas mixture injected at this level exerts an important anti-inflammatory and analgesic action, also normalizing the level of cytokines and prostaglandins, increasing superoxide dismutase (SOD), minimizing reactive oxidant species (ROS), and improving local periganglionic circulation with a eutrophic effect (1-19). Oxygen-ozone therapy has, in fact, proved to be an effective therapeutic option in symptomatic treatment by acting mainly on pain but also muscle tone by reducing the analgesic contracture of the paravertebral muscles. In this group of patients, clinical benefit is obtained already with a single targeted treatment. In cases where the therapeutic result was poor or unsatisfactory, in addition to the intervention of the physiatrist colleague, a neurosurgical reassessment of the picture is also indispensable to decide whether an intervention is essential.

## CONCLUSION

In recent years, mainly thanks to the introduction of MR sequences with Fat Saturation and gadolinium in patients with degenerative disease of the lumbar spine and low back pain, Diagnostic imaging has become even more helpful to the clinician in making a natural diagnosis in order to decide then the best therapeutic strategy to be adopted based on the pathology to be treated.

In particular, in patients with non-radicular low back pain, this syndrome may arise from changes in the posterior elements of the lumbar spine (the "posterior vertebral compartment").

The correct selection of the patient allows, in most cases striking clinical results; in reference to our series of patients afflicted by Baastrup's Syndrome, we found optimal therapeutic results already with a single infiltration under CT control followed by intramuscular paravertebral treatment. The rapid resolution of pain (with no complications), the ease of performing the method, and the complete control of infiltration under CT control allow proposing CT-guided oxygen-ozone therapy as a viable alternative to the various treatments currently proposed for Baastrup's Syndrome. In consideration of these factors, it is safe to assume that it can also be proposed as a method of choice between conservative therapies. It is also important to underline that this therapy does not contraindicate other infiltrative or surgical therapies.

### *Conflict of interest*

The authors declare that they have no conflict of interest.

## REFERENCES

1. Andreula CF, Simonetti L, De Santis F, Agati R, Ricci R, Leonardi M. Minimally invasive oxygen-ozone therapy for lumbar disk herniation. *AJNR American journal of neuroradiology*. 2003;24(5):996-1000. <https://pubmed.ncbi.nlm.nih.gov/12748111/>
2. Bonetti M, Fontana A, Coticelli B, Volta GD, Guindani M, Leonardi M. Intraforaminal O(2)-O(3) versus periradicular steroidal infiltrations in lower back pain: randomized controlled study. *AJNR American journal of neuroradiology*. 2005;26(5):996-1000. <https://pubmed.ncbi.nlm.nih.gov/15891150/>
3. Bonetti M, Coticelli B, Raimondi D, Valdenassi L, Richelmi P, Bertè FA. Ossigeno-ozono terapia vs infiltrazioni epidurali cortisoniche. *Rivista di Neuroradiologia*. 2000;13:203-206.
4. Gallucci M, Limbucci N, Zugaro L, et al. Sciatica: treatment with intradiscal and intraforaminal injections of steroid and oxygen-ozone versus steroid only. *Radiology*. 2007;242(3):907-913. doi:10.1148/radiol.2423051934
5. Gualandi G, Bonetti M. Ossigeno-ozonoterapia nel trattamento della patologia dolorosa del rachide lombare: esperienza preliminare. *Acta Toxic Therap*. 1996;17(2-3):261-264.
6. Iliakis E. Ozone treatment in low back pain. *Orthopaedics*. 1995;1:29-33.
7. Iliakis E, Valadakis V, Vynios DH, Tsiganos CP, Agapitos E. Rationalization of the activity of medical ozone on intervertebral disc and histological and biochemical study. *Rivista di Neuroradiologia*. 2001;14(S1):25-30.

8. Lehnert T, Naguib NNN, Wutzler S, et al. Analysis of Disk Volume before and after CT-guided Intradiscal and Perianglionic Ozone–Oxygen Injection for the Treatment of Lumbar Disk Herniation. *Journal of Vascular and Interventional Radiology*. 2012;23(11):1430-1436. doi:10.1016/j.jvir.2012.07.029
9. Leonardi M, Albini Roccioli L, Battaglia S, et al. Oxygen-ozone chemonucleolysis for herniated disc with sciatica. A comparison of treatments in patients with subacute and chronic symptoms. *Rivista Italiana di Ossigeno-Ozonoterapia*. 2006;5:33-36.
10. Leonardi M, Simonetti L, Agati R. Neuroradiology of spine degenerative diseases. *Best Practice & Research Clinical Rheumatology*. 2002;16(1):59-87. doi:10.1053/berh.2001.0207
11. Leonardi M, Simonetti L, Raffi L, Cenni P, Barbara C. Mini-Invasive Treatment of Herniated Disc by Oxygen-Ozone Injection. *Interventional Neuroradiology*. 2003;9(2\_suppl):75-75. doi:10.1177/15910199030090s211
12. Magalhaes FNDO, Dotta L, Sasse A, Teixeira MJ, Fonoff ET. Ozone therapy as a treatment for low back pain secondary to herniated disc: a systematic review and meta-analysis of randomized controlled trials. *Pain Physician*. 2012;15(2):E115-129. <https://pubmed.ncbi.nlm.nih.gov/22430658/>
13. Muto M, Andreula C, Leonardi M. Treatment of herniated lumbar disc by intradiscal and intraforaminal oxygen-ozone (O2-O3) injection. *Journal of Neuroradiology*. 2004;31(3):183-189. doi:10.1016/s0150-9861(04)96989-1
14. Pellicanò F, Martinelli F, Tavanti V, et al. The Italian Oxygen-Ozone Therapy Federation (FIO) study on oxygen-ozone treatment of herniated disc. *International Journal of Ozone Therapy*. 2007;6:7-15.
15. Perri M, Grattacaso G, Di Tunno V, et al. MRI DWI/ADC signal predicts shrinkage of lumbar disc herniation after O2–O3 discolysis. *The Neuroradiology Journal*. 2015;28(2):198-204. doi:10.1177/1971400915576658
16. Rahimi-Movaghar V, Eslami V. The major efficient mechanisms of ozone therapy are obtained in intradiscal procedures. *Pain Physician*. 2012;15(6):E1007-1008.
17. Splendiani A, Perri M, Conchiglia A, et al. MR Assessment of Lumbar Disk Herniation Treated with Oxygen-Ozone Diskolysis: The Role of DWI and Related ADC versus Intervertebral Disk Volumetric Analysis for Detecting Treatment Response. *The Neuroradiology Journal*. 2013;26(3):347-356. doi:10.1177/197140091302600316
18. Steppan J, Meaders T, Muto M, Murphy KJ. A metaanalysis of the effectiveness and safety of ozone treatments for herniated lumbar discs. *Journal of vascular and interventional radiology: JVIR*. 2010;21(4):534-548. doi:10.1016/j.jvir.2009.12.393
19. Zhang Y, Ma Y, Jiang J, Ding T, Wang J. Treatment of the lumbar disc herniation with intradiscal and intraforaminal injection of oxygen-ozone. *Journal of Back and Musculoskeletal Rehabilitation*. 2013;26(3):317-322. doi:10.3233/bmr-130386
20. Czervionke LF, Fenton DS. Fat-Saturated MR Imaging in the Detection of Inflammatory Facet Arthropathy (Facet Synovitis) in the Lumbar Spine. *Pain Medicine*. 2008;9(4):400-406. doi:10.1111/j.1526-4637.2007.00313.x
21. D'Aprile P, Tarantino A, Lorusso V, Brindicci D. Fat Saturation Technique and Gadolinium in MRI of Lumbar Spinal Degenerative Disease. *The Neuroradiology Journal*. 2006;19(5):654-671. doi:10.1177/197140090601900518
22. D'Aprile P, Tarantino A, Jinkins JR, Brindicci D. The value of fat saturation sequences and contrast medium administration in MRI of degenerative disease of the posterior/perispinal elements of the lumbosacral spine. *European Radiology*. 2007;17(2):523-531. doi:10.1007/s00330-006-0324-0
23. Alonso F, Bryant E, Iwanaga J, Chapman JR, Oskouian RJ, Tubbs RS. Bastrup's Disease: A Comprehensive Review of the Extant Literature. *World Neurosurgery*. 2017;101:331-334. doi:10.1016/j.wneu.2017.02.004
24. Filippiadis DK, Mazioti A, Argentos S, et al. Bastrup's disease (kissing spines syndrome): a pictorial review. *Insights into Imaging*. 2015;6(1):123-128. doi:10.1007/s13244-014-0376-7
25. Kerroum A, Laudato PA, Suter MR. The steps until surgery in the management of Bastrup's Disease (kissing spine syndrome). *Journal of Surgical Case Reports*. 2019;2019(6). doi:10.1093/jscr/rjz194
26. Singla A. Bastrup's disease: The kissing spine. *World Journal of Clinical Cases*. 2014;2(2):45. doi:10.12998/wjcc.v2.i2.45
27. Philipp LR, Baum GR, Grossberg JA, Ahmad FU. Bastrup's Disease: An Often Missed Etiology for Back Pain. *Cureus*. 2016;8(1). doi:10.7759/cureus.465



*Comparative Study*

## **LINGUAL PASSIVE SELF-LIGATING STRAIGHT WIRE WITH SQUARE SLOT BRACKETS AND ACTIVE RETAINERS: COMPARISON BETWEEN LINGUAL ORTHODONTIC TECHNIQUES FOR THE RESOLUTION OF ANTERIOR DENTAL CROWDING**

A. Pinto<sup>1</sup>, V. Mazzetti<sup>1</sup> and A.M. Pujia<sup>2</sup>

<sup>1</sup>PhD Materials for Health, Environment and Energy, University of Tor Vergata, Rome, Italy

<sup>2</sup>Department of Biomedicine and Prevention, University of Tor Vergata, Rome, Italy

*\*Correspondence to:*

Alberto Maria Pujia, MD

Department of Biomedicine and Prevention, University of Rome Tor Vergata, Rome, Italy

e-mail: [albuja@gmail.com](mailto:albuja@gmail.com)

### **ABSTRACT**

Anterior crowding is one of the main reasons for orthodontic treatment in adults. The aim of this study is to evaluate the differences between two orthodontic alignment techniques of the anterior groups. The first technique involves the use of an active retainer that uses Copper Nickel-Titanium (Cu Ni-Ti) orthodontic wires with a round section which are free to slide in the composite modeled on the palatal surfaces of the dental elements. The second technique involves the use of lingual passive self-ligating system straight wire with square slot brackets. The passive self-ligating straight wire with square slot brackets technique is more reliable than the active retainers with round section Cu Ni-Ti arches for the alignment of anterior sectors.

**KEYWORDS:** *lingual orthodontics, active retainers, self-ligating, straight wire, anterior crowding*

### **INTRODUCTION**

Anterior crowding is one of the main reasons for orthodontic treatment in adults (1). With the increase of orthodontic treatments in adulthood, there has been an increase in the demand for aesthetic and comfortable techniques (2). An alternative to traditional vestibular appliances is lingual orthodontic treatment, especially for those patients who want to keep a smile free for the entire duration of treatment (3). Lingual orthodontic treatments were introduced over 30 years ago, (4,5) and in recent decades the demand for lingual orthodontic treatments has increased among patients seeking

Received: 04 May, 2020

Accepted: 27 July, 2020

ISSN: 2038-4106

Copyright © by BIOLIFE 2020

This publication and/or article is for individual use only and may not be further reproduced without written permission from the copyright holder. Unauthorized reproduction may result in financial and other penalties. **Disclosure: All authors report no conflicts of interest relevant to this article.**

aesthetic improvement (5-7). There are other aesthetic options such as labial ceramic brackets and clear aligners. Although the aligners are widely used by clinicians, they are not recommended as a first choice, in particularly complex cases. Lingual orthodontics techniques have also given positive results in these cases (7). At the same time, lingual biomechanics differs from that expressed in vestibular techniques (3, 8-10).

Lingual orthodontics did not have a large diffusion probably due to biomechanical reasons, a difficult development of brackets and performing methods, the particular lingual anatomy of the dental elements, and the necessity of an indirect bonding (11). In the last twenty years, several lingual orthodontic techniques have been developed (12, 13). A technique without brackets, which involved the use of active retainers with arches on the lingual surfaces of teeth from cuspids to cuspids, has been described to treat anterior dental crowding (14, 15).

The aim of our study is to evaluate the differences between two orthodontic alignment techniques. The first technique involves the use of active retainers. Cu Ni-Ti orthodontic round section arches are used. They are free to slide in the composite modeled on the palatal surfaces of the dental elements. The second technique involves the use of the lingual passive self-ligating straight wire system with square slot brackets.

## MATERIALS AND METHODS

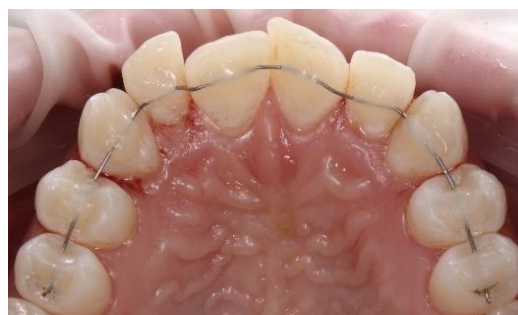### *Lingual orthodontic technique with active retainer*

This technique involves the use of Cu Ni-Ti round section arches for aligning frontal teeth. The arches are applied to the lingual surfaces of the teeth. To attach arches to teeth, attachments are created with the composite. These composite bases hold the wire in the desired position and then the composite is modeled to stabilize the arch (Fig. 1). Dentists must check that the arch could flow through the composite after bonding every tooth. The arch is stabilized starting from the marginal ridge of the premolars. Cuspids and incisors are attached to the arch. The occlusion points are checked after every arch change to obtain a bilateral occlusion.

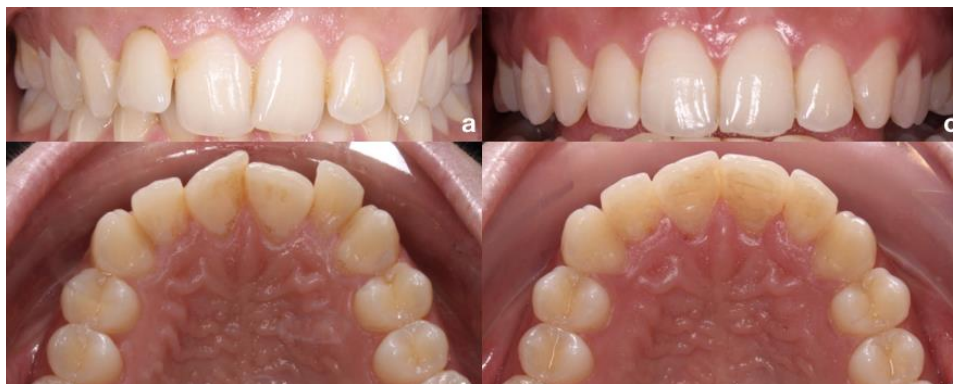The treatment is carried out with three arches 0.013-in, 0.014-in, and 0.016-in (DAMON OPTIMAL-FORCE Cu Ni-Ti, ORMCO, Orange, CA, USA). Acceptable results can be achieved after at least six months of therapy (Fig. 2).

### *Lingual orthodontic technique with passive self-ligating straight wire with square slot brackets*

The technique involves the use of passive self-ligating low friction straight wire and attacks with a square slot 0.018-inX0.018-in (Alias lingual straight wire bracket system, ORMCO, Orange, CA, USA) (Fig. 3-4). Only “frontal teeth” cases were treated. The technique needs a digital setup study phase. The patient models are loaded into the Eline System website (<https://www.elinesystem.net>). The laboratory prepares a preview of the finished case which must be



**Fig. 1.** Occlusal view of active retainer after bonding (0.013 Cu Ni-Ti).



**Fig. 2.** (a): Frontal view at the beginning of treatment; (b): Occlusal view at the beginning of treatment; (c): Frontal view after six months; (d): Occlusal view after six months.

approved by the clinician (Fig. 5).

Brackets' position is carried out on a digital model and subsequently positioning jigs are printed for bonding. Positioning jigs allow a proper attachment of the standard bracket to the lingual surface of each dental element. There are arches of three different sizes (Small, Medium, and Large) to adapt to the patient's dental arch. Finally, a transfer template with customized brackets inside is created in the laboratory. These brackets are subsequently bonded on the lingual surfaces of the patient. Furthermore, positioning jigs are stored for a possible rebonding (if the bracket is loose for a chewing trauma).

Arches in Cu Ni-Ti (Alias Small, Medium, Large Cu Ni-Ti, ORMCO, Orange, CA, USA) of various sizes were used. The use of low friction and square arches have made treatments for the frontal alignment quick (about 6 months) and precise because it allows better regulation of tip and torque. (Fig. 6).

*Rebonding lingual brackets*

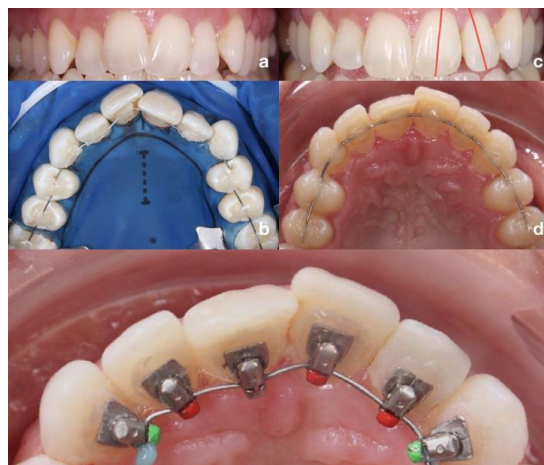The original rebonding technique after a chewing trauma involves an indirect procedure through the repositioning jig and the plaster model. A direct technique in the patient's oral cavity was used in this study: it is possible to eliminate the jig points which are in contact with adjacent teeth (Fig. 7). After cleaning the tooth and brackets it is possible to proceed with bonding. The bracket must have the flap closed when is inserted in the appropriate jig space. Care must be taken to ensure that the composite does not come in contact with the plastic of the jig when placing the jig on the tooth. In this way it will be easier to remove it after photopolymerization (Fig. 8).

*Post-treatment*

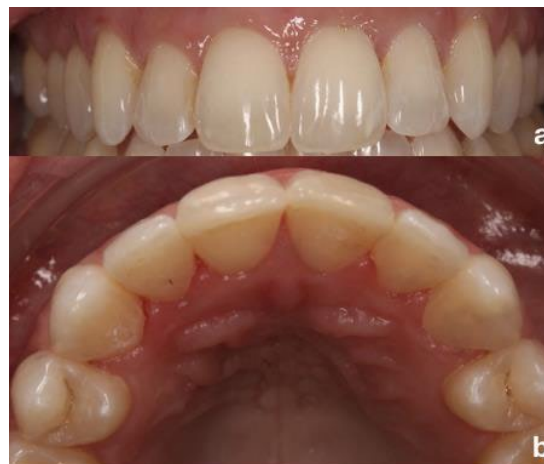In "frontal teeth" treatments, the post-treatment phase with stainless steel passive retainer or clear thermoplastic retainer is very important. The tension between the dental elements can lead to a relapse. For this reason, it is important to evaluate the amount of stripping needed and examine any incisive pre-contacts that may occur at the end of the therapy and perform a light selective grinding if necessary (Fig. 9).

**DISCUSSION**

Crowding is a loss of integrity in the dental arch due to tension



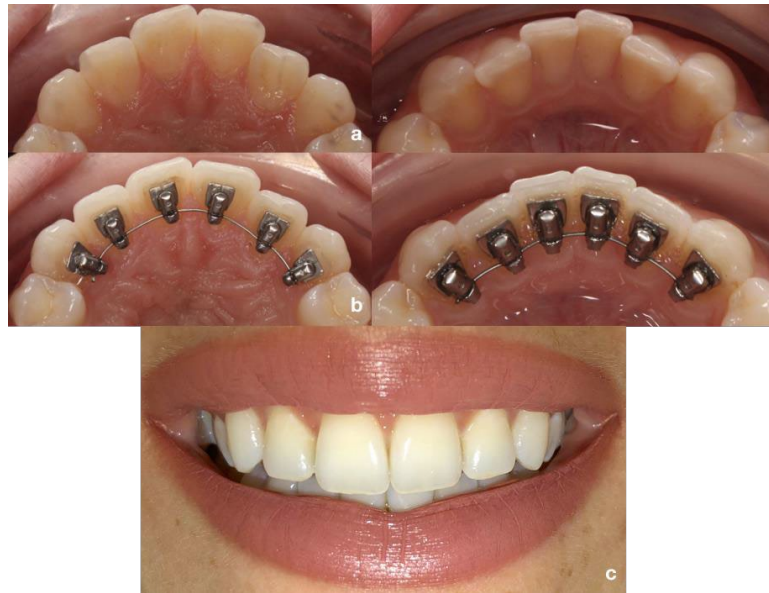**Fig. 3.** (a): Frontal view at the beginning of treatment; (b): Occlusal view at the beginning of treatment; (c): Red lines indicate the wrong angle of the incisors after a few months of treatment; (d): In this case, it was not possible to resolve the dental crowding with active retainer technique; (e): Occlusal view of the case after bonding the brackets ALIAS ORMCO.




**Fig. 4.** Frontal (a) and occlusal (b) view of the end of therapy 6 months after bonding the brackets.



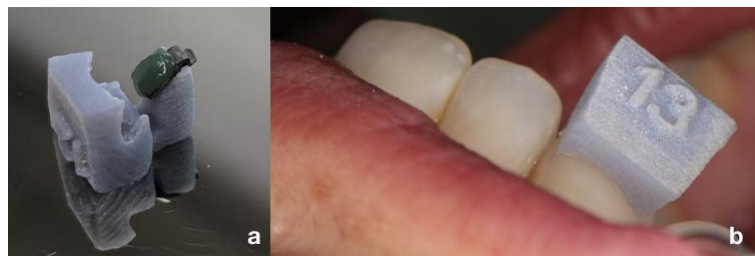**Fig. 5.** Digital case study: superimposition of the setup on the malocclusion and 3D preview of finished case on Eline System software.



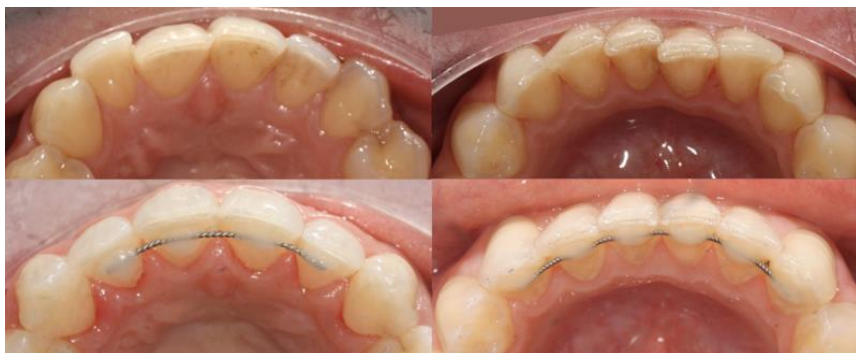**Fig. 6.** (a): Occlusal views at the beginning of treatment; (b): Occlusal views after 2 months; (c): Smile at the end of therapy after 6 months.



**Fig. 7.** (a-b): Positioning jig with wings; (c): How to remove the wings; (d): Jig with wings removed.



**Fig. 8.** (a): Jig modified with the bracket inserted with the flap closed before re-bonding; (b): Intraoral view of re-bonding after trauma.



**Fig. 9.** Passive retainers after “frontal teeth” treatments.

**Table I.** Comparison between two orthodontic treatments.

TECHNIQUE WITH ACTIVE RETAINER	
ADVANTAGES	DISADVANTAGES
Well tolerated by patient	Difficult tip and torque management
Low costs	Use only round section arches
Less initial phonetic problems	Very operator dependent
	Lack of predictability
	Long appointments for changing arches

SELF-LIGATING PASSIVE TECHNIQUE WITH SQUARE SLOT	
ADVANTAGES	DISADVANTAGES
Extreme predictability	Not well tolerated by patient
Good tip and torque management	High costs
Short time to change arches	Difficulty to rebond brackets
Possibility of closing diastemas in simple way	In deep-bites high occlusal build-up
Digital calibration of stripping	

and not simply a consequence of lack of space. Dental arch instability determinant factors should be identified before starting therapy (1). One of the most critical aspects of “frontal teeth” treatments is the possibility of post-treatment relapse (16). These treatments do not fully correct malocclusions, consequently, dental elements could return to their initial position. For this reason, after these treatments very careful and constant retention has to be applied (14,17-21). Furthermore, “frontal teeth” treatments are aesthetic procedures which are evolved in recent years. Both techniques are recent evolutions of others used in the past (12,14). In this study, these methods have only been applied to adults.

An alternative to these treatments is the use of transparent aligners, but only totally invisible methods were analyzed in this paper (22).

In literature there are not articles that compared these two techniques exposing the advantages and disadvantages (Table I). Active retainer technique is operator dependent and has difficult predictability of result. Lingual technique with passive self-ligating straight wire with square slot brackets was a great innovation. Moreover, the classic mushroom shape for lingual arches was eliminated (23). Straight wire was used similarly to the vestibular techniques. The concept of vestibular low friction has moved to lingual technique, and it can also be applied to complete therapies for solving malocclusion. Frequent limitations of lingual therapy with brackets are tongue discomfort, speaking difficulties and problems in maintaining adequate oral hygiene, although no differences for eating and caries risk were detected (5, 24). Certainly, these aspects are less evident in the technique with active retainers. The “frontal teeth” treatment needs a careful study of the case. An aesthetic and functional study with photos and plaster models was always carried out (25). Radiographs are needed only in cases of diagnostic doubts about bone quality or root parallelism. In one case of active retainer, it was necessary to end the therapy with the application of passive self-ligating lingual orthodontic brackets, because it was not possible to manage tip and torque with the first method.

## CONCLUSION

In conclusion, the active retainer technique can be used for an approximate alignment, while the passive self-ligating lingual straight wire technique with square slot brackets is reliable in the anterior alignment treatments. To increase the effectiveness and the precision of the treatment with passive self-ligating lingual brackets a modification could be made: premolars can be bonded, and the action of the arches can also be extended to them to avoid any unwanted movement of the cuspids. Therefore, additional cases are needed to get more information in regards the advantage and disadvantages of both orthodontic techniques.

## Funding

This research received no external funding.

*Conflict of Interest*

The authors declare no conflict of interest.

**REFERENCES**

1. Consolaro A, Cardoso M de A. Mandibular anterior crowding: normal or pathological? *Dental Press Journal of Orthodontics*. 2018;23(2):30-36. doi:10.1590/2177-6709.23.2.030-036.oin
2. Weir T. Clear aligners in orthodontic treatment. *Australian Dental Journal*. 2017;62(S1):58-62. doi:10.1111/adj.12480
3. Lombardo L, Arreghini A, Al Ardha K, Scuzzo G, Takemoto K, Siciliani G. Wire load-deflection characteristics relative to different types of brackets. *International Orthodontics*. 2011;9(1):120-139. doi:10.1016/j.ortho.2010.12.011
4. Fujita K. New orthodontic treatment with lingual bracket mushroom arch wire appliance. *American Journal of Orthodontics*. 1979;76(6):657-675. doi:10.1016/0002-9416(79)90211-2
5. Ata-Ali F, Ata-Ali J, Ferrer-Molina M, Cobo T, De Carlos F, Cobo J. Adverse effects of lingual and buccal orthodontic techniques: A systematic review and meta-analysis. *American Journal of Orthodontics and Dentofacial Orthopedics*. 2016;149(6):820-829. doi:10.1016/j.ajodo.2015.11.031
6. Fritz U, Diedrich P, Wiechmann D. Lingual Technique – Patients’ Characteristics, Motivation and Accpetance Interpretation of a Retrospective Survey. *Journal of Orofacial Orthopedics / Fortschritte der Kieferorthopädie*. 2002;63(3):227-233. doi:10.1007/s00056-002-0124-3
7. Liu D, Yan B, Lei F, et al. Different sliding mechanics in space closure of lingual orthodontics: a translational study by three-dimensional finite element method. *American Journal of Translational Research*. 2019;11(1):120-130.
8. Moran KI. Relative wire stiffness due to lingual versus labial interbracket distance. *American Journal of Orthodontics and Dentofacial Orthopedics: Official Publication of the American Association of Orthodontists, Its Constituent Societies, and the American Board of Orthodontics*. 1987;92(1):24-32. doi:10.1016/0889-5406(87)90292-7
9. Lombardo L, Scuzzo G, Arreghini A, Gorgun Ö, Ortan YÖ, Siciliani G. 3D FEM comparison of lingual and labial orthodontics in en masse retraction. *Progress in Orthodontics*. 2014;15(1). doi:10.1186/s40510-014-0038-9
10. Pol T, Vandekar M, Patil A, Desai S, Shetty V, Hazarika S. Torque Control During Intrusion on Upper Central Incisor in Labial and Lingual bracket System - A 3D Finite Element Study. *Journal of Clinical and Experimental Dentistry*. 2017;10(1). doi:10.4317/jced.54461
11. Riolo C, Finkleman SA, Kaltschmidt C. Lingual orthodontics: Understanding the issues is the key to success with lingual mechanics. *Seminars in Orthodontics*. 2018;24(3):271-285. doi:10.1053/j.sodo.2018.08.001
12. Scuzzo G, Takemoto K, Takemoto Y, Scuzzo G, Lombardo L. A new self-ligating lingual bracket with square slots. *Journal of clinical orthodontics: JCO*. 2011;45(12):682-690; quiz 692.
13. Kim DY, Ha SW, Cho IS, Yang IH, Baek SH. *In-vitro* investigation of the mechanical friction properties of a computer- aided design and computer-aided manufacturing lingual bracket system under diverse tooth displacement condition. *The Korean Journal of Orthodontics*. 2019;49(2):73. doi:10.4041/kjod.2019.49.2.73
14. Liou EJW, Chen LIJ, Huang CShing. Nickel-titanium mandibular bonded lingual 3-3 retainer: For permanent retention and solving relapse of mandibular anterior crowding. *American Journal of Orthodontics and Dentofacial Orthopedics*. 2001;119(4):443-449. doi:10.1067/mod.2001.111397
15. Lombardo L, Saba L, Scuzzo G, et al. A new concept of anatomic lingual arch form. *American Journal of Orthodontics and Dentofacial Orthopedics*. 2010;138(3):260.e1-260.e13. doi:10.1016/j.ajodo.2010.04.022
16. Littlewood S, Kandasamy S, Huang G. Retention and relapse in clinical practice. *Australian Dental Journal*. 2017;62(S1):51-57. doi:10.1111/adj.12475
17. Knierim RW. Invisible lower cuspid to cuspid retainer. *The Angle Orthodontist*. 1973;43(2):218-220. doi:10.1043/0003-3219(1973)043<0218:ILCTCR>2.0.CO;2
18. Carter RN. Simplified direct-bonded retainer. *Journal of clinical orthodontics: JCO*. 1978;12(3):221.
19. Lee RT. The Lower Incisor Bonded Retainer in Clinical Practice: A Three Year Study. *British Journal of Orthodontics*.

- 1981;8(1):15-18. doi:10.1179/bjo.8.1.15
20. Årtun J, Zachrisson B. Improving the handling properties of a composite resin for direct bonding. *American Journal of Orthodontics*. 1982;81(4):269-276. doi:10.1016/0002-9416(82)90212-3
  21. Dahl EH, Zachrisson BU. Long-term experience with direct-bonded lingual retainers. *Journal of clinical orthodontics: JCO*. 1991;25(10):619-630.
  22. Galan-Lopez L, Barcia-Gonzalez J, Plasencia E. A systematic review of the accuracy and efficiency of dental movements with Invisalign®. *The Korean Journal of Orthodontics*. 2019;49(3):140. doi:10.4041/kjod.2019.49.3.140
  23. Lombardo L, Carlucci A, Palone M, Mollica F, Siciliani G. Stiffness comparison of mushroom and straight SS and TMA lingual archwires. *Progress in Orthodontics*. 2016;17(1). doi:10.1186/s40510-016-0140-2
  24. Papageorgiou SN, Gölz L, Jäger A, Eliades T, Bourauel C. Lingual vs. labial fixed orthodontic appliances: systematic review and meta-analysis of treatment effects. *European Journal of Oral Sciences*. 2016;124(2):105-118. doi:10.1111/eos.12250
  25. Ata-Ali F, Cobo T, De Carlos F, Cobo J, Ata-Ali J. Are there differences in treatment effects between labial and lingual fixed orthodontic appliances? A systematic review and meta-analysis. *BMC Oral Health*. 2017;17(1). doi:10.1186/s12903-017-0424-z





*Prospective Study*

## **THE PRECISION OF INDIRECT BONDING PERFORMED BY OPERATORS WITH DIFFERENT EXPERIENCE: A PROSPECTIVE STUDY**

M. Morini<sup>1</sup>, B. Hadroviq<sup>1</sup> and P. Carls<sup>2</sup>

<sup>1</sup>Postgraduate School of Orthodontics, University of Ferrara, Ferrara, Italy

<sup>2</sup>Consultant Oral-Maxillofacial Surgeon, 69 Banbury Road, Oxford, UK

*Correspondence to:*

Martina Morini, DDS

Postgraduate School of Orthodontics, University of Ferrara,

Via Luigi Borsari 46, Ferrara 44121, Italy

e-mail: [martina.morini@teletu.it](mailto:martina.morini@teletu.it)

### **ABSTRACT**

The purpose of this study is to evaluate the reproducibility of bracket placement using indirect bonding by orthodontists with differing experiences in indirect bonding in the same clinical case. Three groups of ten operators were selected as the study sample. Group 1: dentists with limited or no clinical experience; Group 2: postgraduate orthodontics students; and Group 3: orthodontics specialists. A Master operator was chosen as a reference point for ideal bonding. Indirect bonding of 28 dental elements was performed on the same dental casts. The relative positions of each bracket were compared by assessing three variables: vertical measurements (A), axial measurements (B), and horizontal measurements (C) using digital photography. Statistic Analysis: Fisher's analysis of variance (ANOVA) was applied to test for differences between the mean values. The p-value established is 0.05. The Bonferroni post hoc test is utilised to find these statistically significant differences. Student T test was chosen to measure the difference between groups and Masters. Vertical positioning has an average error of 0.2 mm, axial positioning has an average error of 1°, and horizontal positioning has an average error of 0.2 mm. On elements 1.2, 2.4, and 4.2, all 30 operators have made errors regarding all three studied parameters (A, B, and C), whereas fewer errors have occurred on elements 4.1 and 4.7. The experience of the operators in indirect bonding influences the accuracy of bracket placement: orthodontists with more experience perform indirect bonding with greater accuracy than dentists with little or no experience. Finding the correct axial tilt of the brackets is the most difficult aspect for clinicians in bonding, particularly those with more experience.

**KEYWORDS:** *orthodontic brackets, bracket bonding technique/method, indirect bonding, bonding accuracy, operator experience, result reproducibility, axial error, horizontal error, vertical error*

Received: 4 aprile 2020

Accepted: 27 May 2020

ISSN: 2038-4106

Copyright © by BIOLIFE 2020

This publication and/or article is for individual use only and may not be further reproduced without written permission from the copyright holder. Unauthorized reproduction may result in financial and other penalties. **Disclosure: All authors report no conflicts of interest relevant to this article.**

## INTRODUCTION

In order to achieve an ideal final occlusion, the orthodontic equipment industry constantly introduces new bracket prescriptions into the market, and research is carried out on the properties materials' choices of the archwire utilised on the alignment and levelling phases (1).

Although many aspects play a role in the final result, such as the archwire-slot play and the degree of edge beveling of the orthodontic archwire (2), these efforts are futile without an accurate positioning technique. In the edgewise technique, it was necessary to have exceptional skill in bending orthodontic wires to complete a case successfully; today, it is necessary to be as precise as possible when positioning brackets on dental elements. The aim of the pre-adjusted equipment, regardless of prescription differences, is to enable the orthodontist to obtain an ideal occlusion without bending the arch. According to Andrews (3, 4), vestibular orthodontic brackets should be positioned parallel to the incisal edges of the anterior teeth and parallel to the contact points of the posterior teeth, as well as in the middle third of the crown (FA point). On the other hand, in the lingual straight wire method, the brackets should be placed as close as possible to the gingival margin (5).

There are three types of bonding: direct bonding, indirect bonding performed on dental casts, and digital indirect bonding. Indirect bonding (6) uses a transfer system; brackets or other attachments are transferred from the initial dental cast (also known as working casts) and bonded to the patient's dentition. Having the possibility of bonding the appliance on the casts provides undeniable benefits, including optimal visibility of all dental elements from all angles and unlimited working time on dental casts rather than in vivo, a significant reduction in chair time, greater precision in the positioning of the brackets, less need for rebracketing, and a shorter treatment time (7, 8).

Indirect bonding, on the other hand, requires expensive laboratory procedures compared to direct bonding. In addition, numerous studies (8, 10, 11) have demonstrated a high failure rate of brackets positioned with indirect technique during treatment. This failure rate is statistically significant in the posterior segment of the lower arch, where the proportion of adhesive failures is higher with indirect bonding. Finally, numerous studies comparing the accuracy of direct and indirect bonding have shown no statistically significant difference between the two techniques.

Despite the clinical significance of accurate bracket placement, only a few studies have investigated the nature of indirect bonding errors (12, 13), and none have assessed the effect of operator experience on bracket bonding precision. Therefore, this study aims to compare the reproducibility of bracket placement by indirect bonding performed by orthodontists with varying degrees of experience in indirect bonding in the same clinical case.

## MATERIALS AND METHODS

Given the purpose of the study, the patient test for indirect bonding was selected based on the following inclusion criteria: normo-hypodivergent pattern, complete permanent dentition (except the third molar), no previous orthodontic treatment, no prosthetic or conservative treatment (class II fillings or inlays and class III and IV restorations), mild crowding, and no dental elements with poor suture (poor eruption, excessive abrasion, anomalies of shape).

Indirect bonding is performed with Primo Brackets (Sweden & Martina) from the second molar to the second molar in both arcades, always on the same casts. The brackets are positioned using the McLaughlin-Bennet-Trevisi positioning card, the marginal ridge levels (11), and orthopantomography.

The study sample consists of three groups with different indirect bonding experiences: Group 1: dental graduates with little or no clinical experience; Group 2: orthodontic postgraduates; Group 3: orthodontic specialists. To define the "ideal" position, a "master" operator (the clinician with the most experience) was selected.

Dental casts were photographed perpendicular to the buccal surface of each tooth from different front and side angles. First, individual frontal images of non-bonded dental elements were imported into the Inkscape software, where for all 28 dental elements, a pattern was designed: the outline (in yellow), the FACC (Facial Axis of the Clinical Crown), and a line tangent to the incisal/occlusal margin of the tooth in red (Fig. 1). Measurements were assessed using the same software, by superposing the pattern to the photographs of each bonded dental element. For occlusal vision measurements, the same procedure was followed.

For the frontal photographs, the following were measured:

- the distance A between the incisal/occlusal edge of the tooth and the coronal base of the bracket;
- the angle B between the FACC (Facial Axis of the Clinical Crown) and the vertical axis of the bracket.

For occlusal view photographs, a single measurement was taken: the distance C, in millimetres, between the straight line passing through the tooth's centre and the parallel straight line passing through the centre of the base of the bracket (Fig. 1).

#### *Statistic analysis*

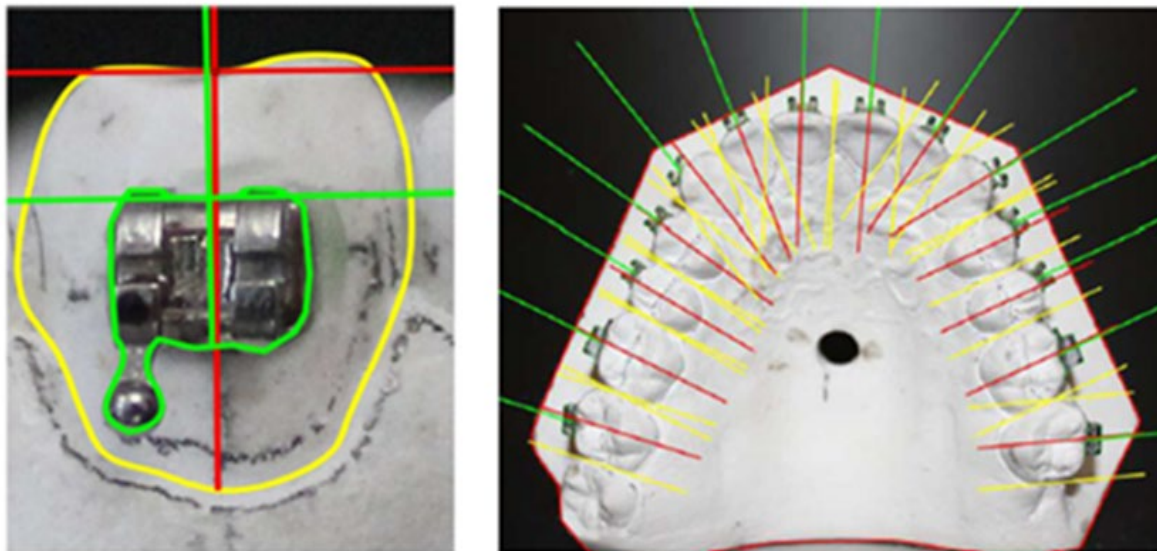
One thousand two hundred sixty measurements were analysed comprising three variables: vertical (A), axial (B), and horizontal (C) measurements of 28 dental elements. The mean and standard deviation of the three parameters (A, B, C) on each dental element were determined for each operator group (Group 1, 2, 3). Fisher's analysis of variance (ANOVA) was then conducted to test the difference between the means. The predetermined p-value for this test was 0.05. The Bonferroni post hoc test was then utilised to determine the location of these significant differences. Finally, the Student T-test was used to determine the statistically significant differences between the means of each group and the "master" value for each bracket.

#### *Error assessment*

The same measurements were taken on each bonded model (study sample) by a first orthodontist operator ("Examiner 1") and then by a second orthodontist operator ("Examiner 2"). Performing a second measurement for each parameter enabled the reproducibility error to be determined. The random error was analysed using the Dahlberg method, while the systematic error was analysed using a T-test for dependent samples. The maximum value of the Dahlberg index was 0.019. The t-test p-value exceeds 0.05, indicating that the measurement method is reproducible. The errors calculated were insignificant. Examiner 1's measurements serve as the basis for the statistical analysis.

## RESULTS

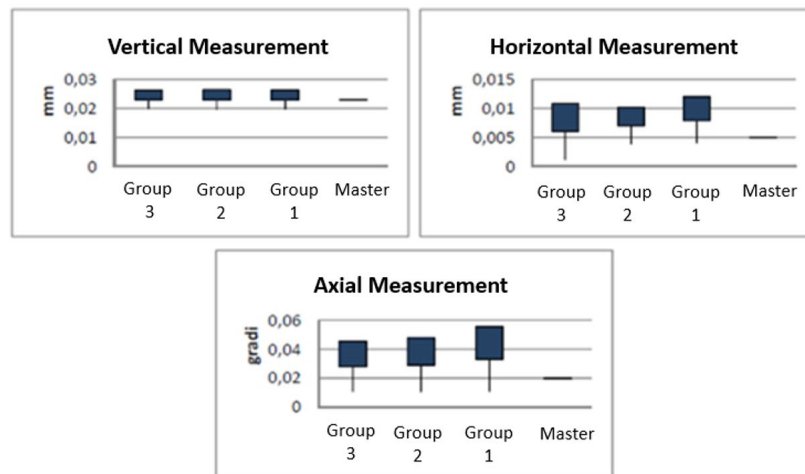
The brackets placed by Group 3 come closest to the Master based on the average of each of the three parameters considered for all teeth. The mean of Group 2 is equivalent to Group 3, and thus the Master. The average for Group 1 differs the most from that of the Master. However, this difference is smaller for vertical measurements than for axial and horizontal measurements.



**Fig. 1.** In frontal view: the outline (in yellow), the FACC and a line, perpendicular to the previous one, tangent to the incisal/occlusal margin (both in red); in occlusal view: the brackets and a straight line passing through the center of the bracket (green color) parallel to the center line of the tooth (red color).

Compared to ideal vertical positioning, the average error in vertical positioning is 0.2 mm. Compared to ideal positioning, the average error in axial positioning is 1°. Compared to ideal horizontal positioning, the average horizontal positioning error is 0.2 mm (Fig. 2).

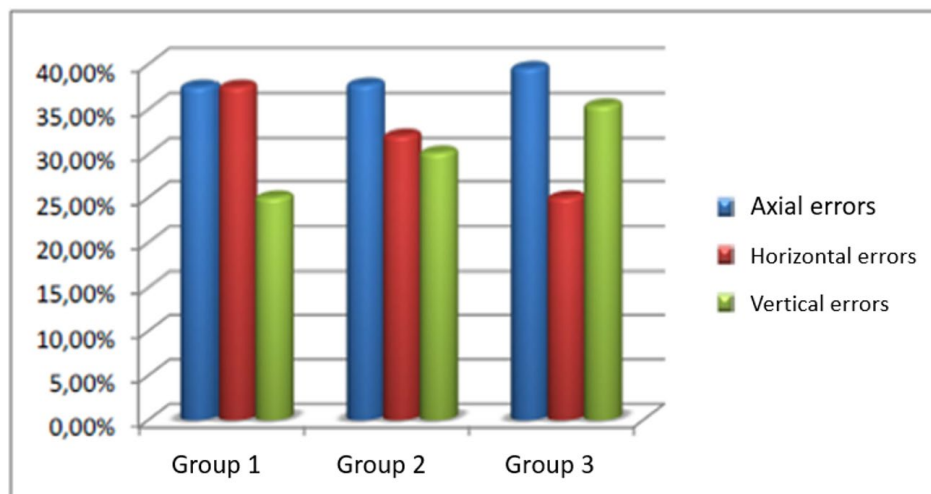
Elements 1.2, 2.4, and 4.2 are the teeth on which errors have been made regarding all three parameters considered (A, B, C) by all 30 operators (Table I). It has been demonstrated that axial errors are the most prevalent among all operators, followed by horizontal and vertical errors (Fig. 3)



**Fig. 2.** Mean and standard deviation of 3 groups compared to the Master value.

**Table I.** Types of errors made (A-vertical error, B-axial error, C-horizontal error) for each tooth by all operators of the three groups.

TOOTH	GROUP 1	GROUP 2	GROUP 3
1.1	BC	BC	BC
1.2	ABC	ABC	ABC
1.3	B	B	B
1.4	B	B	B
1.5	B	B	B
1.6	B	B	B
1.7	B	B	B
2.1	A	A	A
2.2	A	A	A
2.3	A	A	A
2.4	ABC	ABC	ABC
2.5	A	A	A
2.6			
2.7	B	B	B
3.1	BC	BC	BC
3.2	A	A	A
3.3			
3.4	BC	BC	BC
3.5			
3.6	B	B	B
3.7			
4.1	C	C	
4.2	ABC	ABC	ABC
4.3	BC	BC	BC
4.4	BC	BC	BC
4.5	C	C	C
4.6	B	B	B
4.7	BC		



**Fig. 3.** Types of errors most frequently committed by all three groups of operators

## DISCUSSION

The literature regarding the precision of bracket placement does not meet the criteria for credible research on the topics: establish an adequate definition of where brackets should be placed to define the “ideal” position, and include bonding even for teeth that are difficult to bond accurately, such as posterior teeth, irregularly shaped teeth, and teeth that are severely crowded.

In the scientific literature, there are numerous comparisons between indirect bonding and direct method and indirect transfer methods. However, this comparison does not consider the “ideal” position of the brackets, which should be in the centre of the clinical crown (3, 4, 14). Similar to what Koo et al. (12) did, our study presents a choice regarding the definition of the “ideal” position, namely that the ideal position was determined by the bonding performed by the operator (termed “master”), considered to have the most indirect bonding experience. Furthermore, our study comprised all permanent series dental elements typically involved in orthodontic bonding: from the second molar to the second molar of both arches. This choice was unprecedented in the literature, as no articles had previously considered the entire set of teeth.

No other studies in the literature consider the role of the orthodontist in indirect bonding; therefore, no one has previously evaluated whether and to what extent the experience of the operators performing indirect bonding can influence the precision of bracket placement. Our findings indicate statistically significant differences between indirect bonding performed by dental graduates with little to no experience and that of orthodontic specialists. As expected, the operator’s experience influences the positioning accuracy of the brackets during indirect bonding.

However, it should be emphasised that the differences between clinicians with different indirect bonding experiences are more pronounced for the positioning of the bracket in axial and horizontal directions than for the vertical direction. This is likely due to the use of altimeters, a method of vertical bracket positioning that Armstrong et al. (15) found to be more accurate and reproducible than visually identifying the FA point.

In our study, digital photography is used to compare the position of every single bracket. Klocke et al. (10) evaluated the precision of direct and indirect positioning using a similar method.

In the present study, we were asked if, similar to previous research, there were correlations between the type of errors made and the tooth considered (13, 16, 17):

- all types of errors are equally prevalent on the upper and lower incisors;
- horizontal errors are never committed on the upper canines, whereas all types of errors are committed on the lower canines;
- all errors are committed with equal frequency on both the upper and lower premolars.

Axial positioning errors predominate over other types on both upper and lower molars.

Contrary to what the literature anticipated (13,16), there is no correlation between the type of errors made by the operator and the type of tooth considered in indirect bonding; this suggests that indirect bonding eliminates the difficulties associated with direct bonding. However, our results indicate that indirect bonding is more challenging for all operators, regardless of experience, when bonding “critical” teeth.

The teeth with the most errors are 1.2, 2.4, and 4.2. However, these results are not clinically relevant because these teeth are neither excessively crowded nor have an irregular shape compared to the opposing teeth.

In our study, the mean vertical, horizontal, and axial errors were comparable to those found in previous research (7-9). In addition, it has been demonstrated that axial errors are the most prevalent among all operators, followed by horizontal and vertical errors.

Our study’s limitations can be summed up as follows:

- compare the accuracy of the positioning of the brackets performed by different orthodontists; it was necessary to select a single malocclusion subjected to indirect bonding; thus, the study lacks heterogeneity to establish validity, i.e., the study should include a wide variety of malocclusions (extractive and non-extractive, of adults and adolescents);
- compare the accuracy of the positioning of the brackets performed by different orthodontists; the 30 operators (sample of the study) performed indirect bonding while aware that they were participating in an observational study, whereas clinicians should not be aware that they are being observed to avoid the Hawthorne effect;
- no positive or negative signs were associated with the mesial or distal position of the bracket in the occlusal view relative to the ideal, nor the mesial or distal inclination in the front view, but only for vertical positioning.

## CONCLUSIONS

It can be concluded that (1) the experience of the operators in indirect bonding affects the precision of bracket placement: orthodontists with more experience perform more precise indirect bonding than clinicians with little or no experience; (2) finding the correct axial inclination of the brackets poses the greatest difficulty for clinicians, even those with more experience; and (3) the positioning accuracy is independent of the type of tooth, whether anterior or posterior, upper or lower.

## REFERENCES

1. Lombardo L, Ceci M, Mollica F, Mazzanti V, Palone M, Siciliani G. Mechanical properties of multi-force vs. conventional NiTi archwires. *Journal of Orofacial Orthopedics*. 2019;80(2):57-67. doi:10.1007/s00056-018-00164-4
2. Lombardo L, Arreghini A, Bratti E, et al. Comparative analysis of real and ideal wire-slot play in square and rectangular archwires. *The Angle Orthodontist*. 2015;85(5):848-858. doi:10.2319/072214-510.1
3. Andrews LF. The straight-wire appliance, origin, controversy, commentary. *Journal of Clinical Orthodontics*. 1976;10(2):99-114.
4. Andrews LF. *Straight Wire – the Concept and the Appliance*. Wells Co, LA; 1989.
5. Lombardo L, Carlucci A, Palone M, Mollica F, Siciliani G. Stiffness comparison of mushroom and straight SS and TMA lingual archwires. *Progress in Orthodontics*. 2016;17(1). doi:10.1186/s40510-016-0140-2
6. Kalange JT, Thomas RG. Indirect Bonding: A Comprehensive Review of the Literature. *Seminars in Orthodontics*. 2007;13(1):3-10. doi:10.1053/j.sodo.2006.11.003
7. Hodge TM, Dhopatkar AA, Rock WP, Spary DJ. The Burton Approach to Indirect Bonding. *Journal of Orthodontics*. 2001;28(4):267-270. doi:10.1093/ortho/28.4.267
8. Cozzani M, Menini A, Bertelli A. Etching masks for precise indirect bonding. *Journal of Clinical Orthodontics*. 2010;44(5):326-330.
9. Deahl ST, Salome N, Hatch JP, Rugh JD. Practice-based comparison of direct and indirect bonding. *American Journal of Orthodontics and Dentofacial Orthopedics*. 2007;132(6):738-742. doi:10.1016/j.ajodo.2006.01.037
10. Klocke A, Tadic D, Vaziri F, Kahl-Nieke B. Custom base preaging in indirect bonding. *The Angle Orthodontist*. 2004;74(1):106-111.
11. Menini A, Cozzani M, Sfondrini MF, Scribante A, Cozzani P, Gandini P. A 15-month evaluation of bond failures of orthodontic brackets bonded with direct versus indirect bonding technique: a clinical trial. *Progress in Orthodontics*. 2014;15(1):70. doi:10.1186/s40510-014-0070-9

12. Koo BC, Chung CH, Vanarsdall RL. Comparison of the accuracy of bracket placement between direct and indirect bonding techniques. *American Journal of Orthodontics and Dentofacial Orthopedics*. 1999;116(3):346-351. doi:10.1016/s0889-5406(99)70248-9
13. Mota Júnior SL, de Andrade Vitral J, Schmitberger CA, et al. Evaluation of the vertical accuracy of bracket placement with the Boone gauge. *American Journal of Orthodontics and Dentofacial Orthopedics*. 2015;148(5):821-826. doi:10.1016/j.ajodo.2015.05.028
14. Kalange JT. Prescription-Based Precision Full Arch Indirect Bonding. *Seminars in Orthodontics*. 2007;13(1):19-42. doi:10.1053/j.sodo.2006.11.005
15. Armstrong D, Shen G, Petocz P, Darendeliler MA. A comparison of accuracy in bracket positioning between two techniques--localising the centre of the clinical crown and measuring the distance from the incisal edge. *The European Journal of Orthodontics*. 2007;29(5):430-436. doi:10.1093/ejo/cjm037
16. Oliveira NS de, Gribel BF, Neves LS, Lages EMB, Macari S, Pretti H. Comparison of the accuracy of virtual and direct bonding of orthodontic accessories. *Dental Press Journal of Orthodontics*. 2019;24(4):46-53. doi:10.1590/2177-6709.24.4.046-053.oar





---

*Clinical Trial*

## **ULTRASOUND EVALUATION OF BONE GROWTH IN ORTHODONTICS: A CONTROLLED CLINICAL TRIAL**

P. Caccianiga\*, G. Caccianiga and A. Leonida

School of Medicine and Surgery, University of Milano-Bicocca, Monza, Italy

*Correspondence to:*

Paolo Caccianiga, MD

School of Medicine and Surgery,

University of Milano-Bicocca, Monza, Italy

e-mail: p.caccianiga@campus.unimib.it

### **ABSTRACT**

The aim of this research was to assess the ability of soft tissue ultrasound to evaluate the development of wrist ossification centres, particularly for the monitoring of adolescents submitted to orthodontic treatments. High-resolution ultrasound of the hand and wrist was performed with an X-ray examination on 54 patients undergoing orthodontic therapy. Ultrasound scans were specifically directed to the search of ossification centres critical for the peak growth age, namely the pisiform, the adductor sesamoid of the metacarpal-phalangeal joint of the thumb and the cartilage of the distal phalanx of the third finger. Ultrasonography allowed the appreciation of all these structures and yielded results statistically equivalent to film examinations for the pisiform and the sesamoid of the thumb. A statistically significant difference between the two techniques was found concerning the cartilage of the third finger, as it was challenging to profile in some ultrasound scans. Ultrasound of the wrist can be proposed as a simple and valuable non-radiating substitute for the follow-up of skeletal maturation in adolescents during orthodontic treatments.

**KEYWORDS:** *echography, bone, growth, orthodontics, ultrasound*

### **INTRODUCTION**

The bone age is evaluated in various medical situations: to evaluate endocrinal disorders, monitor the response to treatment, determine the potential growth of children and adults and plan orthopaedic procedures (1).

Orthodontics researches and treats malocclusion, which is responsible for bone alterations of the teeth or mixed. According to this, it is easy to underline that orthodontic therapy can have an orthopaedic purpose when it involves maxillary bones or an orthodontic aim if only the teeth are involved (2-5). The strictly orthodontic treatment, meant as teeth realignment, can be done at all ages with the only limitation for patients affected with metabolic disorders of

---

Received: 28 May 2020

Accepted: 20 July 2020

ISSN: 2038-4106

Copyright © by BIOLIFE 2020

This publication and/or article is for individual use only and may not be further reproduced without written permission from the copyright holder. Unauthorized reproduction may result in financial and other penalties. **Disclosure: All authors report no conflicts of interest relevant to this article.**

bones that can lead to deviations in bone turnover; in these cases, periodontal problems are usual, and the response to orthodontic forces can be strongly influenced (6-8). The same limitation is valid for patients under chronic corticosteroid therapy (8). When the therapy aims to modify the growth of maxillary bones in quality and quantity, it can be defined as “orthopaedic”; in this case, treatments must be directed only to patients in an active growth phase because when the growth ends, the bone structure is unmodifiable (9-12).

Nowadays, radiography allows the distinction between a patient that is actively growing and one that has completed growth of the wrist radiography (Fig. 1). Rx evaluates the degree of maturation of the hand and wrist bone. The subject’s position compared to the pubertal-growing spurt allows forecasting the achievable results of the orthodontic therapy: if the growing peak is near, better and faster results can be obtained, compared to the outcomes of treatment done when the growth is slower (10).

Ultrasounds are a form of mechanical energy with the same nature as sound waves but characterized by frequencies above audible sounds. The maximum frequency above the sounds audible to human beings is about 16000 oscillations per second (16KHz); in medical echography, the frequencies are between 2 and 10 million Hz (2-10MHz). An important feature of the echography test is that tissues scanned with ultrasounds do not receive any damage. In recent years the uses of echography in different medical fields have increased so much that any body part can be explored by ultrasounds, even if different results can be achieved depending on the “echogenicity” of the examined structure (12).

A new field of use, where the first steps are now being moved, is orthodontics, to evaluate the bone growth stage and the pubertal growth peak.

Compared to radiography, echography does not imply ionized energy, which interacts with body tissues and can potentially damage their biological features. As this exam has to be repeated more than once, a young patient can be exposed to a moderate but significant amount of ionizing radiation. The use of echography can overcome this issue since it can be done multiple times without contraindications (12).

Because of its highly eco-reflecting cortex, a bone is impermeable to ultrasounds, so an echography cannot provide any diagnostic information; on the contrary, the cartilage is hypoechoic, and the different stages of ossification of the centres of bone growth are characterized by different echogenicity.

Considering these reasons, the authors proposed a controlled clinical study to evaluate the usefulness of echography in evaluating bone maturation.

## **MATERIALS AND METHODS**

The study was conducted according to the guidelines of the Declaration of Helsinki and approved by the Istituto Superiore di Sanità (Prot. 30/07/2007-0040488).

### *Experimental sample*

Fifty-four patients aged between 7 and 19 years, scheduled to undertake an orthodontic treatment, underwent standard radiography and an echography of carpus and metacarpal; 12 of them joined a follow-up protocol that took place after a year. All the subjects came to our attention between February 2016 and April 2018. The choice of these patients was made based on age and clinical indication, which need radiography of carpus and metacarpal to correct planning orthodontic therapy.

### *Radiography technique*

Standard appliances were used (Almex Group, Drachten, The Netherlands) to examine the wrists with the following characteristics (Fig. 1):

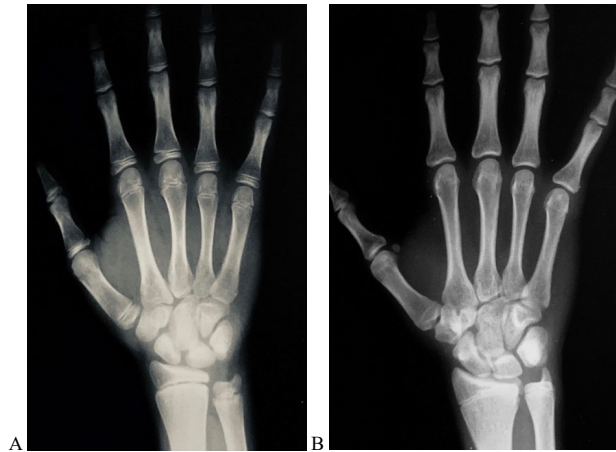
- Distance between the X-ray tube and film of 120cm;
- Film combined with rare earth screens as reinforcement;
- Exposure to 42 kV and 100 mA X-rays for 0.8 sec;
- Posteroanterior projection.

### *Echography technique*

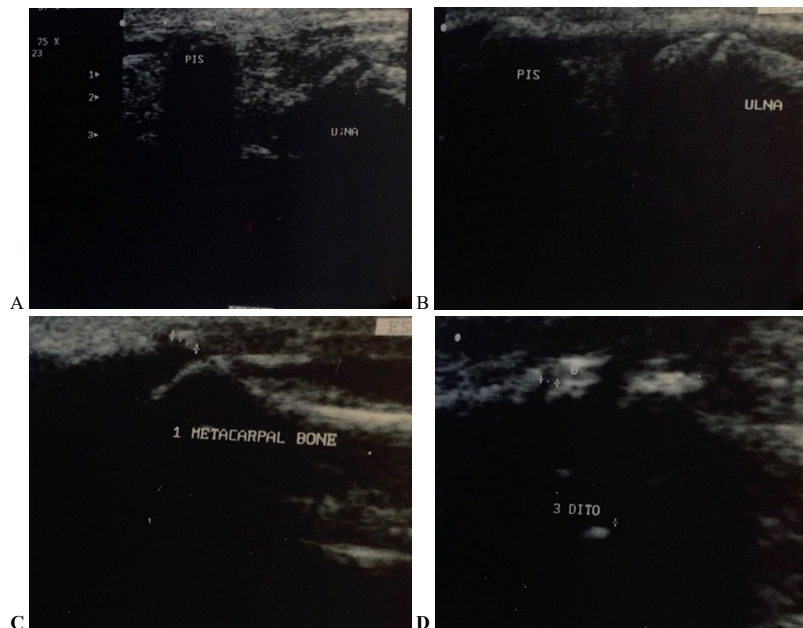
The patient’s wrists and hands were examined with a real-time echographer (Esaote Biomedica, Genoa, Italy) using a

linear 7 probe but 5 MHz and a superficial focus. The examination focused longitudinal scans patterns:

- On the wrist side, searching for the pisiform (Fig. 2A-B);
- On the metacarpal-phalanx articulation of the thumb, searching for the sesamoid (Fig. 2C);
- On the distal end of the third finger, for the evaluation of the metaphyseal cartilage.



**Fig. 1.** *A)* X-ray film of the hand at the beginning of the puberal growth phase: the pisiform nucleus is present but quite small, the sesamoid of the thumb is not ossified, and the growth cartilages of the phalanges are well evident. *B)* X-ray taken at the end of the puberal growth: The pisiform nucleus has become very large, the sesamoid of the thumb is well apparent, and the growth cartilages of the phalanges are almost completely closed.



**Fig. 2.** *A)* Wrist ultrasound during the puberal growth peak. Initial ossification of the pisiform nucleus, that becomes apparent as a hyperechoic area node determining an acoustic shadowing: it is located within the hyperechoic area corresponding to the cartilaginous portion of the nucleus. The ulnar epiphysis can be well appreciated too, together with its nucleus and with the growth cartilage, that is still present. *B)* Wrist ultrasound of the pisiform in a more advanced growth phase. The nucleus becomes very large, with respect to the previous scan, and it gives onset to a sharp cone of acoustic shadowing. *C)* Wrist ultrasound: the ossification center of the adductor tendon of the thumb becomes apparent as a hyperechoic spot with a cone of acoustic shadowing located within the tendon sheet: compare these ultrasound findings with the corresponding x-ray pictures. *D)* Hand ultrasound before the end of the puberal growth peak. The cortical profile of the distal phalanx of the third finger is interrupted by a hypoechoic band (calipers) which corresponds to the growth cartilage: this finding may be better appreciated on the x-ray film.

We proceeded with the echoscope research and measurement of all three formations using the electronic callipers incorporated in the device.

### Statistic evaluation

The radiography and echography results were first evaluated by the radiologist who performed the exam (operator 1). Then, at the end of the clinical study, the radiographs and ultrasounds of the wrists and hands of each subject were revised by a different doctor (operator 2), who did not know the patient's age or clinical history.

After this evaluation, the operator expressed the degree of bone maturity under examination, rating it with a score between 0 and 2, according to the degree of ossification of the nuclei (Table I).

The evaluation results were gathered in a tabular form. They underwent a statistic non-parametric analysis with the Wilcoxon test and a confidence interval of 95% ( $p > 0.05$ ) to establish possible discrepancies or correlations between the data obtained with the echography and the radiography. The patients that took part in the follow-up protocol underwent a second echography after a year which was compared with the previous one. Thus, the trend of growth was evaluated.

## RESULTS

Wrist echography allowed a very good view of bone and cartilage structures. In particular, the skeletal elements and the ossification nuclei are easily observed with the echography, being strongly hyperechoic images thanks to the highly acoustic reflectivity of the cortical bone, which creates an intense acoustic distal shadow cone (Fig. 2B).

With this method, even small and early-stage ossifications - as it happens in the nucleus of the thumb's sesamoid flexor- are immediately identifiable and appear similar to the calcific granulations of chalcolithic already known to the ultrasound semiotic (Fig. 2C).

During further checks, the bone growth is revealed by the increased dimension of the ossification nuclei, easily measurable with the ultrasound device callipers, and for their formation in the cartilage matrix, per se hypoechoic.

The grown plate of the phalanx, which became evident once welded the end of the growing peak, appears like a hypoechoic band that interrupts the very hyperechoic profile of the phalanx's cortical bone (Fig. 2D). It disappears gradually and, in the end, the complete structure of the hyperechoic cortical profile can be observed. However, in its intermediate stages, the evaluation of the process can be difficult due to the limits in the resolving power of the ultrasound device or the angle between the cartilage gap and the ultrasound beam.

**Table I.** Degree of bone maturity of the bone under examination rating with a score between 0 and 2, according to the degree of ossification of the nuclei.

Score	Ossification Nuclei	Metaphyseal cartilage
0	absence	partially present
1	onset	completely present
2	welded	welded

**Table II.** Statistical analysis with Wilcoxon non-parametric test that compares data obtained with echography (operator 2) and radiography (operator 1).

	Operator 1	Operator 2
Pisiform	0,043	1
Sesamoid	0,0277	0,3173
III finger cartilage	0,0045 <sup>1</sup>	0,0187

<sup>1</sup>Statistical significance,  $p < 0,005$

The examinations performed on 54 people were statistically evaluated using the Wilcoxon non-parametric test.

Both echography and radiography provided valid scores regarding the recognition and evaluation of the development of ossification nuclei of pisiform and sesamoid. However, for these bone elements, the statistical analysis did not reveal significant differences, and the evaluation of the welding of the phalanx's cartilage was less concordant (Table II).

Eight of the 12 patients checked after one year have an increase in the size of the ossification nuclei, while in the other 4 patients, the cartilage was comprehended in an already ossified nucleus.

## DISCUSSION

The results of our research confirm the validity of the wrist echography, performed with the technique for the evaluation of the soft tissues, for the evaluation of bone development and growing pubertal peak in young patients needing orthodontic treatments. The validity of the echography, confirmed by the statistical analysis, comes from its sensitivity to small solid formations, both crystalline and dense, like the ossification centres with a bone matrix, even when only in the initial phase of calcium is deposited. All these structures possess much higher acoustic impedance than soft tissues and cartilage, so for the physic that underpins the interaction between ultrasounds and tissues, ultrasound determines intense return echoes, which completely adsorb the ones coming from deeper structures (13-15). The result is a classic echographic image of the hypoechoic nodule that creates a very visible acoustic distal shadow cone: this determines the "classic" image in ultrasound diagnostic, a sign of all bone formations even if they are small (stones, splinters, foreign bodies etc.).

The extreme sensibility of the ultrasound makes this examination as valid as radiography in this field. On the contrary, the welding of the fertile metaphyseal cartilage is not that easily recognizable with an echography. However, the cartilage itself is evident, has a significant dimension within the immature bone and appears like a hypoechoic band that lies between the intense echogenicity of the metaphyseal cortex and epiphysis evident in the wrist of the young subjects at the level of the ulnar metaphyseal cartilage.

In the distal phalanx, however, the fertile cartilage part is very small; it can be well recognized in a younger subject but can be better noticeable in an echography of growing children, while it is present but small in radiography; this implies a lower sensibility of echography for the evaluation of the welding of the cartilage which can overestimate the growing peak (16). For these reasons, echography does not claim to replace radiography for evaluating the pubertal bone age and growing peak. However, it can usefully complement radiography for both initial diagnosis and following checks (quarterly or semi-annual according to the patient's age) to precociously identify the development of ossification nuclei and the phase of the growing peak (17-21). During the most advanced growth stage, the ultrasound check of the phalanx's cartilage welding can be diagnostically useful but cannot exclude another radiographic test.

The main advantage of echography, as in other fields, is its repeatability due to the lack of radiation; this is why we propose this method for screening adolescents subject to orthodontic treatments. The examination is easy, rapid, and without any inconvenience for the patient; however, one limit is that it entirely depends on the technician's skill (22, 23). This matter is, in our opinion, worthy of a further comparative multicentric study even if the experience necessary to identify bone structure is not high (24-26).

## CONCLUSIONS

Hands-wrist echography is an essential diagnostic support for evaluating bone age and growth of young patients subject to orthodontics treatment. A multicentric study should be conducted to better evaluate this method over time since the outcomes also depend on the technician's skills.

### *Author Contributions*

G.C. designed the research study, A.L. performed the research, and P.C. and A.L. wrote the manuscript. All authors contributed to editorial changes in the manuscript. All authors read and approved the final manuscript. The authors declare no conflict of interest.

## REFERENCES

1. De Sanctis V, Soliman AT, Di Maio S, Bedair S. Are the new automated methods for bone age estimation advantageous over the manual approaches? *Pediatric Endocrinology Reviews*. 2014;12(2):200-205.
2. Caccianiga G, Lo Giudice A, Paiusco A, et al. Maxillary Orthodontic Expansion Assisted by Unilateral Alveolar Corticotomy and Low-Level Laser Therapy: A Novel Approach for Correction of a Posterior Unilateral Cross-Bite in Adults. *Journal of Lasers in Medical Sciences*. 2019;10(3):225-229. doi:10.15171/jlms.2019.36
3. Lo Giudice A, Nucera R, Leonardi R, Paiusco A, Baldoni M, Caccianiga G. A Comparative Assessment of the Efficiency of Orthodontic Treatment With and Without Photobiomodulation During Mandibular Decrowding in Young Subjects: A Single-Center, Single-Blind Randomized Controlled Trial. *Photobiomodulation, Photomedicine, and Laser Surgery*. 2020;38(5):272-279. doi:10.1089/photob.2019.4747
4. Caccianiga G, Paiusco A, Perillo L, et al. Does Low-Level Laser Therapy Enhance the Efficiency of Orthodontic Dental Alignment? Results from a Randomized Pilot Study. *Photomedicine and Laser Surgery*. 2017;35(8):421-426. doi:10.1089/pho.2016.4215
5. Caccianiga G, Lo Giudice A, Longoni S, Ceraulo S, Baldoni M, Leonida A. Low-level laser therapy protocols in dental movement acceleration and in pain management during orthodontic treatment. *Journal of Biological Regulators and Homeostatic Agents*. 2019;33(6 Suppl 1):59-68.
6. Lo Giudice A, Caccianiga G, Crimi S, Cavallini C, Leonardi R. Frequency and type of ponticulus posticus in a longitudinal sample of nonorthodontically treated patients: relationship with gender, age, skeletal maturity, and skeletal malocclusion. *Oral Surgery, Oral Medicine, Oral Pathology and Oral Radiology*. 2018;126(3):291-297. doi:10.1016/j.oooo.2018.05.001
7. Caccianiga G, Crestale C, Cozzani M, et al. Low-level laser therapy and invisible removal aligners. *Journal of Biological Regulators and Homeostatic Agents*. 2016;30(2 Suppl 1):107-113.
8. Kalia S, Melsen B, Verna C. Tissue reaction to orthodontic tooth movement in acute and chronic corticosteroid treatment\*. *Orthodontics and Craniofacial Research*. 2004;7(1):26-34. doi:10.1111/j.1601-6343.2004.00278.x
9. Leonardi R, Muraglie S, Lo Giudice A, Aboulazm KS, Nucera R. Evaluation of mandibular symmetry and morphology in adult patients with unilateral posterior crossbite: a CBCT study using a surface-to-surface matching technique. *European Journal of Orthodontics*. 2020;2020:cjz106. doi:10.1093/ejo/cjz106
10. Al-Jewair TS, Preston CB, Flores-Mir C, Ziarnowski P. Correlation between craniofacial growth and upper and lower body heights in subjects with Class I occlusion. *Dental Press Journal of Orthodontics*. 2018;23(2):37-45. doi:10.1590/2177-6709.23.2.037-045.oar
11. Su N, van Wijk AJ, Visscher CM, Lobbezoo F, van der Heijden GJMG. Diagnostic value of ultrasonography for the detection of disc displacements in the temporomandibular joint: a systematic review and meta-analysis. *Clinical Oral Investigations*. 2018;22(7):2599-2614. doi:10.1007/s00784-018-2359-4
12. Liu Q, Wei X, Guan J, Wang R, Zou D, Yu L. Assessment of condylar morphology and position using MSCT in an Asian population. *Clinical Oral Investigations*. 2018;22(7):2653-2661. doi:10.1007/s00784-018-2364-7
13. Mancini G, Carinci F, Zollino I, et al. effectiveness of self-ligating orthodontic treatment. *European Journal of Inflammation*. 2011;9(2 Suppl):53-58.
14. Caccianiga G, Cambini A, Donzelli E, Baldoni M, Rey G, Paiusco A. Effects of laser biostimulation on the epithelial tissue for keratinized layer differentiation: an in vitro study. *Journal of Biological Regulators and Homeostatic Agents*. 2016;30(2 Suppl 1):99-105.
15. Lo Giudice A, Nucera R, Perillo L, Paiusco A, Caccianiga G. Is Low-Level Laser Therapy an Effective Method to Alleviate Pain Induced by Active Orthodontic Alignment Archwire? A Randomized Clinical Trial. *Journal of Evidence Based Dental Practice*. 2019;19(1):71-78. doi:10.1016/j.jebdp.2018.11.001
16. Stergiopoulos O, Houstis O, Kiliaridis S, Antonarakis GS. Changes in facial expressions following functional orthopaedic treatment for Class II division 1 malocclusion: a prospective controlled study. *European Journal of Orthodontics*. 2018;41(3):231-237. doi:10.1093/ejo/cjy047

17. Montes ABM, de Oliveira TM, Gavião MBD, de Souza Barbosa T. Occlusal, chewing, and tasting characteristics associated with orofacial dysfunctions in children with unilateral cleft lip and palate: a case-control study. *Clinical Oral Investigations*. 2017;22(2):941-950. doi:10.1007/s00784-017-2173-4
18. Algharbi M, Bazargani F, Dimberg L. Do different maxillary expansion appliances influence the outcomes of the treatment? *European Journal of Orthodontics*. 2018;40(1):97-106. doi:10.1093/ejo/cjx035
19. Nucera R, Lo Giudice A, Bellocchio M, Spinuzza P, Caprioglio A, Cordasco G. Diagnostic concordance between skeletal cephalometrics, radiograph-based soft-tissue cephalometrics, and photograph-based soft-tissue cephalometrics. *The European Journal of Orthodontics*. 2017;39(4):352-357. doi:10.1093/ejo/cjw072
20. Lo Giudice A, Fastuca R, Portelli M, et al. Effects of rapid vs slow maxillary expansion on nasal cavity dimensions in growing subjects: a methodological and reproducibility study. *European Journal of Paediatric Dentistry*. 2017;18(4):299-304. doi:10.23804/ejpd.2017.18.04.07
21. Cosgrove DO. Evolution of Ultrasonography Since the 1970s. *Ultrasound in Medicine & Biology*. 2017;43(11):2741-2742. doi:10.1016/j.ultrasmedbio.2017.06.015
22. Lo Giudice A, Rustico L, Caprioglio A, Migliorati M, Nucera R. Evaluation of condylar cortical bone thickness in patient groups with different vertical facial dimensions using cone-beam computed tomography. *Odontology*. 2020;108(4). doi:10.1007/s10266-020-00510-2
23. Mancini G, Carinci F, Aavantiato I, Puglisi P, Caccianiga G, Brunelli G. Simplicity and reliability of invisalign® system. *European Journal of Inflammation*. 2011;9(2):43-52.
24. Almeida LE, Pierce S, Zacharias J, et al. Immunohistochemical analysis of IL-1 beta in the discs of patients with temporomandibular joint dysfunction. *Cranio: The Journal of Craniomandibular Practice*. 2017;35(4):233-237. doi:10.1080/08869634.2016.1207911
25. Spampinato C, Palazzo S, Giordano D, Aldinucci M, Leonardi R. Deep learning for automated skeletal bone age assessment in X-ray images. *Medical Image Analysis*. 2017;36:41-51. doi:10.1016/j.media.2016.10.010
26. Leonardi R, Perrotta R, Almeida L, Loreto C, Musumeci G. Lubricin in synovial fluid of mild and severe temporomandibular joint internal derangements. *Medicina Oral Patología Oral y Cirugía Bucal*. 2016;21(6):e793-e799. doi:10.4317/medoral.21145





---

*Clinical Trial*

## **EVALUATION OF PHONETIC ALTERATIONS IN PATIENTS TREATED WITH F22 ALIGNERS**

V. Falconi<sup>1</sup>, L. Borgia<sup>2</sup> and A. Beretta<sup>1</sup>

<sup>1</sup>Postgraduate School of Orthodontics, University of Ferrara, Via Luigi Borsari 46, Ferrara 44121, Italy

<sup>2</sup>Vice-President, Ethical Committee, Republic of San Marino

*Correspondence to:*

Virginia Falconi, DDS

Postgraduate School of Orthodontics, University of Ferrara,

Via Luigi Borsari 46, Ferrara 44121, Italy

e-mail: virgifalco@gmail.com

### **ABSTRACT**

This research aims to determine through semi-objective and subjective analysis the inability to pronounce native language phonemes in patients receiving therapy with F22 aligners at the beginning and after 24 hours of the treatment to evaluate the adaptation in a shorter period than that considered in the literature. The protocol of our study consisted of the submission of the Fanzago speech therapy test to 30 patients before delivery of the aligners (T0), immediately after (T1) and 24 hours later (T2), evaluating 28 phonemes. We ask each patient to complete a self-assessment test immediately at T0 and to return it the next day. The data were subsequently analysed using descriptive statistics. The Fanzago test demonstrates that the alterations in the speech were detected in the phonemes [s], [ts] and [ʃ]. The phoneme [λ] substitution was already there in one patient at T0. For the phoneme [ts], pre-existing alterations at T0 were detected unrelated to the therapy with aligners. From the questionnaire results, we can deduce that most patients found alterations in the pronunciation of phonemes, but this alteration is not perceived as a discomfort. F22 aligners do not cause significant phonetic alterations representing an aesthetic therapeutic alternative with a minimal impact on speech abilities and, consequently, on patients' social and working life.

**KEYWORDS:** *orthodontic aligners, F22 aligner, speech articulation, acoustic analysis*

### **INTRODUCTION**

In modern society, the smile plays a primary role in aesthetics because it determines the psychophysical well-being of the subject (1, 2); in fact, the demand for a rapid, effective therapy that has minimal influence on social and working life is constantly increasing (3).

---

Received: 23 March 2020

Accepted: 03 May 2020

ISSN: 2038-4106

Copyright © by BIOLIFE 2020

This publication and/or article is for individual use only and may not be further reproduced without written permission from the copyright holder. Unauthorized reproduction may result in financial and other penalties. **Disclosure: All authors report no conflicts of interest relevant to this article.**

In recent decades, orthodontic appliances have been introduced to the market to satisfy these demands efficiently. The development of small vestibular brackets, lingual brackets, ceramic brackets and aligners has provided orthodontists with the possibility of being able to offer different therapeutic options that allow them to fulfil their aesthetic needs, as well as simplify sliding mechanics and minimise side effects (4) exerting light and continuous forces to avoid root resorption (5). However, lingual appliances and aligners are considered the best of all aesthetic solutions (6-8).

In 1946 an article by Dr Kesling (9) described the possibility of obtaining orthodontic movements using dental positioners created on a system of plaster models with set-up. Thanks to this method, it was possible to obtain movements of about 1 mm for each positioner. The first to propose using an invisible retainer at the end of the treatment was Dr Ponitz in 1971. In 1985, Dr McNamara (10) proposed using these retainers to optimise the final occlusion by creating a laboratory set-up that reproduced the desired movements.

In 1993, Essix retainers were introduced, highly appreciated by patients and orthodontists, thanks to their optimal aesthetics and low cost (11).

The F22 aligner results from 14 years of research at the University of Ferrara, Department of Orthodontics.

The feature that led to the success of F22 is their transparency; in fact, the transmittance values (fraction of incident light that passes through a material) detected for F22 are the highest, while the absorbance values (the inverse of transmittance) are the lowest of the samples compared, confirming that the material used for F22 is the most transparent (12). Also, clear aligner treatment can be used in addition to whitening agents to accomplish the esthetic demand and improve patient compliance (13).

Moreover, the functional aspect must be necessarily considered; an orthodontic appliance that significantly alters the patient's speech cannot be recognised as an acceptable treatment alternative for an adult. Doshi U.H. and colleagues (14), in a 2011 review, analysed several articles focusing on the correlation between malocclusion, orthodontic treatment and speech defects, discussing the difficulty that scientific research encounters in this area and stating that some malocclusions are related to language alterations, but that they are in no way proportional to the severity of the condition.

Many studies have tried to identify and quantify the difficulty in speech caused by an orthodontic appliance. Fujita's first studies (15) found that the most significant difficulties, limited in time, were recorded in the pronunciation of dental consonants [th] and that the phonetic distortions were more significant in the lingual approach.

The study by Atik's group (16), which compares the effects of Essix and Hawley's bite plate, found alterations in the vowels [e] and [u] in the group of patients with Essix and the consonant [d], even if the alterations in the group wearing Hawley's retainer were more significant, according to the study of Wan (17).

In 2006 the study conducted by the University of Ferrara, Department of Orthodontics (18) aimed to compare a phonetic analysis of patients treated with Invisalign aligners and with STb lingual brackets; results demonstrate that groups showed distortion of the phoneme [s], which was nevertheless recovered in two different times: the Invisalign group corrected the phoneme already at T1, while the STb group at T2.

Our study aims to detect, through semi-objective and subjective analysis, the inability to pronounce specific native language phonemes in patients receiving therapy with F22 aligners immediately after the positioning of aligners and 24 hours later to evaluate the adaptation of patients.

## MATERIALS AND METHODS

The protocol of our study, consisted of submitting the Fanzago speech therapy test to patients in the Department of orthodontics, University of Ferrara, in therapy with F22 aligners and the subsequent compilation by the same patients of a self-assessment questionnaire.

The sample included 30 patients about 20 years old, with mild to moderate dental misalignment requiring orthodontic treatment of both arches.

The Fanzago test was released to patients at the beginning (T0), immediately after delivery (T1), and 24 hours later (T2) in order to evaluate 28 phonemes.

Subsequently, three logopedic therapists compiled three tables for the results for each patient, relating to the three-time points included in the protocol. Column charts have also been created for a simplified visualisation of the results.

The self-assessment questionnaire was delivered to each patient at the delivery appointment, with instructions on how to complete it and return it the next day.

Three professionals carried out results from the speech therapy evaluation (semi-objective analysis), and answers to each question of the self-evaluation questionnaire (objective analysis) were subsequently analysed using descriptive statistics.

## RESULTS

Thanks to the Fanzago test, alterations were detected in the phonemes [s], [ts] and [ʃ]. In one patient, the substitution of the phoneme [λ] (replaced with the phoneme [l]) already at T0 was detected. Alterations pre-existing at T0 were detected only for the phoneme [ts], which also appeared in T1 and T2 (Fig. 1, 2).

Fig. 1 shows only the distorted phonemes; in particular, in Fig 1b, the phonemic alterations could be due to the presence of aligners in the oral cavity; only 3 of the 28 analysed (about 11%) were distorted. Moreover, in one case, the phoneme [ts] was already altered at T0 (Fig. 1a), a condition not attributable to the orthodontic therapy.

Fig. 2 shows the number of patients with phonetic alterations. For example, at T0, only 2 of 30 patients (6.7%) presented alterations in the pronunciation of phonemes, in particular, the distortion of [ts] and the substitution of [λ]. On the other hand, 6 patients (20%) showed alterations at T1 and 5 patients (17%) at T2.

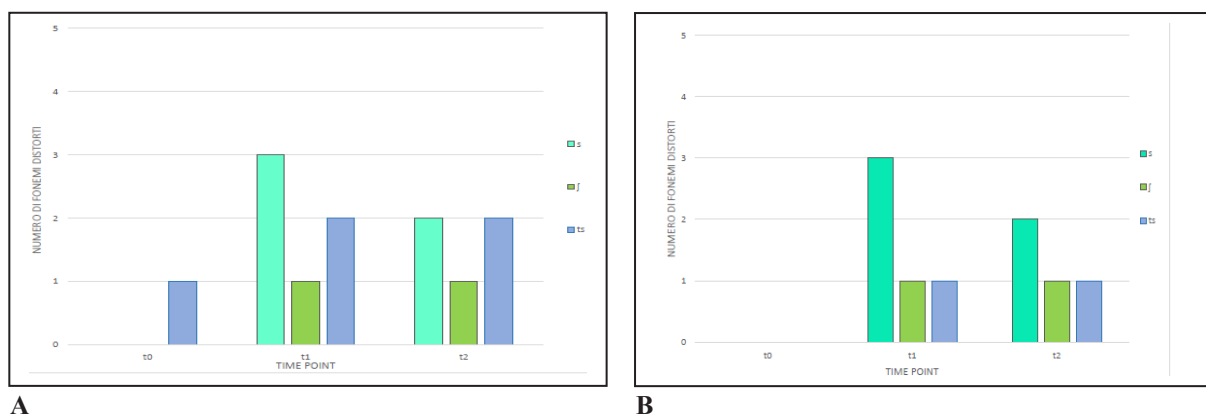


Fig. 1. **A)** Distorted phonemes at T0, T1 and T2; **B)** Distorted phonemes after CAT therapy.

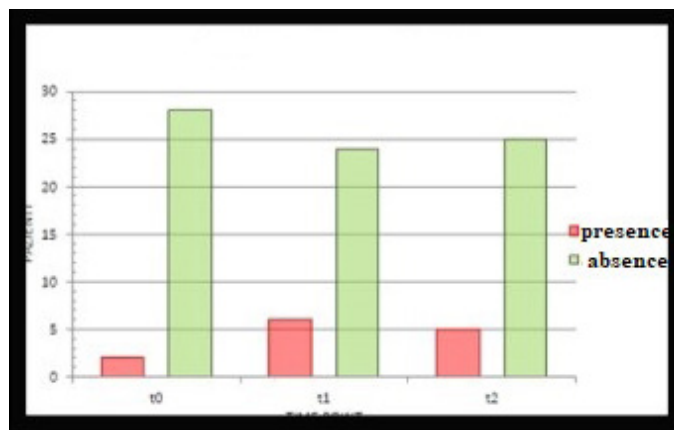


Fig. 2. Presence and absence of alteration in patients

## DISCUSSION

In the majority of the studies previously cited, the evaluation of alterations was carried out by reading a generic text including only some phonemes of the languages in question; however, excluding some phonemes does not allow a proper analysis; therefore, a complete speech test was chosen for this study, in order to evaluate 28 phonemes of the Italian language.

In the literature, only Stevens's 2011 study (19) analysed all the sounds of Canadian English. The remaining published studies used specifically formulated texts or written word lists for the speech therapy assessment. In speech therapy, the most suitable way to test patients is the spontaneous method, with evocation from images, not by reading or repetition. Therefore, the Fanzago speech test consists exclusively of words represented in the drawing that the patient must name spontaneously.

Additional advantages of this test are that it allows obtaining a numerical result (number of distorted phonemes out of the total number of phonemes analysed) and the ability to compare the various tests. Despite this, the judgment of pronunciation in various sounds is based on an opinion defined as semi-objective. It was therefore decided to subject the recordings to listening by two speech therapists and a speech therapy student to increase the validity of the results. The three professionals compiled an evaluation table for each patient for the three-time points considered. The results coincided in 100% of cases.

Phonetic alterations were detected in 6 patients out of a sample of 30. In two patients, the alterations were already present at T0, so they are not due to the presence of aligners in the oral cavity. In particular, in one of these two patients, the alteration consisted in the replacement of the phoneme [λ] with the phoneme [l], a phenomenon explained by the fact that the patient, not being a native speaker, did not possess all the linguistic sounds belonging to the Italian Phonetic Alphabet. The second patient who showed alterations at T0 was born in Ferrara and consequently had the characteristic way of articulating the phoneme [ts] according to the local dialect. Also, in this case, it is impossible to attribute the distortion to the aligners.

The tests were performed 24 hours after the delivery of aligners in order to assess the patients' short-term adaptability. Studies in the literature have shown that, after one month, the patient can adapt by eliminating all the phonetic alterations deriving from the presence of an orthodontic appliance. Therefore, our study aimed to evaluate the phonetic alterations induced by the presence of aligners in the oral cavity and the patient's ability to adapt in the first 24 hours. The results obtained allowed us to state that the influence of the aligners on phonation is reduced: distortions given by aligners were found in 4 patients out of a total of 30.

We considered it important to include in the protocol a subjective evaluation provided by patients to complete the evaluations of speech therapists. The purpose of this work includes the determination of the impact of therapy with aligners on the quality of life of patients; this self-perception test completed by patients, in addition to investigating the phonetic alterations and oral function, also focuses on methods adopted by patients to overcome these discomforts and reduce the impact of therapy on their social life.

From this investigation, we found that 28 out of 30 patients had detected phonetic alterations with the aligners; this result is comprehensible, given that the presence of aligners in the oral cavity can cause a feeling of clutter which, in some patients, may be poorly tolerated, due to the position of the tongue and the upper/lower incisors; therefore, the presence of aligners in these areas can lead to a variation of the tongue position.

Patients reported feeling uncomfortable speaking and considering a score from 0 (no alteration) to 10 (speak in a different way) to the perceived phonetic alteration; most subjects indicated values less than or equal to 5.

The choice of the proposed words results from a careful study: as already stated, the presence of aligners can cause an alteration in the tongue's position, influencing dental or alveolar phonemes. Therefore, the consonants inserted in the multiple answers are the alveolar consonants [t], [d], [n] and frequently used words containing them have been selected. Other phonemes whose pronunciation can be altered by the presence of aligners can be [s], [z], [dz] and [ts].

Most of the subjects reported have noticed that any phonetic alterations lasted for the entire first day, while for the remaining 7 patients, the adaptation took place over a few hours. This result may be because some subjects have a greater adaptive capacity, which allows them to use aligners more easily.

Eleven out of 28 patients reported having forced some words, while 6 chose to speak more slowly. Both solutions have a minimal impact on the patient's social and working life. In addition, 8 of 28 patients did not implement any strategies to improve their language, as alteration is not perceived as discomfort.

From the results of the questionnaire, we can deduce that the majority of patients have detected alterations in the pronunciation of phonemes. However, these alterations are not perceived as discomfort and are easily overcome by implementing small precautions that do not affect social life. Confirming what was found from the analysis of the results of the Fanzago test, sounds that patients perceived as most altered are the alveolar consonants, in particular [s] and [ts].

## CONCLUSIONS

The analysis conducted using the Fanzago speech test did not reveal significant changes in the pronunciation of specific phonemes after the beginning of aligners' therapy. Distortions were detected in 2 patients at T0, 6 at T1 (20%), and 5 at T2 (17%). If we exclude the patients with alterations already present at T0 from the sample, we report distortions at T1 only in 4 of 28 patients (15%) and at T2 in only 3 patients (11%).

Out of a total of 28 phonemes analysed, the alterations caused by the presence of aligners are limited to the 3 phonemes [s], [ʃ] and [ts]. In all cases, alterations are assessed as mild by the speech therapists involved in the study, which, in one out of four patients, resolved within the first 24 hours. From the self-assessment questionnaires, it emerged that patients perceived a phonetic alteration when wearing the aligners for the first time, but this appeared in a short time and had no significant influence on the patient's social life.

In conclusion, we can state that, although further investigations must be carried on, the F22 aligners do not cause significant phonetic alterations; thus, they represent an aesthetic therapeutic alternative with a minimal impact on language abilities and, consequently, on the patient's social and working life.

## REFERENCES

1. Chen M, Feng ZC, Liu X, Li ZM, Cai B, Wang DW. Impact of malocclusion on oral health-related quality of life in young adults. *The Angle Orthodontist*. 2015;85(6):986-991. doi:10.2319/101714-743.1
2. Gazit-Rappaport T, Haisraeli-Shalish M, Gazit E. Psychosocial reward of orthodontic treatment in adult patients. *The European Journal of Orthodontics*. 2010;32(4):441-446. doi:10.1093/ejo/cjp144
3. Shaw WC. Factors influencing the desire for orthodontic treatment. *The European Journal of Orthodontics*. 1981;3(3):151-162. doi:10.1093/ejo/3.3.151
4. Lombardo L, Carlucci A, Palone M, Mollica F, Siciliani G. Stiffness comparison of mushroom and straight SS and TMA lingual archwires. *Progress in Orthodontics*. 2016;17(1). doi:10.1186/s40510-016-0140-2
5. Lombardo L, Ceci M, Mollica F, Mazzanti V, Palone M, Siciliani G. Mechanical properties of multi-force vs. conventional NiTi archwires. *Journal of Orofacial Orthopedics*. 2019;80(2):57-67. doi:10.1007/s00056-018-00164-4
6. Ziuchkovski JP, Fields HW, Johnston WM, Lindsey DT. Assessment of perceived orthodontic appliance attractiveness. *American Journal of Orthodontics and Dentofacial Orthopedics*. 2008;133(4):S68-S78. doi:10.1016/j.ajodo.2006.07.025
7. Walton DK, Fields HW, Johnston WM, Rosenstiel SF, Firestone AR, Christensen JC. Orthodontic appliance preferences of children and adolescents. *American Journal of Orthodontics and Dentofacial Orthopedics*. 2010;138(6):698.e1-698.e12. doi:10.1016/j.ajodo.2010.06.012
8. Rosvall MD, Fields HW, Ziuchkovski J, Rosenstiel SF, Johnston WM. Attractiveness, acceptability, and value of orthodontic appliances. *American Journal of Orthodontics and Dentofacial Orthopedics*. 2009;135(3):276-277. doi:10.1016/j.ajodo.2008.09.020
9. Kesling HD. Coordinating the predetermined pattern and tooth positioner with conventional treatment. *American Journal of Orthodontics and Oral Surgery*. 1946;32(5):285-293. doi:10.1016/0096-6347(46)90053-1
10. McNamara JA, Kramer KL, Juenker JP. Invisible retainers. *Journal of Clinical Orthodontics*. 1985;19(8):570-578.

11. Rinchuse DJ, Rinchuse DJ. Active tooth movement with Essix-based appliances. *Journal of Clinical Orthodontics*. 1997;31(2):109-112.
12. Lombardo L, Arreghini A, Maccarrone R, Bianchi A, Scalia S, Siciliani G. Optical properties of orthodontic aligners—spectrophotometry analysis of three types before and after aging. *Progress in Orthodontics*. 2015;16(1). doi:10.1186/s40510-015-0111-z
13. Oliverio T, Cremonini F, Lombardo L, Siciliani G. Tooth Whitening in Association with Clear Aligner Treatment. *Journal of clinical orthodontics: JCO*. 2019;53(9):508-517.
14. Doshi UH, Bhad-Patil WA. Speech defect and orthodontics: a contemporary review. *Orthodontics*. 2011;12(4):340-353.
15. Fujita K. New orthodontic treatment with lingual bracket mushroom arch wire appliance. *American Journal of Orthodontics*. 1979;76(6):657-675. doi:10.1016/0002-9416(79)90211-2
16. Atik E, Esen Aydın F, Kulak Kayıkçı ME, Çiğner S. Comparing the effects of Essix and Hawley retainers on the acoustics of speech. *The European Journal of Orthodontics*. 2017;39(4):440-445. doi:10.1093/ejo/cjw050
17. Wan J, Wang T, Pei X, Wan Q, Feng W, Chen J. Speech effects of Hawley and vacuum-formed retainers by acoustic analysis: A single-center randomised controlled trial. *The Angle Orthodontist*. 2017;87(2):286-292. doi:10.2319/012716-76.1
18. Alessandrini P. Studio comparativo sulle alterazioni fonetiche provocate dagli attacchi linguali STb e dalle mascherine Invisalign. Tesi di Specializzazione in Ortognatodonzia Università di Ferrara; 2014.
19. Stevens K, Bressmann T, Gong SG, Tompson BD. Impact of a rapid palatal expander on speech articulation. *American Journal of Orthodontics and Dentofacial Orthopedics*. 2011;140(2):e67-e75. doi:10.1016/j.ajodo.2011.02.017



---

Case report

## DESQUAMATIVE GINGIVITIS: A CASE REPORT

F. Fiori

Multidisciplinary Department of Medical-Surgical and Dental Specialties, University of Campania “Luigi Vanvitelli”,  
Naples, Italy

### *Correspondence:*

Fausto Fiori, DDS

Multidisciplinary Department of Medical-Surgical and Dental Specialties,  
University of Campania “Luigi Vanvitelli”, Naples, Italy

e-mail: fausto.fiori@outlook.com

### ABSTRACT

Desquamative gingivitis (DG) is the clinical term for the gingival manifestation of mucocutaneous diseases. It is characterized by erythematous, glazed, friable, and hemorrhagic gingiva, which pains can accompany. The three principal diseases at the origin of desquamative gingivitis are oral lichen planus, pemphigus vulgaris, and mucous membrane pemphigoid. Understanding these three diseases' clinical, histological, and immunohistochemical features is crucial for the diagnosis and appropriate therapy of DG. The present work reports a case of DG to describe the diagnostic procedures and treatment.

**KEYWORDS:** *mucosa, oral, gingivitis, inflammation, erosion*

### INTRODUCTION

Desquamative gingivitis (DG) is a clinical oral manifestation of mucocutaneous disorders such as oral lichen planus, pemphigus vulgaris, and mucous membrane pemphigoid (MMP) (1). DG can also recognize different etiologies like allergic reactions, psoriasis, linear IgA disease, and Crohn's disease (2). DG appears as red, eroded, atrophic, glazed gingiva. It can be characterized by painful symptomatology, often unrelated primarily to plaque, and its disimmune nature is more commonly detected in middle-aged and older women (3). Discomfort and bleeding during daily oral hygiene manoeuvres lead to the accumulation of dental plaque (4). DG could represent a challenging condition when the attached gingiva is the only site involved. It is often misdiagnosed with the more common plaque-induced gingivitis, thus worsening the clinical manifestations leading to disease progression and involvement of several mucosal or cutaneous sites (5). Histological analysis with immunofluorescence is still the gold standard used to discriminate between the various vesiculobullous disease (6). DG manifestations are not significantly improved after conventional periodontal therapy, and the treatment includes topical or systemic immunosuppressive drugs such as corticosteroids and low laser therapy (7). Based on the different histological and immunohistochemical findings, the treatment can be further modulated: In oral lichen planus, topical retinoids can improve the clinical manifestations but cannot give clinical aid in other DG causes. During immunosuppressive therapy, caution must be paid to oral candidiasis (8).

---

Received: 08 May, 2020

Accepted: 17 July, 2020

ISSN: 2038-4106

Copyright © by BIOLIFE 2020

This publication and/or article is for individual use only and may not be further reproduced without written permission from the copyright holder. Unauthorized reproduction may result in financial and other penalties. **Disclosure: All authors report no conflicts of interest relevant to this article.**

## CASE REPORT

A 48-year-old female was visited at the Oral Pathology Unit of the University of Campania, “Luigi Vanvitelli”. The patient’s medical history highlighted an allergy to lincomycin and diabetes mellitus. The patient reported the occurrence of erosive-erythematous areas to both upper and lower attached gingiva and an itching sensation spread to all the gingiva (Fig. 1). The analysis requested included anti-desmoglein 1 antibody (DSG1), anti-desmoglein 3 antibodies (DSG3), bullous pemphigoid antigen 180 (BP180), and bullous pemphigoid antigen (BP230). The anti-BP180 tested positive at the control at 19.9 IU (negative < 9 IU). The patient underwent an incisional biopsy to perform histological analysis and direct immunofluorescence that revealed the dermal-epidermal split, eosinophil infiltration in the blister’s fluid, and IgG deposits upon the linear basement membrane with “band-like” distribution. Therefore the diagnosis of MMP was carried out, and the patient underwent topical medical therapy that consisted of clobetasol propionate twice a day and fluconazole once a day.

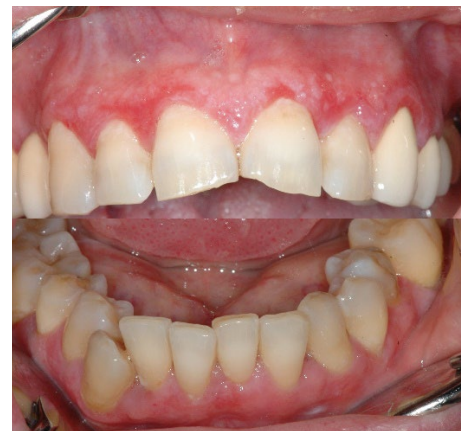## DISCUSSION

MMP is a chronic autoimmune disease characterized by the appearance of blisters on different mucosal surfaces, caused by the expression of autoantibodies (BP 180 and BP 230), one of the leading actors of cellular adhesion in the basement membrane zone that connect basal keratinocytes with the basal membrane (9). Blister development results from the linear deposition of IgG, IgA, or C3 along the mucosal and epithelial basement membranes. Several agents are described as triggering the predisposing factors, including drugs, internal malignancies, ultraviolet exposure, radiotherapy, infective agents such as Human Herpes Virus, cytomegalovirus, Epstein-Barr virus, and thermal or chemical burns (10).

Clinical manifestations of MMP comprise the appearance of blisters of varying size, varying from small vesicles corresponding to red erythematous areas to more giant vesicles (blisters <5 mm in diameter) and bullae (blisters >5 mm in size) (11). The lesions involve the mucosal surfaces lined by stratified epithelium (oral, nasal, conjunctival, laryngo-esophageal, anal, and genital mucosa). Skin lesions are infrequent and occur after mucosal manifestations that often include the upper body, head, and neck (12).

The oral cavity, especially the buccal mucosa, soft palate, and lips, is the first site affected in 90% of MMP patients (11). The oral blisters burst quickly, leaving painful erosions and ulcers, often the only clinical sign of the disease (12). The gingiva is the most commonly affected oral site in MMP. Given its autoimmune etiology, gingivitis in MMP does not improve with the elimination of plaque and tartar, unlike in common bacterial periodontal diseases associated with accumulating a microbial biofilm on tooth surfaces (13).

The treatment choices for MMP include corticosteroids (such as prednisone, clobetasol propionate, or methylprednisolone), immunosuppressive drugs (such as azathioprine, methotrexate mofetil, and cyclophosphamide) and immunomodulators (such as tacrolimus) (11). Due to the epidemiological preference for the elderly, topical therapy seems preferable to limit the systemic adverse effect that could worsen the health of medically fragile patients (14,15). Further studies are needed to provide scientific information for safer and more reliable treatment options.



**Fig. 1.** Desquamative Gingivitis: erosive-erythematous areas to both upper and lower attached gingiva

## REFERENCES

1. Suresh L, Neiders ME. Definitive and differential diagnosis of desquamative gingivitis through direct immunofluorescence studies. *Journal of Periodontology*. 2012;83(10):1270-1278. doi:10.1902/jop.2012.110627
2. Lo Russo L, Fedele S, Guiglia R, et al. Diagnostic Pathways and Clinical Significance of Desquamative Gingivitis. *Journal of Periodontology*. 2008;79(1):4-24. doi:10.1902/jop.2008.070231
3. Robinson N, Wray D. Desquamative gingivitis: A sign of mucocutaneous disorders-a review. *Australian Dental Journal*. 2003;48(4):206-211. doi:10.1111/j.1834-7819.2003.tb00033.x
4. Rinaggio J, Crossland DM, Zeid MY. A Determination of the Range of Oral Conditions Submitted for Microscopic and Direct

- Immunofluorescence Analysis. *Journal of Periodontology*. 2007;78(10):1904-1910. doi:10.1902/jop.2007.070095
5. Shaqman M, Hamdan A, Karadsheh O, Sawair F, Hassona Y. Desquamative gingivitis: a challenging diagnosis for clinicians. *British Dental Journal*. 2020;229(1):26-30. doi:10.1038/s41415-020-1848-4
  6. Yih WY, Maier T, Kratochvil FJ, Zieper MB. Analysis of desquamative gingivitis using direct immunofluorescence in conjunction with histology. *Journal of Periodontology*. 1998;69(6):678-685. doi:10.1902/jop.1998.69.6.678
  7. Garcia-Pola MJ, Rodriguez-López S, Fernánz-Vigil A, Bagán L, Garcia-Martín JM. Oral hygiene instructions and professional control as part of the treatment of desquamative gingivitis. Systematic review. *Med Oral Patol Oral Cir Bucal*. 2019;24(2):e136-e144. doi:10.4317/medoral.22782
  8. Maderal AD, Lee Salisbury P, Jorizzo JL. Desquamative gingivitis: Diagnosis and treatment. *Journal of the American Academy of Dermatology*. 2018;78(5):851-861. doi:10.1016/j.jaad.2017.04.1140
  9. Miyamoto D, Santi C, Aoki V, Maruta C. Continuing medical education. *Anais Brasileiros de Dermatologia*. 2018;94(2). doi:10.1590/abd1806-4841.20199007
  10. Moro F, Fania L, Sinagra JLM, Salemme A, Zenzo GD. Bullous Pemphigoid: Trigger and Predisposing Factors. *Biomolecules*. 2020;10(10). doi:10.3390/biom10101432
  11. Buonavoglia A, Leone P, Dammacco R, et al. Pemphigus and mucous membrane pemphigoid: An update from diagnosis to therapy. *Autoimmunity Reviews*. 2019;18(4):349-358. doi:10.1016/j.autrev.2019.02.005
  12. Ramos-e-Silva M, Ferreira A, de-Moura-Castro Jacques C. Oral involvement in autoimmune bullous diseases. *Clinics in Dermatology*. 2011;29(4):443-454. doi:10.1016/j.clindermatol.2011.01.015
  13. Jascholt I, Lai O, Zillikens D, Kasperkiewicz M. Periodontitis in oral pemphigus and pemphigoid: A systematic review of published studies. *Journal of the American Academy of Dermatology*. 2017;76(5):975-978.e3. doi:10.1016/j.jaad.2016.10.028
  14. Bernard P, Antonicelli F. Bullous Pemphigoid: A Review of its Diagnosis, Associations and Treatment. *American Journal of Clinical Dermatology*. 2017;18(4):513-528. doi:10.1007/s40257-017-0264-2
  15. Joly P, Roujeau JC, Benichou J, et al. A Comparison of Oral and Topical Corticosteroids in Patients with Bullous Pemphigoid. *New England Journal of Medicine*. 2002;346(5):321-327. doi:10.1056/nejmoa011592





Case Report

## **SINUS FLOW: A MINIMALLY INVASIVE TECHNIQUE FOR CRESTAL ACCESS TO THE MAXILLARY SINUS**

M.A. Lopez<sup>1</sup> and F. Altamura<sup>2</sup>

<sup>1</sup>Department of Head and Neck and Sensory Organs, Division of Oral Surgery and Implantology, Gemelli IRCCS Hospital - Catholic University of Sacred Heart, Rome, Italy

<sup>2</sup>Private practice, Rome, Italy

*Correspondence to:*

Michele Antonio Lopez, DDS

Department of Head and Neck and Sensory Organs, Division of Oral Surgery and Implantology,

University Polyclinic Foundation, Catholic University of Sacred Heart, Rome, Italy

e-mail: micheleantonio.lopez@unicatt.it

### **ABSTRACT**

Among the different approaches currently in use to perform sinus lift with a crestal approach, some hydrodynamic techniques use fluid biomaterials. The fluid-dynamic technique carries several advantages: first, it detaches and raises the Schneiderian membrane in a non-traumatic way avoiding dangerous stretching, which may cause perforation of the membrane; second, the biomaterial is smooth and does not have any sharp edge that can cause a rupture of the membrane; third, the microparticles of the biomaterial can be drained from the mucociliary clearance of maxillary sinus up to the ostiomeatal complex if Schneiderian membrane is broken. A case of sinus lifting with a fluid-dynamic technique is reported. This system described is operator-friendly, safe and precise.

**KEYWORDS:** *maxilla, sinus, implant, regeneration, bone*

### **INTRODUCTION**

Transcrestal sinus floor elevation is a surgical procedure performed to vertically enhance the available bone in the edentulous posterior maxilla through a hole created into the bone crest to access the sinus floor. A trans-crestal approach is not indicated if the residual height of the bone ridge is less than 4-5 mm (1), in which case, it is advisable to use a lateral approach.

A transalveolar approach for sinus floor elevation was first suggested by Tatum (2, 3) and consisted of a “green-stick fracture” of the sinus floor performed by hand tapping the socket former in a vertical direction until a fracture of the

Received: 17 aprile 2020

Accepted: 02 june 2020

ISSN: 2038-4106

Copyright © by BIOLIFE 2020

This publication and/or article is for individual use only and may not be further reproduced without written permission from the copyright holder. Unauthorized reproduction may result in financial and other penalties. **Disclosure: All authors report no conflicts of interest relevant to this article.**

sinus floor was obtained. Summers (4) successively modified this technique, suggesting a less invasive technique using a specific set of osteotomes to prepare the implant site and elevate the sinus floor. Subsequently, these techniques have undergone numerous modifications (5-8).

Among them are currently in use the hydrodynamic techniques that uses a saline solution to detach the Schneiderian membrane. An example of this method is a balloon technique (Antral Membrane Balloon Elevation) proposed by Soltan and Smiler (9), which gently detaches the membrane using a latex balloon inflated with saline solution. In addition, the crestal approach is increasingly employed where small quantities of biomaterial are required to fill the sinus cavity, when there is favourable anatomy and when it is possible to use minimally invasive drills and hydraulic techniques (10).

The fluid-dynamic technique for sinus lift is an evolution of the hydrodynamic technique, which differs from the previously described approaches since it uses fluid biomaterials instead of saline solution to detach the membrane and fill the sinus cavity. This procedure has numerous advantages: first, it detaches and elevates the Schneiderian membrane in an atraumatic way to prevent dangerous stretching of the membrane, which may cause its perforation; second, it uses a fluid and smooth biomaterial without sharp edges in order to avoid damage to the membrane; third, if an accidental laceration of the membrane occurs, the microparticles of biomaterial could be easily drained by mucociliary transport system to the ostiomeatal complex (Fig. 1). After they reach the nose, they can be expelled without any complications.

One of the most important objectives of a trans-crestal sinus lift is to achieve minimally invasive alveolar access to maintain the thickness of the residual ridge. This aspect is of paramount importance to prevent oro-antral communication if implant failure occurs (11-15). Therefore, this work aims to evaluate a system that uses cutters for bone thinning of the maxillary sinus floor equipped with millimetre stops, fluid biomaterial drivers and a micrometric piston for the gradual injection of the biomaterial.



**Fig. 1.** *The Sinus Flow kit*

## MATERIAL AND METHODS

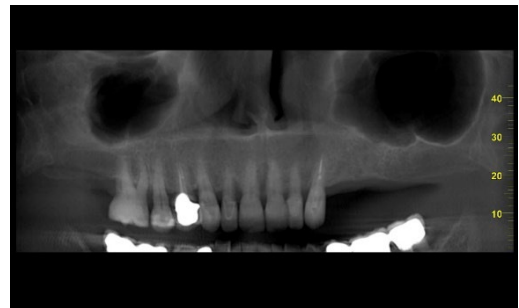
### *Clinical description of the procedure*

A 54-year-old woman presented with a residual crest of 7 mm in the first maxillary left molar area measured at Panorex and CBCT (Fig. 2-3).

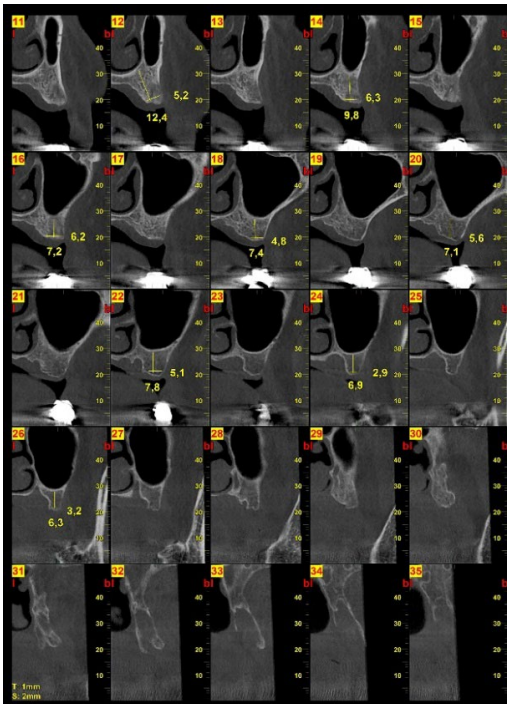
A crestal sinus lift was planned to insert an implant (CM 4.3 x 8 Neodent, Straumann Group, Basel Switzerland). After flap elevation, exposing the bone surface (Fig. 4) and placing two mesial implants, an artificial alveolus was prepared using cutters progressively increasing in diameter and with a smooth apex to protect the Schneiderian membrane (Fig. 5).

The dispenser was loaded with fluid biomaterial (Gel 40, Osteobiol, Tecnos), made up of micronised bone with lower particles and 300 microns in the measure of 60% and collagen in the measure of 40%, and inserted in the crestal hole. The tip of the dispenser was screwed inside the alveolus to enter inside the maxillary sinus with its smooth apical part for 4 mm (Fig. 6).

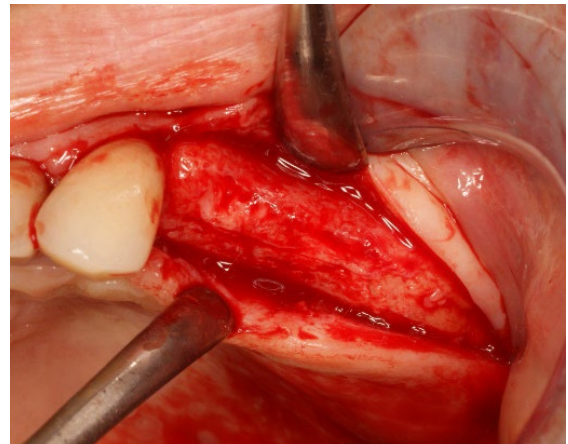
The screwing of the instrument allows the slow injection of biomaterial and the lifting of the Schneiderian membrane in an atraumatic way. The apex of the dispenser has two lateral holes which allow the simultaneous injection of the biomaterial in two directions. After filling some biomaterials, the dispenser was turned 90 degrees to fill the space surrounding the apex of the dispenser. This way, a biomaterial dome is inserted around the future implant site. Finally, the dental fixture is screwed, and control Rx is performed. The implant inserted was 4.3 x 8 mm (Fig. 7). The correct positioning of the dental implants and the biomaterial dome in the maxillary sinus is visible in the control X-ray (Fig. 8).



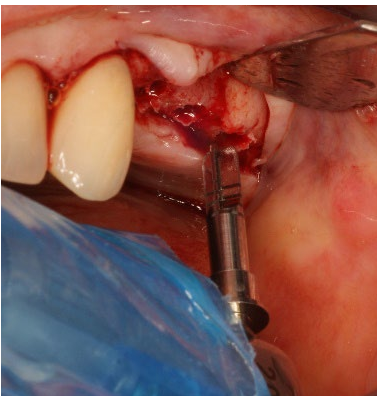
**Fig. 2.** *Initial Panorex before surgery*



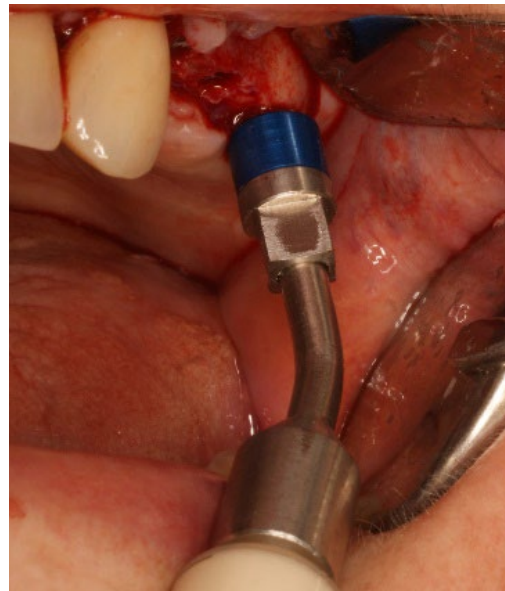
**Fig. 3.** Initial axial scan sections before surgery.



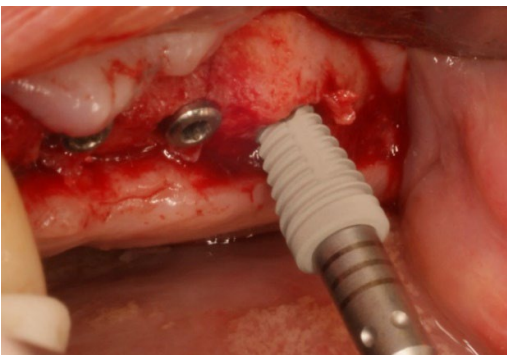**Fig. 4.** Surgical site after exposing the bone surface.



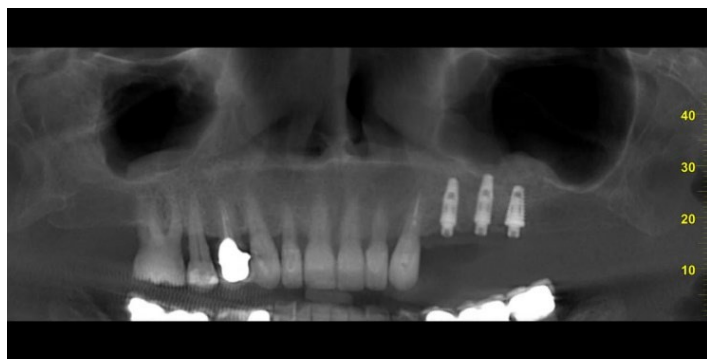
**Fig. 5.** Low cutting capacity drill at the apical level.



**Fig. 6.** The dispenser of fluid biomaterial



**Fig. 7.** Implant placement



**Fig. 8.** Final X-ray check

## DISCUSSION

One of the most frequent reasons for sinus lift via crestal approach failure is connected to the perforation of the Schneiderian membrane, which, once lacerated, cannot contain the graft material. An intact and containing membrane is essential for implant success: the biomaterial must be stabilised in place so it can be remodelled and then transformed into new bone supporting the implant portion located in the sinus. Recently, different techniques and instruments have been developed to reduce the incidence of this complication (6-15).

The proposed technique combines the burs' high accuracy and minor trauma with the predictable hydraulic detachment of the Schneiderian membrane. The main points of the technique are the specific rounded profile burs together with depth-stops, providing predictable discontinuation of the maxillary sinus floor and at the same time safely preserving the soft tissues, and the progressive hydraulic detachment of the Schneiderian membrane and the contemporary filling of the sub-antral space with the graft material.

In addition, the exclusive use of rotary instruments, rather than the more traditional osteotomy technique, implies the elimination of percussive trauma, with a direct decrease in the patient's discomfort as was previously (4, 5). Furthermore, the possibility of performing a crestal sinus lift through a thin alveolus (about only 3 mm in diameter) allows for inserting small-diameter implants. In addition, the risk of an oro-antral communication is reduced in case of implant failure since the communication between the sinus and oral cavity is extremely thin.

Dedicated cutters facilitate the thinning of the maxillary sinus floor with a reduced apical cut that allows one to carry out a non-traumatic procedure. In conclusion, the proposed technique has numerous advantages. To our knowledge, however, additional cases are needed to confirm the effectiveness of this surgical technique.

## REFERENCES

1. Testori T, Panda S, Clauser T, et al. Short implants and platelet-rich fibrin for transcresal sinus floor elevation: a prospective multicenter clinical study. *Journal of Biological Regulators and Homeostatic Agents*. 2019;33(6 Suppl. 2):121-135.
2. Tatum H. Maxillary and sinus implant reconstructions. *Dental Clinics of North America*. 1986;30(2):207-229.
3. Tatum H. Endosteal implants. *CDA journal*. 1988;16(2):71-76.
4. Summers RB. Conservative osteotomy technique with simultaneous implant insertion. *Dental Implantology Update*. 1996;7(7):49-53.
5. Esposito M, Cannizzaro G, Barausse C, Cosci F, Soardi E, Felice P. Cosci versus Summers technique for crestal sinus lift: 3-year results from a randomised controlled trial. *European Journal of Oral Implantology*. 2014;7(2):129-137.
6. Fugazzotto PA. The Modified Trepine/Osteotome Sinus Augmentation Technique: Technical Considerations and Discussion of Indications. *Implant Dentistry*. 2001;10(4):259-264. doi:10.1097/00008505-200110000-00009
7. Fugazzotto PA. Immediate implant placement following a modified trephine/osteotome approach: success rates of 116 implants to 4 years in function. *The International Journal of Oral & Maxillofacial Implants*. 2002;17(1):113-120.
8. Fugazzotto PA, Vlassis J. Long-term success of sinus augmentation using various surgical approaches and grafting materials. *The International Journal of Oral & Maxillofacial Implants*. 1998;13(1):52-58.
9. Soltan M, Smiler DG. Antral Membrane Balloon Elevation. *Journal of Oral Implantology*. 2005;31(2):85-90. doi:10.1563/0-773.1
10. Gatti F, Gatti C, Tallarico M, Tommasato G, Meloni S, Chiapasco M. Maxillary Sinus Membrane Elevation Using a Special Drilling System and Hydraulic Pressure: A 2-Year Prospective Cohort Study. *The International Journal of Periodontics & Restorative Dentistry*. 2018;38(4):593-599. doi:10.11607/prd.3403
11. Lopez MA, Bassi MA, Confalone L, Carinci F. Maxillary Sinus Floor Elevation via Crestal Approach. *Journal of Craniofacial Surgery*. 2014;25(2):e127-e132. doi:10.1097/scs.0000000000000457
12. Bassi MA, Lopez MA, Confalone L, Carinci F. Hydraulic Sinus Lift Technique in Future Site Development. *Implant Dentistry*. 2015;24(1):117-124. doi:10.1097/id.0000000000000200
13. Andreasi Bassi M. Clinical and histomorphometric outcome in future site development performed with a nano-hydroxyapatite through hydraulic sinus lift technique. *Oral & Implantology*. 2017;10(4):468. doi:10.11138/orl/2017.10.4.468

14. Andreasi Bassi M, Andrisani C, Lopez MA, Gaudio RM, Lombardo L, Lauritano D. Endoscopically controlled hydraulic sinus lift in combination with rotary instruments: one-year follow-up of a case series. *Journal of Biological Regulators and Homeostatic Agents*. 2016;30(2 Suppl 1):21-28.
15. Winter AA, Pollack AS, Odrich RB. Placement of implants in the severely atrophic posterior maxilla using localised management of the sinus floor: a preliminary study. *The International Journal of Oral & Maxillofacial Implants*. 2002;17(5):687-695.