


European Journal of Musculoskeletal Diseases

SUPPLEMENT



1818 Ingres riproduse su tela la morte di Leonardo come la racconta Vasari. Petit Palais, Parigi



Published by
Biolife

www.biolife-publisher.it



CONTENTS

STABILIZATION OF THE LOWER DENTURE THROUGH THE USE OF FINE MINI-IMPLANTS: RETROSPECTIVE STUDY. G. Falisi, E. Qorri, G. Botticelli, S. Rastelli, A. Scarano, R. Gatto, D. Kostandini, M. Gallardo Rodriguez, M. Mondragon and P. Di Giacomo.....	1-7
INFRARED THERMOGRAPHIC EVALUATION OF TEMPERATURE MODIFICATIONS INDUCED DURING IMPLANT SITE PREPARATION WITH CONICAL DRILLS. S.R. Tari, S.A. Gehrke, M. Elkabir and A. Scarano.....	8-13
COEXISTENCE OF INTRACRANIAL SOLITARY FIBROUS TUMORS (SFT) AND MENINGIOMA IN A SINGLE PATIENT. G. Bettini, F. De Negri, S. Cozza, E. Orsitto, R. Amore and A. Scarano.....	14-20
THE ROLE OF PERI-IMPLANT CREVICULAR FLUID IN THE DIAGNOSIS AND TREATMENT OF ORAL PERI-IMPLANTITIS: A SCOPING REVIEW. A. Falco, S.A. Gehrke, A. Scarano and S.R. Tari.....	21-27
DENTAL ISSUES FOLLOWING THE PLACEMENT OF ORTHODONTIC MINI-SCREWS. A. Laforgia, G. Dipalma, A.D. Inchingolo, S. Chieppa, V. Colonna, F.C. Tartaglia, S.R. Tari, C. Bugea, M. Corsalini, A. Palermo, F. Inchingolo and A.M. Inchingolo.....	28-36
ANTIBACTERIAL ACTIVITY OF TITANIUM NITRIDE COATING: A SYSTEMATIC REVIEW. S. Oliva, A. Scarano, O. Trubiani, S.R. Tari, M. Capogreco, C. Bugea and G. Murmura.....	37-44
PROTEIN ADSORPTION ON IMPLANT SURFACES TREATED WITH ATMOSPHERIC PLASMA. A. Scarano, S.A. Gehrke, M. Nicotra, G. Di Palma and S.R. Tari.....	45-49
SURFACE ELECTROMYOGRAPHY AS AN EVALUATION TOOL FOR BITE THERAPY IN PATIENTS WITH CRANIO-MANDIBULAR PAIN: A SYSTEMATIC REVIEW. A. Mancini, F. Inchingolo, A. M. Inchingolo, F. Cardarelli, F. Piras, L. Ferrante, A. Palermo, A. Scarano, S. R. Tari, A. D. Inchingolo and G. Dipalma.....	50-66



Retrospective study

STABILIZATION OF THE LOWER DENTURE THROUGH THE USE OF FINE MINI-IMPLANTS: RETROSPECTIVE STUDY

G. Falisi^{1†}, E. Qorri², G. Botticelli^{1†}, S. Rastelli^{1†}, A. Scarano^{3*}, R. Gatto¹, D. Kostandini², M. Gallardo Rodriguez⁴, M. Mondragon⁴ and P. Di Giacomo⁵

¹Department of Life Health and Environmental Sciences, University of L'Aquila, L'Aquila, Italy;

²Department of Dentistry, Faculty of Medical Science, Albanian University, Tirana, Albania;

³Department of Innovative Technology in Medicine and Dentistry, University of Chieti-Pescara, Chieti, Italy;

⁴Mexican College of Oral and Maxillofacial Implantology, Mexico City, Mexico;

⁵Department of Oral and Maxillo-Facial Sciences, Sapienza University of Rome, Italy

*These authors contributed equally to the first author

Correspondence to:

Antonio Scarano, DDS

Department of Innovative Technology in Medicine and Dentistry,

University of Chieti-Pescara,

Strada Marcello Mucci 38/B,

66100 Chieti, Italy

e-mail: ascarano@unich.it

ABSTRACT

This retrospective study aimed at evaluating the survival rate of mini implants used for stabilizing the total prosthesis in patients affected by mandibular atrophy. The implants had a length of 10mm, a diameter of 2mm, and a monolithic spherical connection. Twenty-five patients were evaluated according to a clinical and radiographic protocol with a 24-month follow-up. Repeated measures ANOVA with time (T0, T1, and T2) as a within-subjects factor and Bone Quality (D1, D2, D3/D4) as a between-subjects factor was performed, with a statistical significance $p < 0.05$. The success rate was higher in patients with D1 and D2 interforaminal bone quality. Good primary retention and minimal prosthetic loading are requirements for mini-implant survival. Within the limits of this study, the technique provides for the immediate stabilization of removable prostheses with minimal economic and biological cost, offering a valid alternative to implant-supported prostheses.

KEYWORDS: *mini dental implants, removable prosthesis, overdentures, atrophic mandible.*

INTRODUCTION

The rehabilitation of edentulism in atrophic jaws is quite complex when it involves fragile patients with compromised clinical and economic conditions. The most requested prosthetic treatment that improves the quality of life is the implant-supported one (1, 2). Unfortunately, the quality of bone that hosts the implant itself and the alveolar ridge expansion are key requirements of implant-supported prostheses, which are far from being cheap and conservative from a biological point of view.

Received: 06 May 2024
Accepted: 03 June 2024

ISSN 2038-4106 print
ISSN 2975-044X online

Copyright © by BIOLIFE 2024

This publication and/or article is for individual use only and may not be further reproduced without written permission from the copyright holder. Unauthorized reproduction may result in financial and other penalties. Disclosure: All authors report no conflicts of interest relevant to this article.

Since 2002, overdenture supported by two implants had become the first choice in prosthetic rehabilitation (3, 4). However, more recently, mini-implants (MDIs) to support overdentures have become increasingly accepted (5-8). The MDIs have characteristics that distinguish them from standard implants: they have a smaller diameter (less than 3 mm); as a main feature, they do not consist of two pieces but are monolithic and have spherical attachments to stabilize the conventional prostheses. In addition, they may be used in narrow alveolar ridges (9).

MDIs may be considered for frail patients requiring less invasive procedures, as they can be placed without opening a flap and performing complex surgical procedures (9, 10). Due to the low-cost and less invasive nature of MDIs and their ability to be flapless, it has become a new focus in implant research for rehabilitation in the inter-foraminal zone (11, 12). In this regard, inconsistent results on MDI survival have been reported over the years.

The aim of the retrospective work was to evaluate the effectiveness of a new implant (EASY IMPLANT MACO) in stabilizing the lower removable prostheses.

MATERIAL AND METHOD

The authors developed a retrospective study of patients recruited between 2014 and 2017 in the following Institutes: the Department of Odontostomatology of the University of L'Aquila, the College of Dentistry and Implantology of Mexico City, and the Department of Dentistry of the Albanian University. The Ethics Committee of the Albanian University (n°181 prot date 24-02-2023) approved the study, and all patients signed an informed consent form.

Patient selection

One hundred and sixty patients who needed stabilization of the lower removable total denture were examined. All patients were studied through our new clinical protocol, which also included a gnathological evaluation by DC/TMD (Diagnostic Criteria for Temporomandibular Disorders) to assess the functional status of the stomatognathic system. The following exclusion criteria were applied for the selection of the study group:

- smoking of more than 12 cigarettes per day;
- risk factors such as bisphosphonate therapy, radiation therapy of the head and neck region in the previous 12 months;
- poor oral hygiene;
- inability to undergo the follow-up protocol.

The following inclusion criteria were applied for the selection of the study group:

- Age over 18 years;
- total lower edentulism or expected by post-extractive surgery due to the presence of strictly compromised teeth;
- mandibular atrophy with type 1, type 2, type 3, and type 4 residual crest;
- consent to participate in the study.

Of the 160 patients, 30 were excluded because they were heavy smokers, 41 had elevated risk factors, 26 were on bisphosphonate therapy, five had temporomandibular osteoarthritis, eight had poor oral hygiene, and 25 could not follow the protocol. The final sample consisted of 25 subjects, including 11 men between 66 and 83 (mean age of 74.5) and 14 women between 65 and 78 (mean age of 71.5) (Table I).

Protocol

The sample was subjected to preventive anamnestic and CBCT imaging tests to assess bone quality and define a treatment plan (13) (Fig. 1).

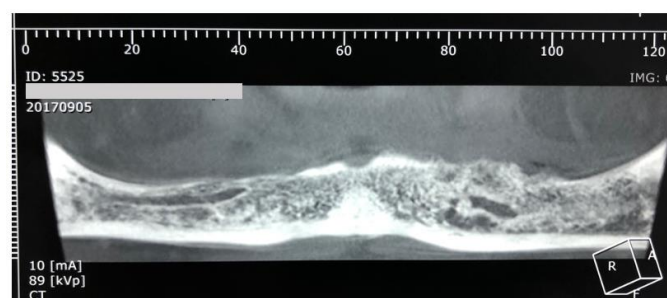


Fig. 1. CBCT – panorex.

The selected subjects underwent implant surgery using 4 mini-implants (10mm long, 2mm diameter in the inter-foraminal area, with an insertion torque of 45 Nw) Easy implant Maco (Fig. 2).

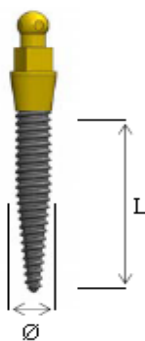


Fig. 2. *Easy implant Maco.*

This type of implant is a grade 5 titanium alloy (TiAl6V4), sandblasted and double-etch, with a surface roughness of 1–2 μm . Teflon o-ring attachments, as already experienced in other scientific works, were used to stabilize the definitive removable prosthesis. Our surgical protocol provided oral antibiotics (2 g of amoxicillin 1 hour before and 1 g every 12 hours for 5 days) (14). Patients were asked to rinse with 0.12% chlorhexidine for 1 minute while the skin was disinfected with Betadine 10% skin solution. Four implants are placed in the inter-foraminal area, keeping a distance of 1.5 mm from the knee of the mandibular nerve. Once the insertion points were identified and marked with a dermal pencil, the mucous membrane was perforated with the same preparation cutter (Fig. 3).

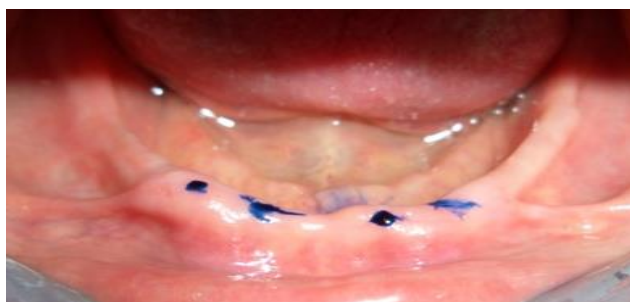

Fig. 3. *Locating insertion points.*

The Maco Easy protocol was used to position the mini-implants. This protocol provided for using a single cutter with a diameter of 1.5 mm. The milling depth provided for type D1 was the entire implant length, type D2 2/3 of the implant length, type D3 1/3 of the implant length, and type D4 only 2 mm. of depth. A calibrated manual ratchet with an insertion torque of 35 N was used for the implant insertion. In the inter-foraminal areas, 4 implants were inserted for 100 (Fig. 4).

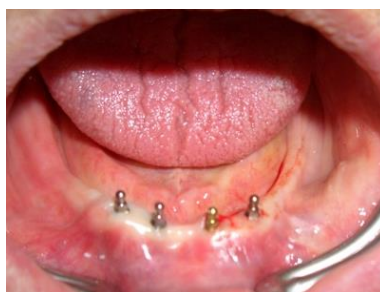

Fig. 4. *Insertion of Implants.*

In the same session, the patients' prostheses were stabilized through o-ring attacks and post-surgical and maintenance instructions were given (Fig. 5).



Fig. 5. *O-RING for prosthetic stabilization*

All patients were placed in a program with semi-liquid feeding for one month. Follow-up was performed in addition to periodic visits, during which radiographic checks assessed the state of implant response over time. Therefore, an orthopantomography was performed yearly (Fig. 6-7).

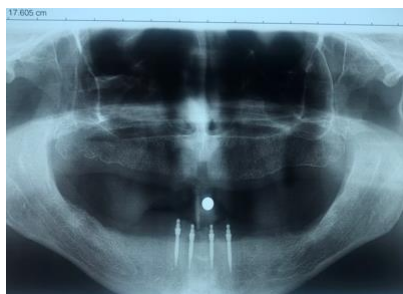

Fig. 6. *One-year follow-up.*

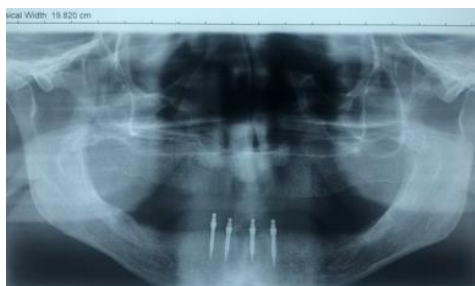

Fig. 7. *Two-year follow-up.*

Statistical analysis

Repeated measures ANOVA with time (T0, T1, and T2) as a within-subjects factor and Bone Quality (D1, D2, D3/D4) as a between-subjects factor was performed. Post-hoc tests were performed. A two-tailed value of $p < 0.05$ was regarded as significant. All analyses were performed with JASP Version 0.8.0.1, downloadable at <https://jasp-stats.org/download/>. Results were controlled using SPSS 24, and no discrepancy was found (Table I).

Table I. Data collected.

Paz	Gender	Age	Bone	Implant	6 month	1 Year	2 Year
1	F	67	D2	4	0	0	0
2	F	75	D3	4	1	3	Failed
3	F	73	D2	4	0	0	1
4	M	66	D3	4	1	2	1
5	F	71	D3	4	2	2	Failed
6	M	76	D1	4	0	0	0
7	M	80	D2	4	0	0	0
8	M	73	D2	4	0	1	0
9	F	67	D3	4	1	2	Failed
10	F	65	D2	4	1	0	0
11	M	69	D2	4	0	0	0
12	F	70	D3	4	2	2	Failed
13	F	78	D2	4	0	1	0
14	M	66	D1	4	0	0	1
15	F	72	D3	4	1	1	2 Failed
16	F	73	D2	4	0	0	1
17	M	66	D2	4	1	0	0
18	F	69	D1	4	1	0	0
19	M	68	D2	4	0	0	0
20	F	67	D2	4	0	0	0
21	M	74	D2	4	0	0	0
22	M	76	D3	4	1	3	Failed
23	F	77	D2	4	1	0	1
24	F	72	D2	4	0	1	0
25	M	83	D1	4	0	0	2

RESULTS

Four subjects had D1 quality, 14 had D2, and 7 had D3. No statistical significance between these groups was found. As for the parameters under consideration, there was an effect of time, with a statistical significance ($p < 0.001$) and significant differences over time, as reported in post-hoc tests. As for the interaction between time and bone quality, significant differences between D1-T2 and D3-T2, D2-T2 and D3-T2, D1-T3 and D2-T3 were reported in post-hoc test ($p < 0.001$). There was a strong effect of bone quality as a between-subject factor with $p < 0.001$ (Table II, Fig. 8).

Table II. Repeated measures ANOVA as for within and between subjects factors.

	F value	P value
Within subjects effect		
<i>Time</i>	43.80	< 0.001
<i>Time * Bone Quality</i>	19.17	< 0.001
Between subjects effect		
<i>Bone Quality</i>	64.09	< 0.001

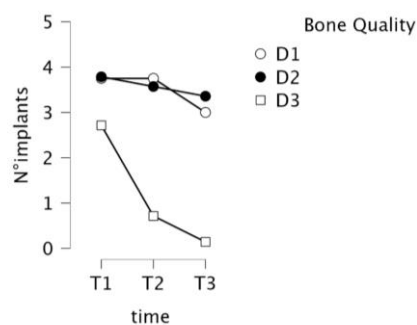


Fig. 8. shows the trend over time concerning bone quality *in the graph below*.

DISCUSSION

The choice of the implant length and where to place it may be a problem when surgery has to be planned. Noble anatomical structures such as the alveolar nerve, the mental nerve, or the alveolar artery may represent a challenge (15).

Therefore, MDIs with a reduced diameter would become the first choice in these cases, but the conformation of these implants could compromise their mechanical and biological survival (16). The literature reports inconsistent opinions on the implant survival of MDIs. Souza et al. showed a lower survival (85%) than that of conventional implants (99%) (17).

Other works described a survival rate of immediate loading MDIs of around 95% (18). Differences in the assessment may have been influenced by biomechanical factors such as implant length and biological factors such as bone quality (19). Failure was associated with excessive loading, resulting in fatigue fracture of the implant (20). Furthermore, the type of attachment system provides for different degrees of horizontal and vertical resistance against dislocation forces; in fact the use of resin caps would be better in reducing such loads, compared to O-rings which could lead to different transmission sizes of the load at the implant-bone interface, as reported by Fatalla et al. (21). Furthermore, the failure of the integration can be found in various factors such as the lack of primary stability, due to an over-preparation of the osteotomy site or to the quality of the underlying bone (22).

Poorer-quality bone can also result in poor primary stability and subsequent failure. Many authors have recognized the importance of primary stability and that implants should be loaded only after reaching stability of 35 Ncm (23-25). In our work, the loss of implants with a length of 10mm was evaluated. As for the quality of the bone, there are differences between D1-D3 and D2-D3 but no difference between D1 and D2 over time.

An effect of time was observed regarding the parameters considered, with statistical significance ($p < 0.001$) and significant differences over time. As reported in the post-hoc tests, this effect is greater in patients with D3. In fact, as for the interaction between time and bone quality, significant differences were reported between D1-T2 and D3-T2, D2-T2 and D3-T2, D1-T3 and D3-T3, and D2-T3 and D3-T3. A strong effect of bone quality as a between-subject factor was found with $p < 0.001$. This leads us to two considerations; the first is that the quality of the bone significantly influences implant survival, with the D1/D2 type more compact and good for primary stability, while as for the D3/D4 type, bicorticalism and therefore longer implants should be exploited. The protocol is also burdened by an immediate load rather than a deferred one.

CONCLUSIONS

Within the limits of this study, although implant loss occurred in patients with bone type D3/D4, it can be concluded that medium-term MDI survival is close to one of the regular diameter implants. The advantages of the mini-implant technique are the immediate stabilization of the removable prosthesis at a minimum economic and biological cost, offering a valid alternative to implant-supported prosthesis, especially for frail patients, thus becoming the first-choice treatment.

REFERENCES

1. Falisi G, Di Paolo C, Rastelli C, et al. Ultrashort Implants, Alternative Prosthetic Rehabilitation in Mandibular Atrophies in Fragile Subjects: A Retrospective Study. *Healthcare (Basel)*. 2021;9(2):doi:<https://doi.org/10.3390/healthcare9020175>

2. Scarano A, Di Carmine M, Al-Hamed FS, Khater AGA, Gehrke SA, Tari SR. Socket Shield Technique to Improve the Outcomes of Immediate Implant: A Systematic Review and Meta-Analysis. *Prosthesis*. 2023;5(509–526).
3. Feine JS, Carlsson GE, Awad MA, et al. The McGill consensus statement on overdentures. Mandibular two-implant overdentures are the first choice standard of care for edentulous patients. *Gerodontology*. 2002;19(1):3-4.
4. Thomason JM. The McGill Consensus Statement on Overdentures. Mandibular 2-implant overdentures as first choice standard of care for edentulous patients. *Eur J Prosthodont Restor Dent*. 2002;10(3):95-96.
5. Sivaramakrishnan G, Sridharan K. Comparison of patient satisfaction with mini-implant versus standard diameter implant overdentures: a systematic review and meta-analysis of randomized controlled trials. *Int J Implant Dent*. 2017;3(1):29. doi:<https://doi.org/10.1186/s40729-017-0092-4>
6. Lemos CA, Verri FR, Batista VE, Junior JF, Mello CC, Pellizzer EP. Complete overdentures retained by mini implants: A systematic review. *J Dent*. 2017;57(4-13). doi:<https://doi.org/10.1016/j.jdent.2016.11.009>
7. Lorusso F, Mastrangelo F, Inchingolo F, Mortellaro C, Scarano A. In vitro interface changes of two vs three narrow-diameter dental implants for screw-retained bar under fatigue loading test. *J Biol Regul Homeost Agents*. 2019;33(6 Suppl. 2):115-120 DENTAL SUPPLEMENT.
8. Scarano A, Conte E, Mastrangelo F, Greco Lucchina A, Lorusso F. Narrow single tooth implants for congenitally missing maxillary lateral incisors: a 5-year follow-up. *J Biol Regul Homeost Agents*. 2019;33(6 Suppl. 2):69-76 DENTAL SUPPLEMENT.
9. Singh RD, Ramashanker, Chand P. Management of atrophic mandibular ridge with mini dental implant system. *Natl J Maxillofac Surg*. 2010;1(2):176-178. doi:<https://doi.org/10.4103/0975-5950.79225>
10. Bidra AS, Almas K. Mini implants for definitive prosthodontic treatment: a systematic review. *J Prosthet Dent*. 2013;109(3):156-164. doi:[https://doi.org/10.1016/S0022-3913\(13\)60035-9](https://doi.org/10.1016/S0022-3913(13)60035-9)
11. Duraisamy R, Ganapathy DM, Rajeshkumar S, Ashok V. Mini-Implants in Dentistry - A Review. *J Long Term Eff Med Implants*. 2022;32(3):29-37. doi:<https://doi.org/10.1615/JLongTermEffMedImplants.2022041814>
12. Scarano A, Murmura G, Carinci F, Lauritano D. Immediately loaded small-diameter dental implants: Evaluation of retention, stability and comfort for the edentulous patient. *European Journal of Inflammation*. 2021;10(19–23).
13. Mikic M, Vlahovic Z, Stevanovic M, Arsic Z, Mladenovic R. The Importance of Correlation between CBCT Analysis of Bone Density and Primary Stability When Choosing the Design of Dental Implants-Ex Vivo Study. *Tomography*. 2022;8(3):1293-1306. doi:<https://doi.org/10.3390/tomography8030107>
14. Botticelli G, Severino M, Ferrazzano GF, Vittorini Velasquez P, Franceschini C, Di Paolo C. Excision of Lower Lip Mucocele Using Injection of Hydrocolloid Dental Impression Material in a Pediatric Patient: A Case Report. *Appl Sci*. 2021;11(13):5819.
15. Alshenaiber R, Silikas N, Barclay C. Does the Length of Mini Dental Implants Affect Their Resistance to Failure by Overloading? *Dent J (Basel)*. 2022;10(7):doi:<https://doi.org/10.3390/dj10070117>
16. Scurria MS, Morgan ZVt, Guckes AD, Li S, Koch G. Prognostic variables associated with implant failure: a retrospective effectiveness study. *Int J Oral Maxillofac Implants*. 1998;13(3):400-406.
17. de Souza RF, Ribeiro AB, Della Vecchia MP, et al. Mini vs. Standard Implants for Mandibular Overdentures: A Randomized Trial. *J Dent Res*. 2015;94(10):1376-1384. doi:<https://doi.org/10.1177/0022034515601959>
18. Griffiths TM, Collins CP, Collins PC. Mini dental implants: an adjunct for retention, stability, and comfort for the edentulous patient. *Oral Surg Oral Med Oral Pathol Oral Radiol Endod*. 2005;100(5):e81-84. doi:<https://doi.org/10.1016/j.tripleo.2005.06.018>
19. Mundt T, Schwahn C, Stark T, Biffar R. Clinical response of edentulous people treated with mini dental implants in nine dental practices. *Gerodontology*. 2015;32(3):179-187. doi:<https://doi.org/10.1111/ger.12066>
20. Allum SR, Tomlinson RA, Joshi R. The impact of loads on standard diameter, small diameter and mini implants: a comparative laboratory study. *Clin Oral Implants Res*. 2008;19(6):553-559. doi:<https://doi.org/10.1111/j.1600-0501.2007.01395.x>
21. Fatalla AA, Song K, Du T, Cao Y. A three-dimensional finite element analysis for overdenture attachments supported by teeth and/or mini dental implants. *J Prosthodont*. 2012;21(8):604-613. doi:<https://doi.org/10.1111/j.1532-849X.2012.00883.x>
22. Falisi G, Foffo G, Severino M, Di Paolo C, Bianchi S, Bernardi S. SEM-EDX Analysis of Metal Particles Deposition from Surgical Burs after Implant Guided Surgery Procedures. *Coatings*. 2022;12(2):240.
23. Tomasi C, Idmyr BO, Wennstrom JL. Patient satisfaction with mini-implant stabilised full dentures. A 1-year prospective study. *J Oral Rehabil*. 2013;40(7):526-534. doi:<https://doi.org/10.1111/joor.12053>
24. Falisi G, Severino M, Rastelli C, et al. The effects of surgical preparation techniques and implant macro-geometry on primary stability: An in vitro study. *Med Oral Patol Oral Cir Bucal*. 2017;22(2):e201-e206. doi:<https://doi.org/10.4317/medoral.21286>
25. Malchiodi L, Scarano A, Quaranta M, Piattelli A. Rigid fixation by means of titanium mesh in edentulous ridge expansion for horizontal ridge augmentation in the maxilla. *Int J Oral Maxillofac Implants*. 1998;13(5):701-705.



Evaluation Study

INFRARED THERMOGRAPHIC EVALUATION OF TEMPERATURE MODIFICATIONS INDUCED DURING IMPLANT SITE PREPARATION WITH CONICAL DRILLS

S.R. Tari¹, S.A. Gehrke², M. Elkabir³ and A. Scarano¹

¹Department of Innovative Technologies in Medicine & Dentistry, University of Chieti-Pescara, Italy;

²Department of Research, Bioface/PgO/UCAM, Montevideo, Uruguay, Department of Biotechnology, Universidad Católica de Murcia (UCAM), Murcia, Spain;

³Department of Surgery, University of Tripoli, Tripoli, Lybia

Correspondence to:

Antonio Scarano, M.D., D.D.S.

Strada Marcello Mucci 38/B,

66100 Chieti, Italy

e-mail: ascarano@unich.it

ABSTRACT

Several research studies have explored the impact of drilling on bone healing. Various factors have been identified as affecting the increase in temperature during surgical preparation for implant placement. These factors include drill design, material, depth of drilling, sharpness of the cutting instrument, drilling velocity, pressure exerted on the drill, preference for graduated or one-step drilling, intermittent versus continuous drilling, and the presence or absence of irrigation. This research aimed to measure the temperature fluctuations in cortical bone and at the tip of the drills while preparing implant sites using a conical implant drill. The drill system was evaluated in a laboratory using cortical bone from bovine femurs. This system used a conical drill with triple twist and triple twist drills. Site preparation commenced, and the temperatures of the cortical bone and the tip of the drill were recorded using infrared thermography. The average temperature recorded in the cortical bone during implant preparation was $30.2 \pm 0.5^\circ\text{C}$ while the average temperature recorded at the tip of the drill during implant site preparation was $32.1 \pm 0.5^\circ\text{C}$. No statistically significant differences were observed in the temperatures recorded in the cortical bone and at the tip of the drill. The experimental setup employed in this study successfully measured the temperature changes in both the cortical bone and the tip of the drills. The temperature changes at the drill's tip seemed to be related to the tool's geometric shape. The results of this study show that drill geometry significantly impacts how much heat is produced when implant sites are being prepared. The drill's design or form could explain the increased temperature at the drill's tip.

KEYWORDS: dental implant, drilling, heat generation, osseointegration, infrared thermography

INTRODUCTION

Dental implants have become a popular and reliable option for replacing missing teeth, with high success rates (1). They depend mainly on achieving adequate bone healing and establishing osseointegration (2). The complex process of bone healing around dental implants includes the activation of periosteal and endosteal lining cells, the growth and differentiation of pre-osteoblasts into osteoblasts, the production and mineralization of osteoid matrix, and the final organization of the bone-implant interface (3, 4). Primary healing must occur for a dental implant to be successful (3). Thus ensuring the implant location is prepared without stress (5).

Received: 24 April 2024

Accepted: 20 May 2024

ISSN 2038-4106 print

ISSN 2975-044X online

Copyright © by BIOLIFE 2024

This publication and/or article is for individual use only and may not be further reproduced without written permission from the copyright holder. Unauthorized reproduction may result in financial and other penalties. Disclosure: All authors report no conflicts of interest relevant to this article.

While creating the implant site, friction between the drill and bone inevitably generates heat. If not properly managed, this heat can lead to a detrimental complication known as thermal damage. On the other hand, heat produced by drilling during implant site preparation may cause bone damage. Research suggests that temperatures exceeding 47°C for over a minute can be harmful. Higher temperatures and extended thermal exposure enhance this danger and can compromise bone tissue repair (6), delayed healing, bone loss, and pain. In addition to mechanically harming the affected bone, dental site preparation raises the temperature of the surrounding bone in the vicinity of the implant site.

Over the past ten years, numerous researchers have endeavored to characterize the interface structure between implants and bone (4, 7, 8). A predictable degree of success in integrating implants with bone has been attained through implementing a gentle surgical technique under sterile conditions, a healing period devoid of loading, and introducing macroretentive commercially pure titanium implants (9). A few studies have examined how drilling affects bone mending (10); after drilling holes in the bone and implanting dental crowns, cellular and molecular reactions begin, constituting the wound-healing response (3). An approximate temperature of 56°C is produced during surgical preparation for implant insertion. Interestingly, alkaline phosphatase becomes denatured at this temperature, which slows down the mending of bones (11).

Necrosis brought on by high temperatures has previously been documented in the literature (12). The authors of this study have previously utilized a thermocouple and infrared thermographic to measure temperature changes induced during implant site preparation in a bovine rib model (2, 12). Subsequently, they developed a model to visualize temperature changes during implant site preparation under saline irrigation. A study employing external irrigation during the drilling of bovine bone revealed that temperature increases, as detected by the thermocouple, were notably higher in the cortical bone and escalated with an increasing number of drill uses (13).

This study aimed to compare temperature variations, assessed using infrared thermography, generated under an external irrigation system during bone preparation for implants utilizing a conical implant drill.

MATERIALS AND METHODS

The effectiveness of the implant drills was assessed using bovine femoral cortical bone in a laboratory setup. The lower portion of the bone was immersed in a temperature-controlled saline solution at 26.0°C. Site preparation commenced once the internal temperature of the bone, measured via infrared thermography, equaled the bath temperature of 26.0°C±0.1°C. Saline solution at room temperature was used for continuous irrigation during drilling at a 50 mL/min rate. Thermal measurements were conducted in a climate-controlled environment (temperature: 23-24°C, relative humidity: 53±5%, and no direct airflow onto the bone). The implant drill system evaluated was a triple twist system (Isomed System, Due Carrare, Padova, Italy). Four sets of new drills were assessed, and all drilling procedures were conducted at a speed of 800 revolutions per minute (rev/min). Intermittent drilling occurred at 2-second intervals while the bone remained submerged in the thermostat-controlled saline bath.

An experienced implantologist (AS) performed all drilling to ensure the closest possible replication of real-life scenarios. Thermal image series during implant site preparation were captured using a 14-bit digital infrared camera (FLIR SC3000 QWIP, FLIR Systems, Danderyd, Sweden) (Fig. 1).




Fig. 1. Thermogram illustrating the area of maximal thermal emission of cortical bone and drill during the use of a drill.

The acquisition parameters included a 320x240 Focal Plane Array, 8-9 μm spectral range, 0.02 K Noise Equivalent Temperature Differences (NETD), 50 Hz sampling rate, optics with a germanium lens, aperture settings at f/20 and f/1.5. The camera was positioned 0.50 meters away from the bone to achieve maximum spatial resolution. Images were acquired at a rate of 25 per second and later realigned using an edge-detection-based method implemented in

proprietary software. Temperature variations in the cortical bone and at the tip of the drill were determined based on these images.

Statistical evaluation

The primary outcome measures were the changes in temperature (both mean and maximum) of the cortical bone at the implant site and at the tip of the drill, expressed as the mean \pm standard deviation of the three drills for each system, measured upon completion of implant site preparation. The thermal image video also allowed for assessing variations in drilling durations between the two systems. The significance of observed differences was assessed using Student's t-test, with a two-tailed significance level of <0.05 considered statistically significant. Statistical analysis was evaluated using SPSS 14 for Windows.

RESULTS

Thermal image series during implant site preparation were captured and evaluated (Fig. 1). The average temperature generated in the cortical bone during implant preparation (Fig. 2, 3) was $30.5\pm 0.5^{\circ}\text{C}$ at the drill tip was $31.2\pm 0.5^{\circ}\text{C}$.

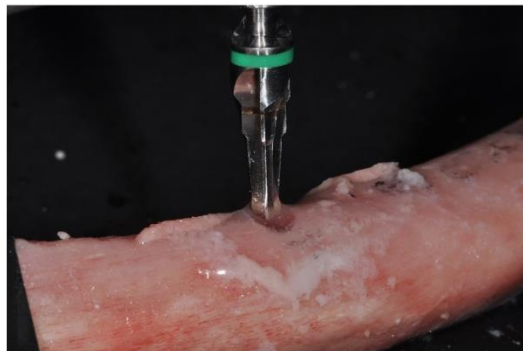

Fig. 2. Area of cortical bone during the initial phase of implant bed preparation.

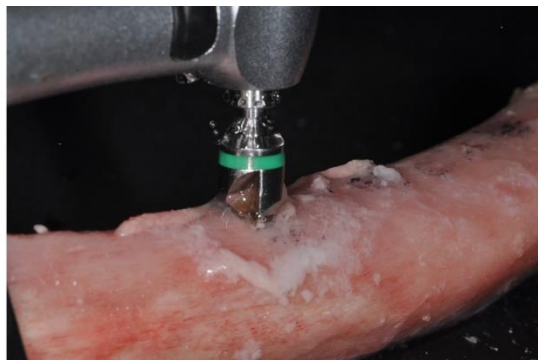

Fig. 3. Area of cortical bone during the end phase of implant bed preparation.

The maximum and mean temperature variations that were seen during drilling in the designated area were displayed in Table I. The highest temperatures that were measured were below the level that is thought to be dangerous for bone health.

Table I. Maximum and mean temperature variations seen during drilling

Basal bone temperature $26^{\circ}\pm 0.5^{\circ}\text{C}$		
	Max T cortical bone $^{\circ}\text{C}$	Max T apical portion of drill $^{\circ}\text{C}$
Temperature	$30.5\pm 0.5^{\circ}\text{C}$	$31.2\pm 0.5^{\circ}\text{C}$

Statistical evaluation

Data analysis statistically revealed no differences between the temperature measurements at the cortical bone and the tip of the drill ($p\geq 0.05$).

DISCUSSION

The temperatures produced during implant site preparation rise with increased drill usage, according to a previous study (13). Many more elements have also been shown to influence the increase in temperature during the surgical preparation for implant insertion. These variables include drill material (10, 14), drill geometry (15, 16), drilling depth (17), sharpness of the cutting tool (18), drilling speed (19), pressure applied to the drill (18), use of graduated versus one-step drilling (20), intermittent versus continuous drilling (21), and use of internal or external irrigation (22). Various drill designs and geometries have been suggested over the years (17, 23). Primarily, they are based on conventional geometrical shapes used to drill metals.

According to Matthews and Hirsch (17), under certain surgical circumstances without external irrigation, cortical temperatures in a human femoral cortex model approached 100°C during osteotomy preparation. Drills' overall performance may be affected by several factors, including the material's durability. Recent studies have suggested that implant failures may be influenced by the impact of drilling on bone (22). As a result, the investigation of the localized consequences of drilling was the particular emphasis of this work. Heat generation is one clinically significant and sometimes dangerous side effect of drilling. The soft tissues covering the bone may receive heat from the metal drill head in the cortical bone. Many drill designs, geometries, and metals have been presented over the years (23, 24), each with claimed benefits, although most are based on conventional drill geometry.

According to certain research, heat produced during drilling operations is a significant factor in implant failure (25, 26). This is because the heat generated within the bone may cause the periosteum to lose vitality (27), the bone to become devascularized, and alkaline phosphatase denatured.

When preparing the implant bed, avoiding bone damage from both heat and mechanical forces is critical. During surgery, rotary instruments are the main tool used to cut bone. These instruments can produce heat and damage. Additionally, clogging the cutting flutes in these devices may result in ineffective cutting (28). Various clinicians have been known to apply different pressures to the drill, and this variability may be related to the heterogeneous structure of bone tissue.

The model system of this study performed a good job of evaluating temperature variations in the drill tip and cortical bone, and it showed a relationship with drill shape. The results of this investigation highlight how important drill geometry is for producing heat when preparing an implant site. Interestingly, neither the degree of drill use nor the possible effects of sterilization or disinfection were considered in this investigation. Although various factors can affect bone temperature and drill-cutting efficiency separately, their combined effect is clinically significant. The temperature rise during surgical preparation for implant placement is influenced by a number of factors, including the geometry of the drill flute, the depth of the drilling, the sharpness of the cutting tool, the speed at which the drilling is done, the pressure at which the drill is operated, whether graduated or one-step drilling is preferred, whether intermittent or continuous drilling is carried out and whether internal or external irrigation is used. Given these variables, it is possible to speculate that temperatures in clinical settings may be higher than those recorded in this study.

CONCLUSIONS

In conclusion, the drill's configuration greatly impacts how much heat is produced while drilling. The heat recorded on the cortical bone and drill tip was significantly lower than the bone damage when using a conical implant drill with an external irrigation system.

Acknowledgments

The authors acknowledge the helpful technical assistance of Dr Francesco Tricca in the experimental setup and the invaluable contribution of Dr Caramanico Antonio in executing the graphic material. Isomed, Due Carrare, Padova, Italy kindly supplied all equipment and materials used in this research.

REFERENCES

1. Albrektsson T, Lekholm U. Osseointegration: current state of the art. *Dent Clin North Am.* 1989;33(4):537-554.
2. Scarano A, Piattelli A, Assenza B, et al. Infrared thermographic evaluation of temperature modifications induced during implant site preparation with cylindrical versus conical drills. *Clin Implant Dent Relat Res.* 2011;13(4):319-323. doi:https://doi.org/10.1111/j.1708-8208.2009.00209.x
3. Slaets E, Carmeliet G, Naert I, Duyck J. Early trabecular bone healing around titanium implants: a histologic study in rabbits. *J Periodontol.* 2007;78(3):510-517. doi:https://doi.org/10.1902/jop.2007.060183
4. Piattelli A, Scarano A, Piattelli M. Detection of alkaline and acid phosphatases around titanium implants: a light microscopical and histochemical study in rabbits. *Biomaterials.* 1995;16(17):1333-1338. doi:https://doi.org/10.1016/0142-9612(95)91049-5
5. Eriksson RA, Albrektsson T, Magnusson B. Assessment of bone viability after heat trauma. A histological, histochemical and vital microscopic study in the rabbit. *Scand J Plast Reconstr Surg.* 1984;18(3):261-268. doi:https://doi.org/10.3109/02844318409052849
6. Ercoli C, Funkenbusch PD, Lee HJ, Moss ME, Graser GN. The influence of drill wear on cutting efficiency and heat production during osteotomy preparation for dental implants: a study of drill durability. *Int J Oral Maxillofac Implants.* 2004;19(3):335-349.
7. Thomsen P, Larsson C, Ericson LE, Sennerby L, Lausmaa J, Kasemo B. Structure of the interface between rabbit cortical bone and implants of gold, zirconium and titanium. *J Mater Sci Mater Med.* 1997;8(11):653-665. doi:https://doi.org/10.1023/a:1018579605426
8. Scarano A, Pecora G, Piattelli M, Piattelli A. Osseointegration in a sinus augmented with bovine porous bone mineral: histological results in an implant retrieved 4 years after insertion. A case report. *J Periodontol.* 2004;75(8):1161-1166. doi:https://doi.org/10.1902/jop.2004.75.8.1161
9. Brånemark PI, Zarb GA, Albrektsson T. *Tissue-Integrated Prosthesis: Osseointegration in Clinical Dentistry*; Quintessence; 1985.
10. Augusto Alves Bento V, Marcela de Luna Gomes J, Davi Del Rei Daltro Rosa C, et al. Steel drills versus zirconia drills on heat generation at the surgical site of dental implants: A systematic review and meta-analysis. *Saudi Dent J.* 2024;36(1):1-10. doi:https://doi.org/10.1016/j.sdentj.2023.09.001
11. Leunig M, Hertel R. Thermal necrosis after tibial reaming for intramedullary nail fixation. A report of three cases. *J Bone Joint Surg Br.* 1996;78(4):584-587.
12. Scarano A, Carinci F, Quaranta A, Di Iorio D, Assenza B, Piattelli A. Effects of bur wear during implant site preparation: an in vitro study. *Int J Immunopathol Pharmacol.* 2007;20(1 Suppl 1):23-26. doi:https://doi.org/10.1177/039463200702001s06
13. Jacobs CH, Pope MH, Berry JT, Hoaglund F. A study of the bone machining process-orthogonal cutting. *J Biomech.* 1974;7(2):131-136. doi:https://doi.org/10.1016/0021-9290(74)90051-7
14. Scarano A, Lorusso F, Noubbissi S. Infrared Thermographic Evaluation of Temperature Modifications Induced during Implant Site Preparation with Steel vs. Zirconia Implant Drill. *J Clin Med.* 2020;9(1):doi:https://doi.org/10.3390/jcm9010148
15. Chacon GE, Bower DL, Larsen PE, McGlumphy EA, Beck FM. Heat production by 3 implant drill systems after repeated drilling and sterilization. *J Oral Maxillofac Surg.* 2006;64(2):265-269. doi:https://doi.org/10.1016/j.joms.2005.10.011
16. Wiggins KL, Malkin S. Drilling of bone. *J Biomech.* 1976;9(9):553-559. doi:https://doi.org/10.1016/0021-9290(76)90095-6
17. Matthews LS, Hirsch C. Temperatures measured in human cortical bone when drilling. *J Bone Joint Surg Am.* 1972;54(2):297-308.
18. Agren E, Arwill T. High-speed or conventional dental equipment for the removal of bone in oral surgery. 3. A histologic and microradiographic study on bone repair in the rabbit. *Acta Odontol Scand.* 1968;26(3):223-246. doi:https://doi.org/10.3109/00016356809026135
19. Eriksson RA, Adell R. Temperatures during drilling for the placement of implants using the osseointegration technique. *J Oral Maxillofac Surg.* 1986;44(1):4-7. doi:https://doi.org/10.1016/0278-2391(86)90006-6
20. Adell R. Tissue integrated prostheses in clinical dentistry. *Int Dent J.* 1985;35(4):259-265.
21. Benington IC, Biagioni PA, Briggs J, Sheridan S, Lamey PJ. Thermal changes observed at implant sites during internal and external irrigation. *Clin Oral Implants Res.* 2002;13(3):293-297. doi:https://doi.org/10.1034/j.1600-0501.2002.130309.x
22. Jacob CH, Berry JT. A study of the bone machining process--drilling. *J Biomech.* 1976;343-349.
23. Saha S, Pal S, Albright JA. Surgical drilling: design and performance of an improved drill. *J Biomech Eng.* 1982;104(3):245-252. doi:https://doi.org/10.1115/1.3138356
24. Piattelli A, Piattelli M, Mangano C, Scarano A. A histologic evaluation of eight cases of failed dental implants: is bone overheating the most probable cause? *Biomaterials.* 1998;19(7-9):683-690. doi:https://doi.org/10.1016/s0142-9612(97)00172-5

25. Piattelli A, Scarano A, Piattelli M. Histologic observations on 230 retrieved dental implants: 8 years' experience (1989-1996). *J Periodontol.* 1998;69(2):178-184. doi:<https://doi.org/10.1902/jop.1998.69.2.178>
26. Baumgart F, Kohler G, Ochsner PE. The physics of heat generation during reaming of the medullary cavity. *Injury.* 1998;29 Suppl 2(B11-25). doi:[https://doi.org/10.1016/s0020-1383\(98\)80058-2](https://doi.org/10.1016/s0020-1383(98)80058-2)
27. Ochsner PE, Baumgart F, Kohler G. Heat-induced segmental necrosis after reaming of one humeral and two tibial fractures with a narrow medullary canal. *Injury.* 1998;29 Suppl 2(B1-10). doi:[https://doi.org/10.1016/s0020-1383\(98\)80057-0](https://doi.org/10.1016/s0020-1383(98)80057-0)
28. Cordioli G, Majzoub Z. Heat generation during implant site preparation: an in vitro study. *Int J Oral Maxillofac Implants.* 1997;12(2):186-193.



Case report

COEXISTENCE OF INTRACRANIAL SOLITARY FIBROUS TUMORS (SFT) AND MENINGIOMA IN A SINGLE PATIENT

G. Bettini¹, F. De Negri², S. Cozza¹, E. Orsitto³, R. Amore⁴ and A. Scarano⁵

¹Radiology Unit, Azienda USL Toscana Nord Ovest, Pisa, Italy;

²Center of Clinical Pharmacology for Drug Experimentation, Azienda Ospedaliera Universitaria Pisana, Pisa, Italy;

³Radiology Unit, Emergency Department, Azienda Ospedaliera Universitaria Pisana, Pisa, Italy;

⁴Master course in Aesthetic Medicine, Department of Medical, Oral and Biotechnological Sciences, University of Chieti-Pescara, Italy;

⁵Department of Innovative Technologies in Medicine and Dentistry, University of Chieti-Pescara, Chieti-Pescara, Italy

Correspondence to:

Gloria Bettini, MD

Radiology Unit

Azienda USL Toscana Nord Ovest

Pisa, Italy

e-mail: gloria.bettini@uslnordovest.toscana.it

ABSTRACT

Solitary fibrous tumor of the CNS is a relatively rare neoplasm with a variable prognosis. It usually appears as a solitary mass, with CT and MRI features similar to those typically associated with meningiomas. Here, we present a particularly rare and interesting case because two different lesions coexist. One is a histologically confirmed solitary fibrous tumor, and the other has MRI and CT features of meningioma. This case exemplifies the different imaging characteristics of the two lesion types well.

KEYWORDS: *solitary fibrous tumor, meningioma, computed tomography imaging, magnetic resonance imaging*

INTRODUCTION

Meningiomas are the most common mass lesion of the dura and account for about 38% of intracranial tumors in women and 20% in men. However, several other dural lesions mimic their imaging features (1). These include metastatic disease, solitary fibrous tumors (SFT), glioblastoma, and melanoma, as well as non-neoplastic processes such as tuberculosis.

Solitary fibrous tumor (SFT) is a spindle-cell mesenchymal tumor first described by Klemperer and Rabin in 1931 as a distinct pathological entity involving the pleura. Subsequently, it was described in various extrapleural sites, such as the lung, liver, and breast (2-4). About 40% of extrapleural tumors arise in the subcutaneous tissue, while the remaining cases occur in other sites, such as deep soft tissues, retroperitoneum, mediastinum, and abdominal cavity.

In 1996, Carneiro et al. (5) described the first 7 cases of SFT involving the central nervous system (CNS): meningeal tumors that could be distinguished from fibrous meningioma on morphological and immunohistochemical grounds.

Received: 20 April 2024
Accepted: 15 May 2024

ISSN 2038-4106 print
ISSN 2975-044X online

Copyright © by BIOLIFE 2024

This publication and/or article is for individual use only and may not be further reproduced without written permission from the copyright holder. Unauthorized reproduction may result in financial and other penalties. Disclosure: All authors report no conflicts of interest relevant to this article.

Prominent branching hemangiopericytoma-like vasculature is a characteristic finding. There is an ongoing debate among sarcoma-trained pathologists on the best way to differentiate SFT from hemangiopericytoma (HPC). Recent studies have shown that most soft tissue SFT and HPC share inversion at 12q13, a fusion of NAB2 and STAT6 genes (6). As a result, HPS and SFT have been integrated into a new entity, "solitary fibrous tumor/hemangiopericytoma (SFT/HPC)", in the 2016 WHO classification of CNS tumors (7). Recently, STAT6 proved to be a highly sensitive immunohistochemical marker, almost perfectly specific for SFT, useful to distinguish this tumor from histological mimics, i.e., other mesenchymal tumors and spindle-cell sarcomas (desmoid fibromatosis malignant nerve sheath tumor peripheral, etc.) (8). SFT prognosis varies with histological grade, ranging from benign lesions (grade I) to more aggressive tumors (grade II-III) (1).

Intracranial SFT exhibits aggressive biological behavior with a 5-year recurrence rate close to 50% after surgical resection and an extraneural metastasis rate of up to 30% after initial surgery (9).

Clinical presentation

A 42-year-old woman was referred by her GP to a maxillofacial surgeon for a headache, particularly in the left temporal area, which worsened with chewing. Then, she came to our attention to undergo an MRI of her temporomandibular joints.

Investigations/Imaging findings: MR Imaging

The first MRI sequences showed an expansive lesion, so the exam was converted into a brain-cranial MRI that explored the skull and brain without and with contrast.

The T1- and T2-weighted sequences showed a lesion of 55 mm maximal diameter, isointense to the grey matter (Fig. 1-2). The DWI sequence demonstrated a moderate and diffuse restriction, confirmed by the ADC map (Fig. 3). In T1VIBE post-contrast acquisition, the lesion presented a diffuse enhancement (Fig. 4-5).

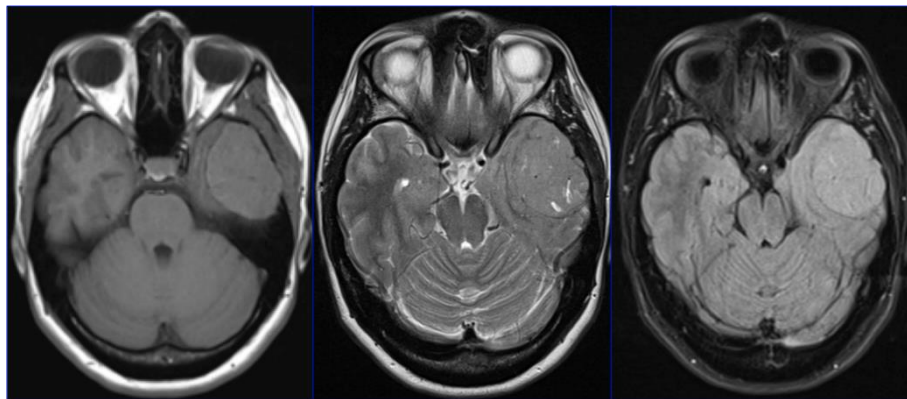


Fig. 1. Brain MRI: T1, T2, and FLAIR sequence showing the expansive lesion.

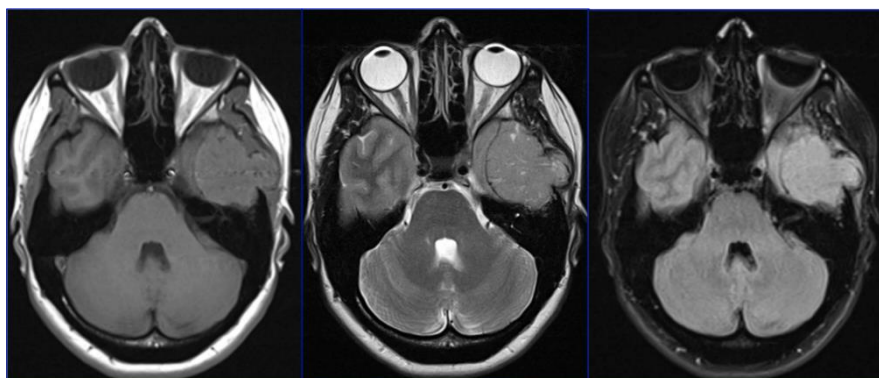


Fig. 2. Brain MRI: T1, T2, and FLAIR sequence showing the expansive lesion and the bone involvement.

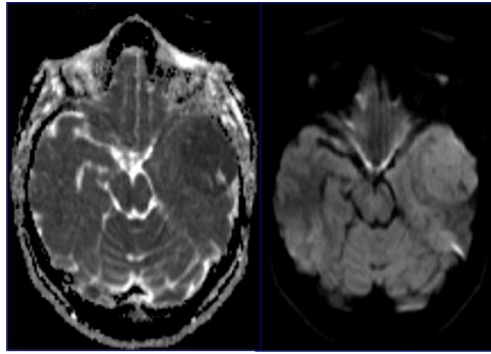


Fig. 3. Brain MRI: DWI and ADC map.

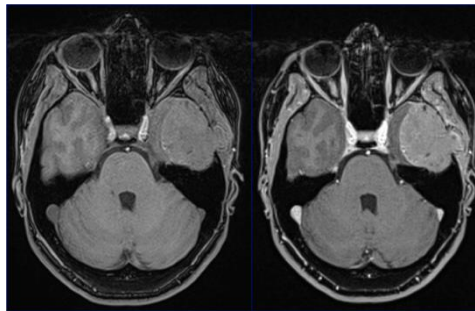


Fig. 4. Brain MRI: T1 VIBE e post-contrast T1 VIBE showing the high enhancement.

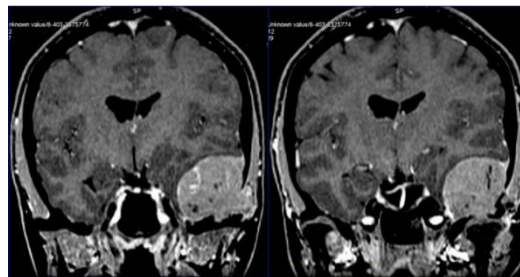


Fig. 5. Brain MRI: Coronal reformat of post-contrast T1 VIBE showing the high enhancement, the temporal involvement, and the temporomandibular joint involvement.

In addition to the described lesion, in the right temporal area, it was possible to appreciate another minor lesion (9.9 mm of maximum diameter), with signal characteristics similar to those of the larger one, isointense to the grey matter in the weighted T1 and T2 sequences. This lesion, however, was attached to the squama of the right temporal bone, presenting a broad dural base with clear hyperostosis (instead of erosion and invasion) (Fig. 6-8).

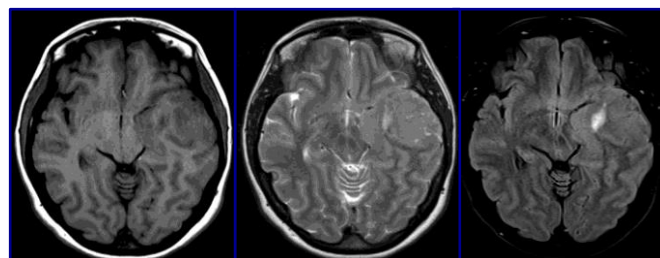


Fig. 6. Brain MRI: T1, T2, and FLAIR sequence showing the right temporal lesion and hyperostosis.

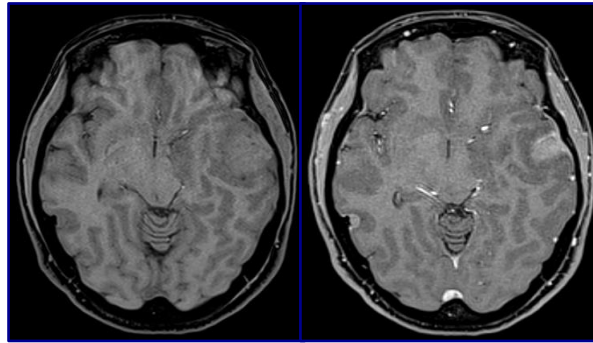


Fig. 7. Brain MRI: T1 VIBE e post-contrast T1 VIBE showing the meningioma's enhancement.

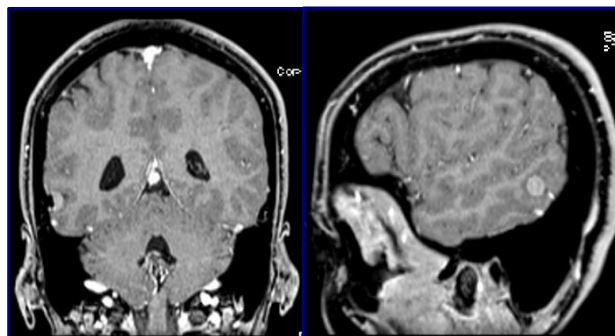


Fig. 8. Brain MRI: Coronal and sagittal reformat of post-contrast T1 VIBE showing the meningioma's enhancement.

CT Imaging

The brain CT confirmed the presence of both left and right temporal lesions, and the bone reconstruction algorithm highlighted skull involvement and hyperostosis (Fig. 9-10).

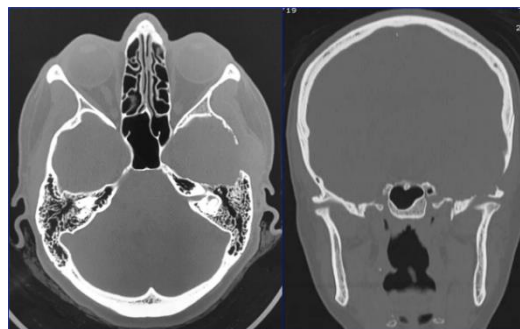


Fig. 9. Brain CT: Axial view and coronal reformat, with bone reconstruction algorithm, showing bone involvement.

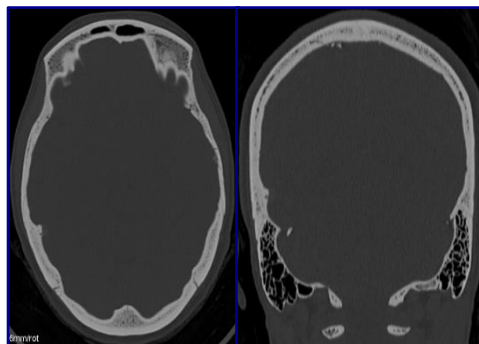


Fig. 10. Brain CT: An axial view and coronal reformat of CT, with a bone reconstruction algorithm, show the left temporal bone hyperostosis.

Differential diagnosis

The most common diagnosis of a dural mass is meningioma; possible alternative diagnoses (so-called “meningioma mimics”) include SFT, glioblastoma, lymphoma, dural metastases (e.g., breast cancer), as well as other less common lesions (1).

Compared to all grades/subtypes of meningioma, SFT is associated with a higher apparent diffusion coefficient, narrow-based dural attachments, less peritumoral brain edema, extensive serpentine flow voids, and younger age at initial diagnosis. Tumor volume has limited utility in differentiating between SFT and various grades/subtypes of meningioma (9).

Treatment

The patient was submitted to neurosurgical treatment with complete removal of the tumor. The lesion was largely subdural with focal extradural extension involving the middle cranial fossa, the left temporal bone, and the left temporal muscle. Histological examination and immunohistochemistry revealed a pattern of solitary fibrous tumor STAT6+. Subsequently, the patient underwent total body CT and PET, both of which excluded the presence of other tumor localizations. Then, she was submitted to radiation treatment, 27 sessions in 6 weeks, for a total dose of 54.0 Gy.

Outcome and follow-up

The patient recovered after surgical resection without sequelae, except for seizures in complete remission, for which the patient was submitted to prophylactic medical treatment. A control brain MRI and a total body CT carried out about 40 days after the end of RT excluded the presence of local recurrence or distant metastases; the minor contralateral lesion was unchanged. The planned follow-up involves the execution of two brain MRIs and two total body CTs every year for the first 3 years. Two years after the first surgery, a control brain MRI showed the presence of disease recurrence at the level of surgical outcomes (Fig. 11).

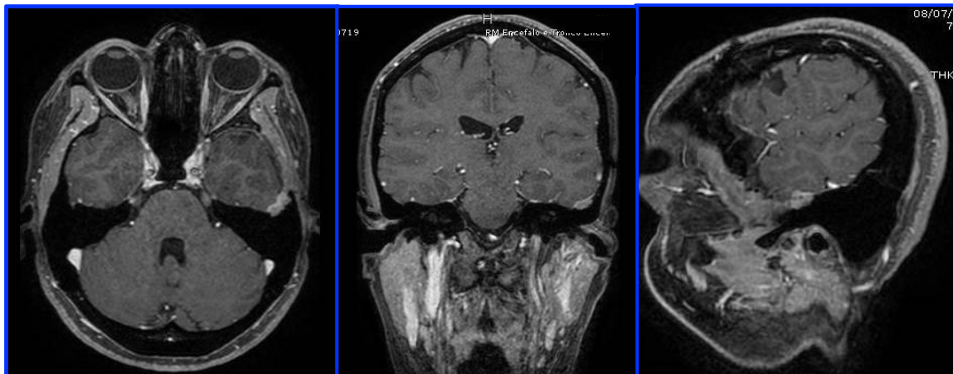


Fig. 11. Brain MRI: Axial view, coronal and sagittal reformat of post-contrast T1 VIBE sequence, showing the high enhancement of the pathological tissue at the level of surgical outcomes.

Therefore, the patient underwent a second surgical treatment. One year later, a control brain CT suggested the presence of a disease recurrence, which was confirmed by subsequent MR images (Fig. 12-14).

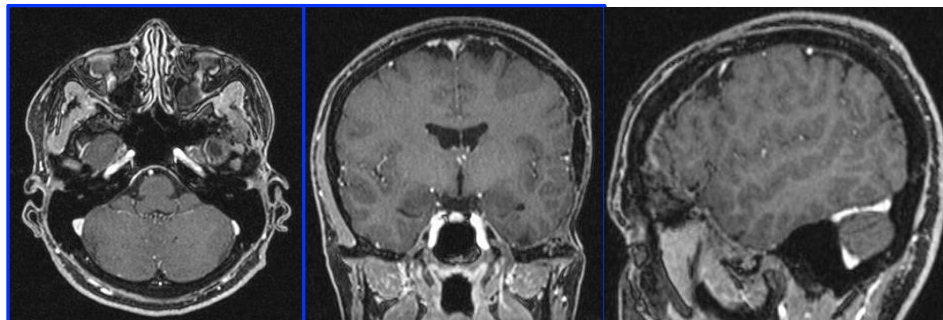


Fig.12. Brain MRI: Axial view, coronal and sagittal reformat of post-contrast T1 VIBE sequence, showing the high enhancement of the pathological tissue of the second recurrence of disease at the level of surgical outcomes.

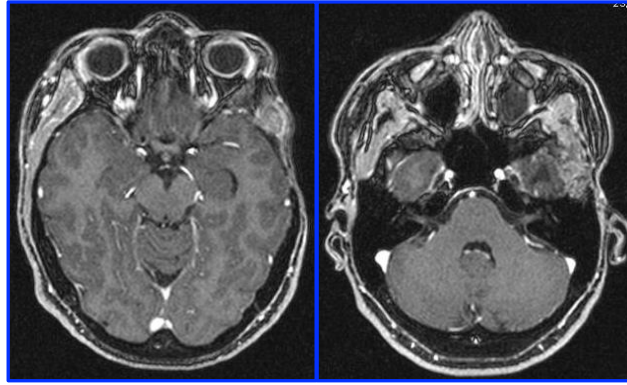


Fig.13. Brain MRI: Axial view of post-contrast T1 VIBE sequence, showing the high enhancement of the pathological tissue of the second recurrence of disease 3 months after its identification; the images show how the tissue develops in a more cranial and a more caudal component that is continuous with each other.

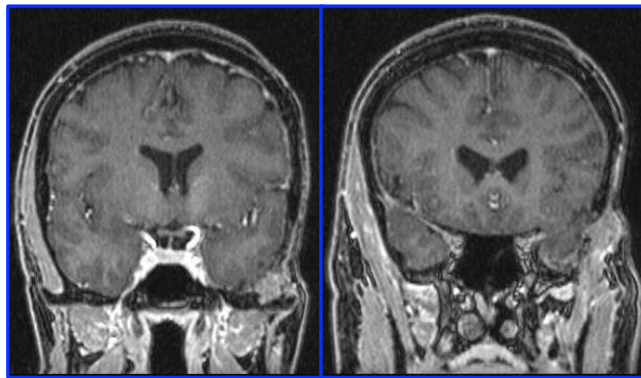


Fig. 14. Brain MRI: Coronal reformat of post-contrast T1 VIBE sequence, showing the high enhancement of the pathological tissue of the second recurrence of disease 3 months after its identification; the images show how the tissue develops in a more cranial component and a more caudal one, that is continuous with each other.

Because of this, the patient was submitted to new radiation treatment (Hadrontherapy treatment), and then she started chemotherapy, which is still ongoing; until now, the disease appears to be under control.

DISCUSSION

Solitary fibrous tumor of the CNS is a relatively rare neoplasm with a prognosis variable according to the histological grade identified using the WHO classification system (10). This neoplasm usually occurs in middle-aged adults and is equally common in men and women. The most frequent presentation symptoms are headache, dizziness, and unstable gait.

At imaging, it usually appears as a solitary mass of variable dimensions, even considerable (up to 70 mm according to some cases), well-defined, often round, and originating from meninges or tentorium (11, 12). Most CT and MRI features are similar to those typically associated with meningiomas. On pre-contrast CT scans, the attenuation of the lesions shows predominantly hyperattenuation; usually, the lesion does not contain calcifications. The signal intensity on MR images is generally isointense on T1-weighted images and isointense to hypointense on T2-weighted images, a feature that correlates with the histologic finding of the fibrous stroma. An intense contrast enhancement, homogeneous or heterogeneous, is usually present at CT and MRI after contrast injection, sometimes with evidence of marked peritumoral edema. The intense enhancement has been attributed to the high vascularization due to the prominent vascular channels in the neoplasm.

According to some authors (13), the sign of the dural tail, which is highly suggestive but not specific to the meningioma, is also present in SFT and missing, according to other authors (12). Unlike meningiomas, the classic bone thickening adjacent to the lesion is often not present (14). In SFT, the dural attachments are usually narrow-based (9).

Our case is particularly rare because two different lesions coexist. One is a histologically confirmed STF, and the other has MRI and CT features of meningioma. This case exemplifies the different imaging characteristics of the two

types of lesions well.

cSFT is a rare and aggressive type of tumor. Tumor resection is the first choice for treatment. The log-rank test results showed that the patients who underwent total resection had better overall survival (OS). The effect of radiation therapy after surgery was not significant; it does not improve OS (15). Intracranial SFT exhibits aggressive biological behavior with a 5-year recurrence rate close to 50% after surgical resection (9).

In conclusion, although relatively rare, SFT should be included in the radiological differential diagnosis of tumors arising from the meninges.

REFERENCES

1. Lyndon D, Lansley JA, Evanson J, Krishnan AS. Dural masses: meningiomas and their mimics. *Insights Imaging*. 2019;10(1):11. doi:<https://doi.org/10.1186/s13244-019-0697-7>
2. Davanzo B, Emerson RE, Lisy M, Koniaris LG, Kays JK. Solitary fibrous tumor. *Transl Gastroenterol Hepatol*. 2018;3(94). doi:<https://doi.org/10.21037/tgh.2018.11.02>
3. Dervan PA, Tobin B, O'Connor M. Solitary (localized) fibrous mesothelioma: evidence against mesothelial cell origin. *Histopathology*. 1986;10(8):867-875. doi:<https://doi.org/10.1111/j.1365-2559.1986.tb02584.x>
4. Fukunaga M, Naganuma H, Nikaido T, Harada T, Ushigome S. Extrapleural solitary fibrous tumor: a report of seven cases. *Mod Pathol*. 1997;10(5):443-450.
5. Carneiro SS, Scheithauer BW, Nascimento AG, Hirose T, Davis DH. Solitary fibrous tumor of the meninges: a lesion distinct from fibrous meningioma. A clinicopathologic and immunohistochemical study. *Am J Clin Pathol*. 1996;106(2):217-224. doi:<https://doi.org/10.1093/ajcp/106.2.217>
6. Fritchie KJ, Jin L, Rubin BP, et al. NAB2-STAT6 Gene Fusion in Meningeal Hemangiopericytoma and Solitary Fibrous Tumor. *J Neuropathol Exp Neurol*. 2016;75(3):263-271. doi:<https://doi.org/10.1093/jnen/nlv026>
7. Louis DN, Perry A, Reifenberger G, et al. The 2016 World Health Organization Classification of Tumors of the Central Nervous System: a summary. *Acta Neuropathol*. 2016;131(6):803-820. doi:<https://doi.org/10.1007/s00401-016-1545-1>
8. Doyle LA, Vivero M, Fletcher CD, Mertens F, Hornick JL. Nuclear expression of STAT6 distinguishes solitary fibrous tumor from histologic mimics. *Mod Pathol*. 2014;27(3):390-395. doi:<https://doi.org/10.1038/modpathol.2013.164>
9. El-Abtah ME, Murayi R, Lee J, Recinos PF, Kshetry VR. Radiological Differentiation Between Intracranial Meningioma and Solitary Fibrous Tumor/Hemangiopericytoma: A Systematic Literature Review. *World Neurosurg*. 2023;170(68-83). doi:<https://doi.org/10.1016/j.wneu.2022.11.062>
10. Sung KS, Moon JH, Kim EH, et al. Solitary fibrous tumor/hemangiopericytoma: treatment results based on the 2016 WHO classification. *J Neurosurg*. 2018;1-8. doi:<https://doi.org/10.3171/2017.9.JNS171057>
11. Wang YH, Huang YL. Is Aspiration Prior to Filler Injection Beneficial in Preventing Inadvertent Vascular Adverse Events? *Aesthet Surg J*. 2022;42(6):NP434-NP436. doi:<https://doi.org/10.1093/asj/sjab404>
12. Ma L, Wang L, Fang X, Zhao CH, Sun L. Diagnosis and treatment of solitary fibrous tumor/hemangiopericytoma of central nervous system. Retrospective report of 17 patients and literature review. *Neuro Endocrinol Lett*. 2018;39(2):88-94.
13. Martin AJ, Fisher C, Igbaseimokumo U, Jarosz JM, Dean AF. Solitary fibrous tumours of the meninges: case series and literature review. *J Neurooncol*. 2001;54(1):57-69. doi:<https://doi.org/10.1023/a:1012553119349>
14. Clarencon F, Bonneville F, Rousseau A, et al. Intracranial solitary fibrous tumor: imaging findings. *Eur J Radiol*. 2011;80(2):387-394. doi:<https://doi.org/10.1016/j.ejrad.2010.02.016>
15. Lu T, Xu H, Dong X, Jin Z, Wang Y. Epidemiology and survival of patients with central nervous system solitary fibrous tumors: A population-based analysis. *Front Oncol*. 2022;12(977629). doi:<https://doi.org/10.3389/fonc.2022.977629>



Review

THE ROLE OF PERI-IMPLANT CREVICULAR FLUID IN THE DIAGNOSIS AND TREATMENT OF ORAL PERI-IMPLANTITIS: A SCOPING REVIEW

A. Falco¹, S.A. Gehrke^{2,3}, A. Scarano⁴ and S.R. Tari⁴

¹Falmed Medical Care, Viale G. d'Annunzio, Pescara, Italy;

²Department of Research, Bioface/PgO/UCAM, Montevideo, Uruguay;

³Department of Biotechnology. Universidad Católica de Murcia (UCAM), Murcia, Spain;

⁴Faculty of Oral Surgery, Department of Innovative Technologies in Medicine and Dentistry, University of Chieti-Pescara, Chieti, Italy

Correspondence to:

Prof. Antonio Scarano, D.D.S., M.D.

Department of Innovative Technology in Medicine and Dentistry,

University of Chieti-Pescara,

Via Dei Vestini 31,

66100 Chieti, Italy

e-mail: ascarano@unich.it

ABSTRACT

Peri-implantitis is a major inflammation involving soft and hard peri-implant tissues, resulting in implant loss that is currently considered an evolution of mucositis. At present, implant-supported prosthesis is readily accepted as a reliable treatment option for the rehabilitation of both partially as well as fully edentulous patients. A diagnosis of peri-implantitis can be made only by assessing the Gingival Index, the bleeding on probing, the probing depth, and an examination of the radiographic bone resorption. We can find in the literature studies that have suggested the possibility of diagnosing the beginning of peri-implantitis or of examining this pathological condition using inflammatory markers. This review aims to analyze which and how many inflammatory mediating factors are involved in the peri-implantitis destructive process and the possibility of using these same factors to diagnose, control, and eventually for the therapy of peri-implantitis. From a deep analysis of the literature, it is possible to observe how we are near the achievement of these objectives. Still, further studies are necessary to determine which markers and with what mechanisms these markers of inflammation can be utilized to treat the destructive process of both the soft and hard tissues involved in peri-implantitis. Therefore, it is not yet possible to give birth to a new protocol on peri-implantitis based on inflammatory markers, and future studies are necessary to establish the diagnostic accuracy and clinical relevance of these biomarkers.

KEYWORDS: *peri-implant crevicular fluid (PICF), dental implant, peri-implantitis, inflammatory markers.*

INTRODUCTION

Peri-implantitis (PI) is a major inflammation that involves soft tissues and hard peri-implant tissues, resulting in implant loss. It is currently considered an evolution of mucositis (MI). Recently, the consensus report of the 4th workgroup of the 2017 World Workshop has been divided into three categories based on the classification of periodontal and PI

Received: 29 April 2024
Accepted: 03 June 2024

ISSN 2038-4106 print

ISSN 2975-044X online

Copyright © by BIOLIFE 2024

This publication and/or article is for individual use only and may not be further reproduced without written permission from the copyright holder. Unauthorized reproduction may result in financial and other penalties. Disclosure: All authors report no conflicts of interest relevant to this article.

diseases and conditions. These are peri-implant health, peri-implant mucositis (PIM), and PI (1). The more common complication with implants can be attributed to the loss of components, marginal bone loss (MBL), MI, peri-implantitis, and lack and loss of osseointegration (2). No adverse immunological reactions against CP-Ti implants have been yet reported. Metal sensitivity is due to a cell-mediated immune response with metal ions acting as haptens (3).

Another possible origin of implant failure is implanted surface contaminants, which may be released from the surface, eliciting an inflammatory response (4). It has been demonstrated both *in vitro* and *in vivo* that particulate debris can activate macrophages, which produce factors mediating bone resorption (5). Other experimental studies have also shown that particles can be transported by phagocytes to regional lymph nodes (6) and parenchymal organs (7). Based on available data, it seems very unlikely that metal particles released at the implant interface play a predominant role in the failures of oral implants, as there is little evidence to support any toxic effect due to wear particles or metal ion release. The etiology of MBL has been attributed mainly to two factors: mechanical (or load factors) and biological (or plaque-induced lesions) (8, 9). Most failures, 60%, occurred during the first year after the placement. In most cases, no prosthetic restoration has been placed on the implants. Untreated bacterial infection can lead to inflammatory peri-implant disease processes, reversible soft tissue inflammatory conditions surrounding the implant (MI), or an advanced and irreversible stage called PI. This pathology is defined as an inflammatory process affecting the tissues around a functional osseointegrated implant, resulting in the loss of supporting bone (10). The diagnosis of PI is usually established by assessing probing depth, gingival index (GI), bleeding on probing (BOP), and radiographic bone resorption examinations. However, interpreting these signs and symptoms is often subjective, and their calibration for general clinical needs can be problematic. Although the clinical periodontal parameters have been widely used to monitor the conditions affecting the peri-implant tissue, a general agreement on their significance is, at least partially, still unclear, as these clinical diagnostic indices have been developed to diagnose and measure the course of periodontitis. Radiographic examinations mainly reflect the past pattern of bone loss and do not always reveal the current disease status and phase of the actual disease activity. Furthermore, the detectable radiographic bone loss reflects the peri-implantitis site already in the advanced and irreversible stage (11). The aim of this paper is to summarize the currently available articles on biomarkers and periimplantitis through a scoping review.

INFLAMMATORY MARKERS

Gingival crevicular fluid (GCF), a serum-like fluid exudates from capillaries of the gingival sulcus or periodontal pocket, has been regarded as a promising medium for the detection of periodontal disease activity (12). Several inflammatory cytokines (13) and proteases and/or protease inhibitors (14) have been investigated (Fig. 1).

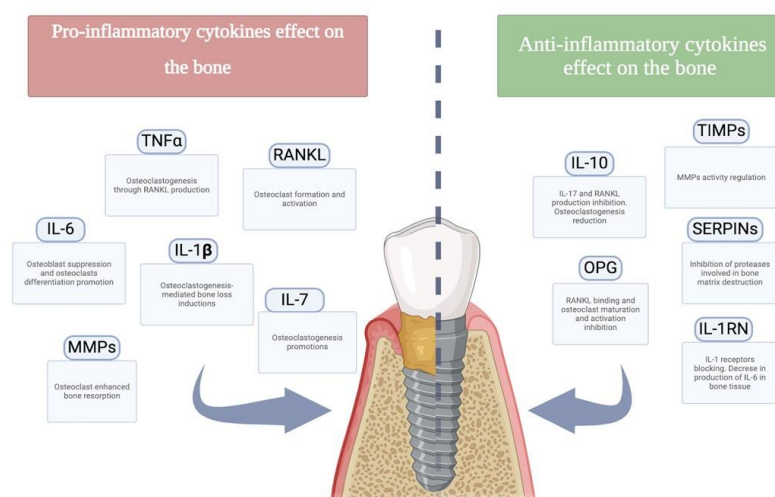


Fig. 1. Peri-implant anti-inflammatory and proinflammatory cytokine on preimplant tissues. Image realized by BioRender software.

On the other hand, several studies have also been carried out on inflammatory markers and growth factors in peri-implant crevicular fluid (PICF). It was reported that at sites where implants were removed due to peri-implantitis, ‘an inflammatory infiltrate, composed of macrophages, lymphocytes, and plasma cells, was found in the connective tissue around the implants’. The characteristics of the PICF flow and microbiota appear similar to those in periodontal tissues.

Epithelial cells attached to the implant surface are similar to those found on the natural tooth surface and produce non-keratinized sulcular epithelium overlapping of the junctional epithelium (15). Porcine epithelial cells have been shown to attach themselves to titanium film by basement membrane (BM) and hemidesmosomes (HD) *in vitro*. These structures are rich in laminin-5 and type IV collagen. Laminin-5 (LN-5) (known as kalinin/nicein/epiligrin) has a size of 400–440kDa, and it is a multifunctional glycoprotein that acts as a motility signal and adhesive component for epithelial cells, both in physiological (16) and pathological processes. Furthermore, the LN-5g2-chain is expressed in various cancers along their invasive edge (17) as well as co-localizing together with matrix metalloproteinases (MMPs) to the basement membrane region underlying the periodontitis-affected gingival sulcular epithelium (18).

Marjo J. Kivelä-Rajamäki et al. (19) used Western immunoblotting with image analysis to quantify the molecular forms of LN-5 g2-chain and MMP-8 in peri-implant sulcular fluid (PISF) from healthy and diseased implants (20). These observations were regarded as the recorded gingival (GI) and bone resorption (BR) indices of the studied sites. 72 PISF samples from osseointegrated dental implants were examined, and significantly elevated levels of fragmented LN-5 g2-chain species (45 and 70 kDa) and MMP-8 immunoreactivities were observed in diseased PISF in relation to healthy PISF. These cross-sectional findings indicated that elevated MMP-8 and LN-5 g2-chain fragment levels in PISF can reflect the active phase of the inflammatory peri-implant disease. Further, longitudinal studies are required to assess their use, either alone or in combination with molecular, biochemical PISF markers, to predict the risk of progression of peri-implantitis and to monitor the impact of treatment of the disease (21). Almost all extracellular matrix (ECM) and basement membrane (BM) protein components can be degraded by MMPs acting alone or in a collective manner.

MMPs form a family of neutral endoproteinases with over 20 known members (MMP-1 to MMP-28). Their common denominator is the ability to function at the neutral body pH; under these conditions, they can degrade all extracellular matrix components. The expression and activity of MMPs in normal tissues are quite low but increase significantly in various pathological conditions that may lead to unwanted tissue destruction, such as in inflammatory diseases, tumor growth, and metastasis. MMPs also seem to have a marked role in tissue destruction in oral diseases (22). MMPs are normally involved in physiological processes such as tissue development, remodeling, and wound healing and also play an important role in the regulation of cellular communication, molecular shedding, and immune functions by processing bioactive molecules, including cell surface receptors, cytokines, hormones, defensins, adhesion molecules and growth factors (22).

In dentistry, they are best known for their ability to cut across the interstitial collagen triple helix of type I and III collagen, which are the main components of the periodontal ligament. Still, evidence has been brought forward to indicate that MMPs may also be involved in other oral diseases, such as dental caries and oral cancer. More recent studies suggest that *in vivo*, the proforms of at least certain MMPs may be active in full-size or complex with certain proteins. MMP activation *in vivo* likely involves tissue and plasma proteinases and bacterial proteinases together with oxidative stress. Secreted MMPs are usually activated extracellularly or at the cell surface, the best-known example of cell surface activation being the activation of MMP-2 in an MMP-2/TIMP-2/MT1-MMP complex.

Several MMPs may also be activated intracellularly by furin or related proprotein convertases (23, 24). The increased synthesis of MMPs in inflamed gingiva has also been seen at the mRNA level. The main collagenases responsible for collagen degradation in gingival tissues are MMP-1 (fibroblast-type collagenase) and MMP-8 (neutrophil-type collagenase). The current literature has shown that the major collagenase in gingival crevicular fluid (GCF) from adult periodontitis patients is MMP-8, while MMP-1 is predominant in GCF in juvenile periodontitis patients.

Currently, four TIMPs (TIMP 1–4) are known to be expressed in vertebrates. TIMPs inhibit MMPs by forming 1:1 stoichiometric enzyme-inhibitor complexes. TIMP-1, -2, and -4 are secreted, while TIMP-3 is sequestered to the ECM. Synthetic inhibition of MMPs offers an interesting possibility to control MMP-related diseases involving extensive tissue destruction (25). One approach in MMP inhibition is aimed at the chelation of the enzyme's active site, Zn²⁺ ion. The first MMP inhibitors to enter clinical trials in tumor treatment, based on their MMP inhibitory effect on chelation. Tetracyclines and their non-antimicrobial analogs (chemically modified tetracyclines, CMTs) inhibit MMPs by several mechanisms. In addition to Zn²⁺ chelation, they can down-regulate MMP mRNA expression, interfere with protein processing during activation, and render the MMPs more susceptible to degradation (26). Some studies on MMPs in PICF have reported that collagenase activity and MMP-8 levels were significantly higher in diseased PICF than in healthy ones (27). A strong inverse relationship was found between the collagenase activity and collagenase inhibitor (28). As the roles of MMPs in tissue degenerative diseases have become more evident, attempts to control their activities by pharmacological means have gained much attention. Although the exact roles of individual MMPs in various diseases are not fully understood, it is clear that MMPs are often up-regulated in groups, forming activation cascades in inflammatory and malignant diseases.

Many enzymes present in GCF and PISF originate from the azurophilic granules of polymorphonuclear leukocytes (PMNs). Various authors have shown increased PMN-specific enzyme myeloperoxidase (MPO) activity at

periodontitis sites and decreased activity following treatment (29). MPO is generally believed to kill by oxidizing Cl_2 into hypochlorous acid, HOCl (30). Hypochlorous acid is highly reactive and can easily oxidize many biological molecules. HOCl can also induce peptide bond scission and the formation of low molecular weight chloramines with bactericidal potential. A cross-sectional study evaluated the correlation of myeloperoxidase (MPO) levels with traditional periodontal clinical parameters around dental implants, including peri-implant pocket probing depth, GI, and BOP (11).

These authors showed that the total amounts of MPO were significantly higher in PISF collected around implants with inflammatory lesions. The levels of MPO were then correlated with the clinical parameters, and a similarity of the inflammatory response of tissues surrounding both implants and natural teeth was found. They suggested that MPO could be a promising marker of inflammation. Two enzymes, elastase and alkaline phosphatase, as well as the inhibitor α_2 -macroglobulin, were shown to be associated with tissue destruction in periodontitis (31). Increased PICF elastase activity has been seen in the periodontitis sites, and it has been suggested that elastase activity could predict the progression of the disease.

Alkaline phosphatase, an enzyme involved in bone metabolism, is significantly higher in active sites than in inactive sites (32). It has been suggested that it could predict current and/or future disease activity (33). It has been reported that, compared to the clinically healthy implants, total amounts of each of these 3 substances were significantly higher in PICF collected around implants with periimplantitis, suggesting that ALP and EA could be promising markers of bone loss around dental implants. In addition, markers of bone metabolism, such as osteocalcin (a 5.4-kDa calcium-binding protein of bone), have been studied. It is the most abundant noncollagenous protein of the mineralized bone tissue (34).

The serum level of this protein is considered to be a marker of bone formation. Although several investigations on osteocalcin levels in GCF from patients with periodontitis have been carried out, the role of osteocalcin in periodontal disease progression is still unclear. Murata et al. analyzed the levels of osteocalcin, deoxypyridinoline (Dpd), and interleukin-1b as markers of bone metabolism in PICF in peri-implantitis patients, and PICF was sampled from a total of 34 endosseous titanium implants (35). They observed that osteocalcin levels in PICF from MI sites were significantly higher than in healthy implants ($P < 0.05$). In contrast, peri-implantitis sites were not significantly different from either MI or healthy implant sites. IL-1b levels in PICF from peri-implantitis sites were significantly higher than levels from PIM ($P < 0.05$) and healthy implant sites ($P < 0.01$). The authors found that osteocalcin in PICF may reflect increased local bone turnover around implants. Furthermore, IL-1b should be a valuable marker for peri-implant inflammation.

More recent evidence suggests that gelatinase B is involved in bone remodeling, which is mediated by bone morphogenetic units, which, after initiation, undergo sequential phases known as activation, resorption/reversal, and formation (the so-called ARF cycle). Although MMPs, particularly MMP-9, have long been implicated in bone destruction, the exact phase of their involvement is not well understood. Gelatinase B is involved in the recruitment of osteoclasts that go to the resorption sites. Gelatinase B, but not gelatinase A, is expressed by rabbit and human osteoclasts, the number of which is increased in periodontitis. Gelatinase B also seems to play a role in jaw cyst expansion (36). Polymorphonuclear leukocytes, keratinocytes, and macrophages contain gelatinase B. Osteoclasts also represent an important source of gelatinase B in periodontal tissues.

Research conducted by Ma et al. studied whether gelatinase B was associated with peri-implant bone loss (37). Peri-implant sulcus fluid was collected from 46 implant sites in 12 patients. The sites were also characterized by a modified GI. They saw that gelatinase B is associated with PBL and that activation of gelatinase B and elevated mGI eventually reflects active phases of peri-implantitis and may, in some cases, be diagnostically useful. An enzyme generally confined to the cytoplasm of cells but released in the extracellular environment upon cell death is aspartate aminotransferase (38). They showed that a significant difference in aspartate aminotransferase (AST) activity existed between healthy implants and implants affected by peri-implantitis (PI) and between implants with MI and PI. However, no statistically significant difference was found between HI/MI AST activity; the AST activity was significantly associated with probing depth, bone loss, and bleeding upon probing. In addition, Fiorellini et al. demonstrated in a cross-sectional study a statistical correlation between diseased clinical periodontal parameters and elevated AST levels (39). Other authors analyzed AST in PCF of implants exhibiting peri-implantitis and evaluated the association between AST levels and levels and progressive attachment loss. Their results indicated that, in contrast to periodontal disease, the assessment of AST in the PICF may be of limited value as a diagnostic and prognostic marker for peri-implant disease (40). It is well known that prostaglandin E2 has a pro-inflammatory effect on peri-implant tissues, including mediation of bone resorption. Alrowis et al., in their pilot study, assessed prostaglandin E2 levels in implant crevicular fluid and the possibility of using this method in diagnosing PIM (41).

It was seen that in the control group (with probing depths less than 3 mm), there was no statistically significant positive correlation between clinical parameters and PICF prostaglandin E2 levels ($P > 0.05$), while in the test group, GI and probing depths were found to be statistically significantly related with PICF prostaglandin E2 levels ($P < 0.05$). In a

study by Aboyoussef et al., they evaluated possible mechanisms of bone loss in peri-implantitis by examining PICF samples for the presence of prostaglandin E2 and proteolytic enzymes, specifically MMPs (42). The results indicated that levels of prostaglandin E2 in healthy sites were not significantly different from those at diseased sites. MMP species migrated at 92 kd and 66 kd, and no qualitative difference in bands was seen between healthy implants and those diagnosed as early peri-implantitis.

Interleukin 1 is believed to play a key role in inflammation and immunologic reactions. The interleukin-1 gene cluster has been mapped to the long arm of chromosome 2 and consists of three genes: interleukin-1A, interleukin-1B, and interleukin-1RN, encoding interleukin-1a, interleukin-1b, and interleukin-1ra, respectively. Interleukin-1a and interleukin-1b have several pro-inflammatory activities, causing strong stimulatory effects on bone resorption and inhibitory effects on bone formation (43). A pilot study was conducted to determine levels of inflammatory cytokines in crevicular fluid from healthy implants and those affected by peri-implantitis (44). Implants were categorized clinically as healthy, early peri-implantitis, or advanced peri-implantitis. Results indicated that interleukin-1 beta is present in implant gingival crevicular fluid and may be modulating attachment loss in implants suffering from peri-implantitis. Thus, interleukin-1 beta may be used to monitor disease progression.

Other studies confirmed that the crevicular fluid levels of this inflammatory cytokine, interleukin-1 beta (IL-1 beta), can be used as an objective measure of peri-implant health and to evaluate the effectiveness of treatment of patients with failing implants. Boris Gruica et al. assessed the impact of the IL-1 genotype and smoking status on the prognosis and development of complications of osseointegrated implants. They showed that there is a synergistic effect between a positive IL-1 genotype and smoking that puts dental implants at a higher risk of developing biological complications during function. In addition, IL-6, another cytokine with the potential to regulate osteoclasts, is increased in both peri-implantitis and CP (chronic periodontitis) (45). Tumor necrosis factor- α (TNF- α), a cytokine with functions similar to IL-1b, has also been detected in very low levels in sites with periodontitis. These cytokines stimulate bone resorption, prostaglandin synthesis, and protease production by many cell types, including fibroblasts and osteoblasts (46).

To our knowledge, Ataoglu is the first study demonstrating the presence of TNF- α in PICF of implants (47). In comparison, TNF- α levels in PICF were somewhat lower than IL-1b levels and were not correlated with clinical parameters. Based on the findings of this study, it remains to be proven whether the TNF- α level in PICF has a value as a measure of peri-implant health status. A member of the Tumor necrosis factor superfamily is the receptor activator of NF-KappaB ligand (RANKL); it's a key mediator of osteoclast formation, activation, and survival. In a pilot study, Djinic Krasavcevic et al. hypothesized that there was a functional relationship between RANKL expression and peri-implantitis (48).

CONCLUSIONS

One of the more common complications of implant prosthetic rehabilitation therapy is peri-implantitis. Various authors have studied the phenomena that destroy the peri-implant tissues, especially bone tissue. These studies indicate a possible link between the active phases of peri-implantitis and elevated levels of the inflammatory markers. This implies that it might be possible to utilize the inflammatory markers as an auxiliary early warning diagnostic tool against peri-implantitis and as a control of the effectiveness of the therapies against the inflammatory pathology. Eventually, it may also be possible to develop therapies that have an effect on their inhibitors.

In the near future, it will not yet be possible to utilize very selective drugs that act against specific strains of bacteria and, at the same time, inhibit the activity of all factors involved in peri-implantitis inflammation. Numerous new studies will have to be conducted under rigorous control conditions to understand which markers of the inflammation process are involved in determining peri-implantitis. The future treatment of peri-implantitis lies in the utilization of the markers for early diagnosis and the development of specific drugs capable of selectively inhibiting the effects of inflammatory markers.

REFERENCES

1. Berglundh T, Armitage G, Araujo MG, et al. Peri-implant diseases and conditions: Consensus report of workgroup 4 of the 2017 World Workshop on the Classification of Periodontal and Peri-Implant Diseases and Conditions. *J Clin Periodontol.* 2018;45 Suppl 20(S286-S291). doi:<https://doi.org/10.1111/jcpe.12957>
2. Bullon P, Fioroni M, Goteri G, Rubini C, Battino M. Immunohistochemical analysis of soft tissues in implants with healthy and peri-implantitis condition, and aggressive periodontitis. *Clin Oral Implants Res.* 2004;15(5):553-559. doi:<https://doi.org/10.1111/j.1600-0501.2004.01072.x>
3. Merritt K, Brown SA. Metal sensitivity reactions to orthopedic implants. *Int J Dermatol.* 1981;20(2):89-94. doi:<https://doi.org/10.1111/j.1365-4362.1981.tb00408.x>

4. Scarano A, Piattelli A, Polimeni A, Di Iorio D, Carinci F. Bacterial adhesion on commercially pure titanium and anatase-coated titanium healing screws: an *in vivo* human study. *J Periodontol*. 2010;81(10):1466-1471. doi:<https://doi.org/10.1902/jop.2010.100061>
5. Noubissi S, Scarano A, Gupta S. A Literature Review Study on Atomic Ions Dissolution of Titanium and Its Alloys in Implant Dentistry. *Materials (Basel)*. 2019;12(3):doi:<https://doi.org/10.3390/ma12030368>
6. Weingart D, Steinemann S, Schilli W, et al. Titanium deposition in regional lymph nodes after insertion of titanium screw implants in the maxillofacial region. *Int J Oral Maxillofac Surg*. 1994;23(6 Pt 2):450-452. doi:[https://doi.org/10.1016/s0901-5027\(05\)80045-1](https://doi.org/10.1016/s0901-5027(05)80045-1)
7. Schliephake H, Reiss G, Urban R, Neukam FW, Guckel S. Metal release from titanium fixtures during placement in the mandible: an experimental study. *Int J Oral Maxillofac Implants*. 1993;8(5):502-511.
8. De Smet E, van Steenberghe D, Quirynen M, Naert I. The influence of plaque and/or excessive loading on marginal soft and hard tissue reactions around Branemark implants: a review of literature and experience. *Int J Periodontics Restorative Dent*. 2001;21(4):381-393.
9. Scarano A, Assenza B, Piattelli M, et al. Interimplant distance and crestal bone resorption: a histologic study in the canine mandible. *Clin Implant Dent Relat Res*. 2004;6(3):150-156. doi:<https://doi.org/10.1111/j.1708-8208.2004.tb00222.x>
10. Albrektsson T. Consensus report of session IV. In: *Proceedings of the First European Workshop on Periodontology*: Quintessence Publishing; 1994. pp. 365-369.
11. Herrera D, Berglundh T, Schwarz F, et al. Prevention and treatment of peri-implant diseases-The EFP S3 level clinical practice guideline. *J Clin Periodontol*. 2023;50 Suppl 26(4-76). doi:<https://doi.org/10.1111/jcpe.13823>
12. Tsuchida S, Satoh M, Takiwaki M, Nomura F. Current Status of Proteomic Technologies for Discovering and Identifying Gingival Crevicular Fluid Biomarkers for Periodontal Disease. *Int J Mol Sci*. 2018;20(1):doi:<https://doi.org/10.3390/ijms20010086>
13. Cafiero C, Spagnuolo G, Marenzi G, Martuscelli R, Colamaio M, Leuci S. Predictive Periodontitis: The Most Promising Salivary Biomarkers for Early Diagnosis of Periodontitis. *J Clin Med*. 2021;10(7):doi:<https://doi.org/10.3390/jcm10071488>
14. Lumbikananda S, Srithanyarat SS, Mattheos N, Osathanon T. Oral Fluid Biomarkers for Peri-Implantitis: A Scoping Review. *Int Dent J*. 2023;doi:<https://doi.org/10.1016/j.identj.2023.11.005>
15. Fujii N, Kusakari H, Maeda T. A histological study on tissue responses to titanium implantation in rat maxilla: the process of epithelial regeneration and bone reaction. *J Periodontol*. 1998;69(4):485-495. doi:<https://doi.org/10.1902/jop.1998.69.4.485>
16. Mizushima H, Koshikawa N, Moriyama K, et al. Wide distribution of laminin-5 gamma 2 chain in basement membranes of various human tissues. *Horm Res*. 1998;50 Suppl 2(7-14). doi:<https://doi.org/10.1159/000053118>
17. Pyke C, Romer J, Kallunki P, et al. The gamma 2 chain of kalinin/laminin 5 is preferentially expressed in invading malignant cells in human cancers. *Am J Pathol*. 1994;145(4):782-791.
18. Pirila E, Maisi P, Salo T, Koivunen E, Sorsa T. *In vivo* localization of gelatinases (MMP-2 and -9) by in situ zymography with a selective gelatinase inhibitor. *Biochem Biophys Res Commun*. 2001;287(3):766-774. doi:<https://doi.org/10.1006/bbrc.2001.5653>
19. Kivela-Rajamaki MJ, Teronen OP, Maisi P, et al. Laminin-5 gamma2-chain and collagenase-2 (MMP-8) in human peri-implant sulcular fluid. *Clin Oral Implants Res*. 2003;14(2):158-165. doi:<https://doi.org/10.1034/j.1600-0501.2003.140204.x>
20. Scarano A, Khater AGA, Gehrke SA, et al. Current Status of Peri-Implant Diseases: A Clinical Review for Evidence-Based Decision Making. *J Funct Biomater*. 2023;14(4):doi:<https://doi.org/10.3390/jfb14040210>
21. Alassy H, Parachuru P, Wolff L. Peri-Implantitis Diagnosis and Prognosis Using Biomarkers in Peri-Implant Crevicular Fluid: A Narrative Review. *Diagnostics (Basel)*. 2019;9(4):doi:<https://doi.org/10.3390/diagnostics9040214>
22. Sorsa T, Tjaderhane L, Salo T. Matrix metalloproteinases (MMPs) in oral diseases. *Oral Dis*. 2004;10(6):311-318. doi:<https://doi.org/10.1111/j.1601-0825.2004.01038.x>
23. Nagase H. Activation mechanisms of matrix metalloproteinases. *Biol Chem*. 1997;378(3-4):151-160.
24. Pei D, Weiss SJ. Furin-dependent intracellular activation of the human stromelysin-3 zymogen. *Nature*. 1995;375(6528):244-247. doi:<https://doi.org/10.1038/375244a0>
25. Sorsa T, Tjaderhane L, Konttinen YT, et al. Matrix metalloproteinases: contribution to pathogenesis, diagnosis and treatment of periodontal inflammation. *Ann Med*. 2006;38(5):306-321. doi:<https://doi.org/10.1080/07853890600800103>
26. Golub LM, Lee HM, Ryan ME, Giannobile WV, Payne J, Sorsa T. Tetracyclines inhibit connective tissue breakdown by multiple non-antimicrobial mechanisms. *Adv Dent Res*. 1998;12(2):12-26. doi:<https://doi.org/10.1177/08959374980120010501>
27. Teronen O, Konttinen YT, Lindqvist C, et al. Human neutrophil collagenase MMP-8 in peri-implant sulcus fluid and its inhibition by clodronate. *J Dent Res*. 1997;76(9):1529-1537. doi:<https://doi.org/10.1177/00220345970760090401>

28. Chmielewski M, Pilloni A. Current Molecular, Cellular and Genetic Aspects of Peri-Implantitis Disease: A Narrative Review. *Dent J (Basel)*. 2023;11(5):doi:https://doi.org/10.3390/dj11050134
29. Baima G, Iaderosa G, Citterio F, et al. Salivary metabolomics for the diagnosis of periodontal diseases: a systematic review with methodological quality assessment. *Metabolomics*. 2021;17(1):1. doi:https://doi.org/10.1007/s11306-020-01754-3
30. Brandt E, Keskin M, Raisanen IT, et al. Induction of Collagenolytic MMP-8 and -9 Tissue Destruction Cascade in Mouth by Head and Neck Cancer Radiotherapy: A Cohort Study. *Biomedicines*. 2023;12(1):doi:https://doi.org/10.3390/biomedicines12010027
31. Yin L, Li X, Hou J. Macrophages in periodontitis: A dynamic shift between tissue destruction and repair. *Jpn Dent Sci Rev*. 2022;58(336-347). doi:https://doi.org/10.1016/j.jdsr.2022.10.002
32. Piattelli A, Scarano A, Di Alberti L, Piattelli M. Histological and histochemical analyses of acid and alkaline phosphatases around hydroxyapatite-coated implants: a time course study in rabbit. *Biomaterials*. 1997;18(17):1191-1194. doi:https://doi.org/10.1016/s0142-9612(97)00055-0
33. Piattelli A, Piattelli M, Scarano A. Simultaneous demonstration of alkaline and acid phosphatase activity in bone, at bone-implant interfaces and at the epiphyseal growth plate in plastic-embedded undemineralized tissues. *Biomaterials*. 1997;18(7):545-549. doi:https://doi.org/10.1016/s0142-9612(96)00172-x
34. Scarano A, Assenza B, Inchingolo F, Mastrangelo F, Lorusso F. New Implant Design with Midcrestal and Apical Wing Thread for Increased Implant Stability in Single Postextraction Maxillary Implant. *Case Rep Dent*. 2019;2019(9529248). doi:https://doi.org/10.1155/2019/9529248
35. Murata M, Tatsumi J, Kato Y, et al. Osteocalcin, deoxypyridinoline and interleukin-1beta in peri-implant crevicular fluid of patients with peri-implantitis. *Clin Oral Implants Res*. 2002;13(6):637-643. doi:https://doi.org/10.1034/j.1600-0501.2002.130610.x
36. Teronen O, Salo T, Kontinen YT, et al. Identification and characterization of gelatinases/type IV collagenases in jaw cysts. *J Oral Pathol Med*. 1995;24(2):78-84. doi:https://doi.org/10.1111/j.1600-0714.1995.tb01143.x
37. Ma J, Kittu U, Hanemaaijer R, et al. Gelatinase B is associated with peri-implant bone loss. *Clin Oral Implants Res*. 2003;14(6):709-713. doi:https://doi.org/10.1046/j.0905-7161.2003.00951.x
38. Paknejad M, Emtiaz S, Khoobyari MM, Gharb MT, Yazdi MT. Analysis of aspartate aminotransferase and alkaline phosphatase in crevicular fluid from implants with and without peri-implantitis. *Implant Dent*. 2006;15(1):62-69. doi:https://doi.org/10.1097/01.id.0000202416.23259.35
39. Fiorellini JP, Nevins ML, Sekler J, Chung A, Oringer RJ. Correlation of peri-implant health and aspartate aminotransferase levels: a cross-sectional clinical study. *Int J Oral Maxillofac Implants*. 2000;15(4):500-504.
40. Ruhling A, Jepsen S, Kocher T, Plagmann HC. Longitudinal evaluation of aspartate aminotransferase in the crevicular fluid of implants with bone loss and signs of progressive disease. *Int J Oral Maxillofac Implants*. 1999;14(3):428-435.
41. AlRowis R, AlMoharib HS, AlMubarak A, Bhaskardoss J, Preethanath RS, Anil S. Oral fluid-based biomarkers in periodontal disease - part 2. Gingival crevicular fluid. *J Int Oral Health*. 2014;6(5):126-135.
42. Aboyousssef H, Carter C, Jandinski JJ, Panagakos FS. Detection of prostaglandin E2 and matrix metalloproteinases in implant crevicular fluid. *Int J Oral Maxillofac Implants*. 1998;13(5):689-696.
43. Tatakis DN. Interleukin-1 and bone metabolism: a review. *J Periodontol*. 1993;64(5 Suppl):416-431.
44. Panagakos FS, Aboyousssef H, Dondero R, Jandinski JJ. Detection and measurement of inflammatory cytokines in implant crevicular fluid: a pilot study. *Int J Oral Maxillofac Implants*. 1996;11(6):794-799.
45. Gruica B, Wang HY, Lang NP, Buser D. Impact of IL-1 genotype and smoking status on the prognosis of osseointegrated implants. *Clin Oral Implants Res*. 2004;15(4):393-400. doi:https://doi.org/10.1111/j.1600-0501.2004.01026.x
46. AlMoharib HS, AlRowis R, AlMubarak A, Waleed Almadhoon H, Ashri N. The relationship between matrix metalloproteinases-8 and peri-implantitis: A systematic review and meta-analysis. *Saudi Dent J*. 2023;35(4):283-293. doi:https://doi.org/10.1016/j.sdentj.2023.03.012
47. Ataoglu H, Alptekin NO, Haliloglu S, et al. Interleukin-1beta, tumor necrosis factor-alpha levels and neutrophil elastase activity in peri-implant crevicular fluid. *Clin Oral Implants Res*. 2002;13(5):470-476. doi:https://doi.org/10.1034/j.1600-0501.2002.130505.x
48. Djinic Krasavcevic A, Nikolic N, Milinkovic I, et al. Notch signalling cascade and proinflammatory mediators in peri-implant lesions with different RANKL/OPG ratios-An observational study. *J Periodontol Res*. 2023;58(2):360-368. doi:https://doi.org/10.1111/jre.13096



Review

DENTAL ISSUES FOLLOWING THE PLACEMENT OF ORTHODONTIC MINI-SCREWS

A. Laforgia^{1†}, G. Dipalma^{1†}, A.D. Inchingolo¹, S. Chieppa¹, V. Colonna¹, F.C. Tartaglia², S.R. Tari³, C. Bugea³, M. Corsalini¹, A. Palermo⁴, F. Inchingolo^{1*††} and A.M. Inchingolo^{1††}

¹Department of Interdisciplinary Medicine, University of Bari "Aldo Moro", Bari, Italy;

²Department of Biomedical, Surgical and Dental Sciences, University of Milan, Milan;

³Department of Innovative Technologies in Medicine and Dentistry, University of Chieti-Pescara, Chieti, Italy;

⁴College of Medicine and Dentistry, Birmingham, UK;

†These authors contributed equally as first authors

††These authors contributed equally as last authors

*Correspondence to:

Francesco Inchingolo, DDS

Department of Interdisciplinary Medicine,

University of Bari "Aldo Moro",

70124 Bari, Italy

e-mail: francesco.inchingolo@uniba.it

ABSTRACT

In contemporary orthodontic clinical practice, orthodontic mini-screws (OM) are often utilized due to their superior safety profile and ability to enhance skeletal anchoring. Periodontal ligament damage or tooth root perforation might occur during OM implantation. In rare cases, OM injury can result in long-term harm, such as ankylosis, osteosclerosis, and tooth loss. The objective of this study was to investigate any dangers and dental issues related to the usage of OMs. Ninety-nine papers were found after an unlimited research proposal of the PubMed, Cochrane, Web of Science, and Scopus databases using the keywords "orthodontic mini-screw" and "dental damage." Thirteen articles were chosen following qualifying and screening processes, such as those found through citation searches. According to four investigations, unintentional injuries brought on by OM. Most of the adverse effects were contained within the root level, and after the OM was promptly removed, the pain subsided, and restorative cement formed on its own. Endodontic therapy and/or surgery may be necessary in certain situations due to irreparable nerve damage and severe lesions to the dentin-pulp complex.

KEYWORDS: *orthodontics, root canal therapy, dental problems, insertion, mini-screws, nerve*

INTRODUCTION

The application of orthodontic mini-screws (OMs) as a reliable aid in anchoring management during orthodontic treatment (1) (Fig. 1, 2). Orthopedic appliances can be made more effective or less forceful by supporting OMs (2). The screw's diameter, length, and other dimensions, in addition to the depth of insertion, angulations, the insertion place site, and bone thickness, all have a direct impact on the technique's success rate (3-6).

Received: 15 May 2024
Accepted: 08 June 2024

ISSN 2038-4106 print
ISSN 2975-044X online

Copyright © by BIOLIFE 2024

This publication and/or article is for individual use only and may not be further reproduced without written permission from the copyright holder. Unauthorized reproduction may result in financial and other penalties. Disclosure: All authors report no conflicts of interest relevant to this article.

While thread depth and form are unimportant, implants with denser threads have higher stability (7). To improve the stability and precision of OM insertion and lower the risk of failure and side effects, surgically designed 3D templates are a useful tool (8). To direct the implantation while it is in the clinical phase, digital OMs can be positioned using a Cad Cam approach when CBCT and intraoral imaging are coupled.

There have been numerous reports of issues with the insertion, usage, and removal of OMs (9-11). Inserting OMs in the lower arch without properly examining anatomical structures could reveal significant harm to the lingual and mental nerves. There are no noteworthy reports of problems resulting from the insertion of OMs through the maxillary sinus (12, 13). Conversely, the most common side effect of OMs is said to be tooth root damage (14-16). OMs positioned incorrectly with respect to the tooth root might cause damage to the tooth element as well as OM movement and failure.

Reviews on the dangers of inserting OMs into other structures, like the palatine artery or maxillary sinus, also exist (17-19). The purpose of this review was to evaluate tooth damage after OM insertion to understand any potential risks and dental concerns associated with OM use (20).

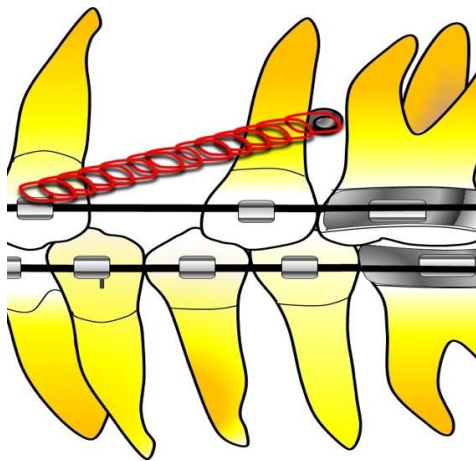


Fig. 1. Distal traction with OM.

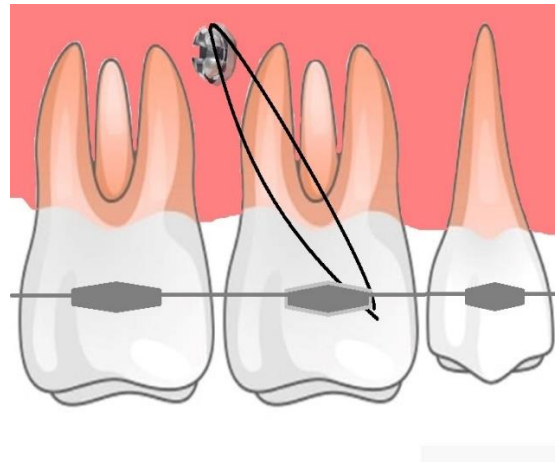


Fig. 2. Stabilization with OM.

MATERIALS AND METHODS

Registration and protocol

This review (21) followed the Suggested Report Formats for Systematic Reviews and Meta-Analysis (PRISMA) literature search guidelines. It was also registered under CRD42022380972 in the International Prospective Register of Systematic Reviews PROSPERO ID: 552746.

The search process

Between December 2007 and February 2019, we conducted time-limited searches in PubMed, Cochrane, Web of Science, and Scopus to find articles related to our subject. The following Boolean keywords were incorporated into the search strategy because they correspond to the purpose of our examination, which focuses primarily on the adverse effects of OMs on teeth (“orthodontic mini-screw” AND “tooth damage”) (Table I).

Table I. Search process.

Indicator for database searches	Keywords: A "orthodontic mini-screw"; B "tooth damage" Boolean Expressions: ("A" AND "B") Duration: indefinite Pubmed, Cochrane, Web of Science, and Scopus are electronic databases.
---------------------------------	--

Criteria for inclusion and exclusion

The following criteria had to be met for inclusion:

1. human studies only;
2. studies written in English;
3. open-access studies;
4. case studies or clinical trials.

Excluded were studies addressing tooth injury in the context of OMs, surgical procedures, complications unrelated to teeth, OMs, or any other choice facet of orthodontic therapy.

Information processing

Author disagreements on which articles to publish were discussed and settled.

RESULTS

99 studies were found using an electronic database search (PubMed = 45, Cochrane = 1, Web of Science = 18, and Scopus = 35). Upon elimination of duplicates, 53 studies stayed. After reviewing the acceptable publications' reference list, 6 more relevant articles were added. Thirty-six papers were eliminated due to being off-topic, nine not being available, and two being animal research (Fig. 3).

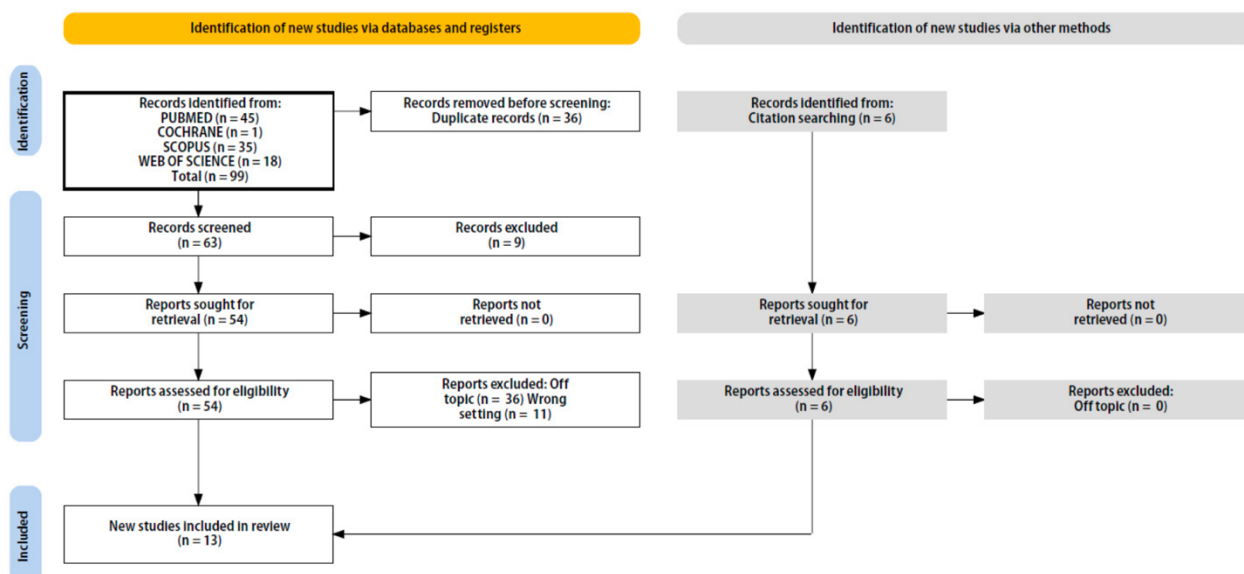


Fig. 3. Literature search Preferred Reporting Items for Systematic Reviews and Meta-Analyses (PRISMA) flow diagram and database search indicators.

A full-text examination revealed that 13 papers all satisfied the inclusion requirements. Table II presents an overview of the features of every study included (Fig. 4, 5).

Table II. Included studies.

Author	Study Design	Sample	Type of Complications	Causes	Healing	Parameters	Recommendations
Ahmed et al., 2016 (22)	Case report	1	Damage of the dentin-pulp complex	Intentional root contact due to OM tip fracture	Tooth extraction after 4 weeks	Spontaneous; Normal pulp vitality test	There are no variations in the method of insertion. Pay attention to the insertion
Ghanbarzadeh et al., 2017 (23)	Clinical study	14	Cementum, pulp, and root dentin's inflammatory response	Intentional root injury	Tooth extraction after 8 weeks	Spontaneous; Normal pulp vitality test	There is no variation in the insertion method. Pay attention to the insert
Hwang et al., 2011 (24)	Case report	1	Iatrogenic root perforation and chronic apical periodontitis	Unintentional injury	No	Negative pulp/cold test; no spontaneous healing	Proper choice of the insertion site for OMs

Kadioglu et al., 2008 (25)	Clinical study	10	Root resorption	Intentional premolar root contact	after 4 or 8 weeks, tooth extraction	Spontaneous; Normal collagen fiber organization	Attention in insertion
Lim et al., 2013 (26)	Case report	1	Root surface damage	Unintentional injury	No	No spontaneous healing	Anatomy is an important surgical intervention and root canal therapy insertion care.
Baik et al., 2014 (27)	Case report	4	clinical repercussions following root contact	Unintentional injury	after root injury, OM was removed instantly	Spontaneous healing	Attention in insertion
McCabe et al., 2012 (28)	Case report	1	Iatrogenic root perforation	Unintentional injury	No	Pulpal necrosis and apicectomy	Attention in insertion
Maino et al., 2007 (29)	Clinical study	2	Root perforation	Intentional injury	Teeth whose roots were compressed against the screws until they were extracted (group 2 after 57 days and group 1 after 30 days of recovery)	A histology study revealed teeth with ongoing resorption lacunae without any signs of repair.	Drill contact and/or Temporary Anchorage Devices (TAD) damage is the reason why resorptive roots get damaged. After that, fix the contact breakage.
Ahmed et al., 2012 (30)	Clinical study	17	Root perforation	Intentional injury	Reparative cementum occurs after 12 weeks, producing a good repair.	Every tooth selected for this investigation recovered well during the whole healing process. By the end of the fourth week, significant repairs were completed. Almost 60% of the teeth had substantial repair by week four; by week eight, that percentage had declined to 35%; and by week twelve, it had fallen to 28.6%. Seventy percent of the teeth had healed well by week 12.	A minimum of 1 mm should separate a mini-screw from a root for periodontal health and mini-screw stability. Consequently, mini-screws with a diameter of 1.5 mm or less are safe for interradicular insertion if there is a minimum 3.5 mm spacing between the roots.
Hourfar et al., 2017 (31)	Retrospective study	284	loss due to pulp sensibility testing of the maxillary front teeth following the insertion of paramedian OMs in the anterior palate, which is 3 to 5 mm distant from the suture.	Age, gender, upper central inclination, state of dentition, and placement of insertion	Of the 284 samples, 3 showed a decline in vitality.	Negative pulp/cold test; no spontaneous healing	Even though the teeth that lost vitality showed no radiographic signs of OMI-induced damage, the proximity of the implants to the anterior teeth was positively and substantially linked with loss of vitality. OMs should be positioned in the middle plane or the third rugae.
Yerawedakar et al., 2018 (32)	Clinical study	10	Root perforation	Intentional injury	One-day, three-week, six-week, and 12-week intervals of extraction	A histological examination revealed that the cementum's continuity broke after a day. Cementum development started early in the third week, and the thickness had	It is recommended to avoid moving the teeth further for a minimum of 12 weeks while the root heals.

						progressively grown by the end of the 12 weeks. After 12 weeks, the notch was filled due to a gradual increase in the thickness of the freshly created cementum.	
Shinohara et al., 2013 (33)	Prospective study	50	Root contact	Unintentional injury	147 OMs of the mini-implants made contact with nearby roots in 20% of cases.	Researchers examined the mesiodistal implantation position by measuring the mesial and distal distances between the mini-implant and the root. Next, the inclinations of the implant in the horizontal and vertical	When mini-implants are placed into the right maxillary buccal alveolar bone, they should not come into contact with the distal adjoining tooth's root.
Güler et al., 2019 (34)	Clinical study	42	Root contact	Intentional injury	Left premolars were excised at 4, 8, or 12 weeks following OM's root contact. Micro-CT data suggest that a 12-week healing period may not be sufficient to restore the roots fully.	Repair procedures 4, 8, and 12 weeks following micro- Tac Cone Beam (TC) contact with TAD	In comparison to leaving a TAD in touch with the root in situ without force, force loading from springs on injured roots generated by TAD contact during orthodontic treatment may worsen the damage and decrease healing. No more than 12 weeks should pass after forcing reloading on broken roots.

DISCUSSION

Root resorption may result from stress to the root or the periodontal ligament brought on by contact between the screw and the tooth root (35, 36). The deposition of cellular cementum will effectively cure a superficially wounded root if there is no pulpal involvement (37). Furthermore, a few weeks after the screws are taken out, a quicker and full repair occurs (24). Studies have shown that 75% of the repair may be finished in 8 weeks (25), and others have shown that the tooth and periodontium can heal completely in 12 to 18 weeks following the removal of the OM (38). After nearly 20 weeks, some people have shown full recovery (39).

Ghanbarzadeh et al. have studied the histology reaction of cementum, root dentin, and pulp resulting from purposeful damage to the roots using self-tapping and self-drilling OMs (23). In 75.4% of the teeth, reparative cementum development was seen, and there was no discernible difference in the restorative cement formation between the group that had repairs and the group that did not (23).

Baik et al. have also described the consequences of the OM's interaction with the tooth root during orthodontic treatment and insertion. The OMs were promptly removed in both of the instances the authors examined, with pain treatment, and transported to other locations, keeping the screw tight and not influencing the tooth's movement. Eight weeks following the instant removal of the screw or orthodontic strength, cement started to aid in root recovery. After around a year, There were no symptoms, including discomfort, discoloration, root canals, or ankylosis (27).

According to research by Lim et al., improper and repetitive insertion of OMs results in chronic inflammation and harm to the roots of the teeth, which can induce pulp necrosis and periapical periodontitis (26).

Complications, including ankylosis, osteosclerosis, and loss of tooth vitality, can sometimes arise from root injury. If the injured area accounts for more than 4 mm or 20% of the root, ankylosis may develop (24). The main cause of issues with neighboring teeth during OM implantation and after orthodontic loading seems to be the strong relationship between the dental roots (34, 40). A pulp-related root fracture may result in the tooth losing its vitality, depending on the extent of the damage. When a screw pierces the root more than half of its diameter, pulp vitality is lost (28, 41). The ensuing pulp necrosis destroys the surrounding periodontal and periapical tissues (29).

Because of the ongoing trauma and inflammation, the OM created a breach that let external pathogens enter the periodontal dental ligament (PDL) area and cause bone deterioration around the roots, which led to pulp necrosis (22,

42). Injuries at the roots can be seen by histology and radiological examination (24). The inability to respond to pulp sensitivity tests is used to assess the loss of vitality. (24, 31, 41, 43, 44).

Treatment for root perforation via the access cavity might begin after radiographic confirmation of the damage has been acquired. An intracanal technique is used to treat a perforation. A surgical repair is necessary if the standard endodontic treatment is unsuccessful (30, 32, 35, 37, 43). In the surgical method, a bone window is made, and the perforation site is then sealed using a substance such as mineral trioxide aggregate (MTA). The control of bacterial infections at the site of perforation has a significant impact on the prognosis (22, 30).

McCabe et al. investigated the endodontic treatment of tooth damage following the implantation of OMs. The authors presented a case of an unintentional fracture of the OM tip during the placement and inclusion close to the dental implant (element 1.6) (28). A sinus tract measuring more than 1.6 was observed more than a week later. However, sensitivity testing revealed that the tooth was in good condition. After the screw was removed, the 1.6 tooth looked to be asymptomatic for nine months, at which point the fistula returned after the conclusion of the orthodontic therapy.

The patient mentioned a past episode of pain that was exacerbated by the cold. Periodontal probing showed 3 mm interproximal to 1 mm buccally and lingually, and the mobility was normal. A lesion was visible on intraoral radiography close to the palatal and mesiobuccal roots. Below the perforation, an apicectomy was necessary. A 5-year follow-up showed no symptoms (28).

The risk of injury during inter-radicular placement can be considerably increased if the practitioner inadvertently changes the insertion angle. The apical zone has more open space between roots but without associated gingiva. As a result, the clinician needs to stay within the "safe zones," defined as 1.0 to 5.0 mm at least away from the root (22). In particular, the positioning of the OM across the larger palatine artery in the upper arch raises the likelihood of biomechanical control loss and palatal root contact (25,38, 45, 46).

We saw nerve involvement in the lower arch, and the clinical advice is to employ a short retromolar OM. Numerous writers in this instance have documented measurements using screws that are no longer than 8 mm and are inserted into the buccal retromolar area for the mandibular location below the anterior ramus (38, 47). The root damage that results from implanting OMs in a mandibular incisor and how to treat this issue was discussed by Hwang et al. (24). One of the two OMs between the central and lateral incisors punctured the right lateral incisor's root to create an anterior sector intrusion (33). Following the determination that the tooth lacked vitality and considering the radioactivity in the apical region on the X-ray, an apicectomy was carried out, with the perforation being sealed with MTA (48, 49). The reabsorption process ended without further stimulation, and cement-like tissue developed in two to three weeks (50).

This review's primary restriction is the number and caliber of the papers included in the analysis. By concentrating solely on tooth destruction, it sought to examine the harm that OMs do. More comprehensive randomized controlled trials are required to give clinicians evidence-based recommendations.

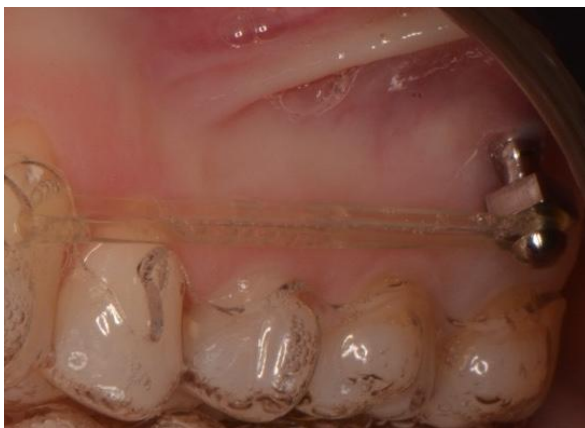

Fig. 4. *Vestibular OM.*

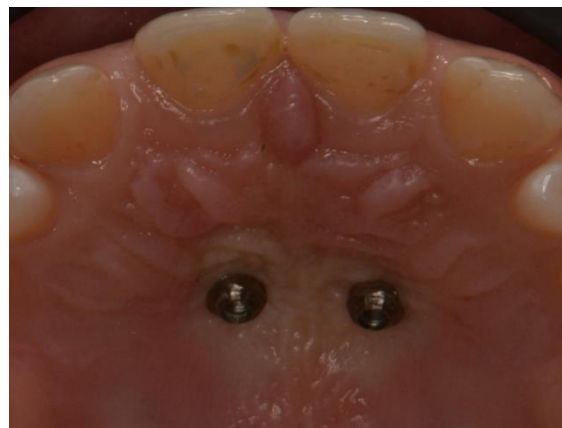

Fig. 5. *Palatal OM.*

CONCLUSIONS

The positioning of OMs is a crucial operation, and root injury can still happen even with precautions such as taking an apical radiograph prior to screw placement. The lesion is often healed without repercussions when the harm brought on by screw root contact is restricted to the periodontal structures. In instances where there was considerable damage to the tooth root and iatrogenic perforations, endodontic and surgical therapy was necessary to address this OM result. In summary, the findings demonstrated that if OMs are inserted appropriately, dental problems are typically

minimal and may go away on their own. Consequently, it was discovered that the use of OMs was a safe process with few negative consequences.

REFERENCES

- Adina SS, Dipalma G, Bordea IR, et al. Orthopedic joint stability influences growth and maxillary development: clinical aspects. *J Biol Regul Homeost Agents*. 2020;34(3):747-756. doi:https://doi.org/10.23812/20-204-e-52
- Inchingolo AD, Ferrara I, Viapiano F, et al. Rapid Maxillary Expansion on the Adolescent Patient: Systematic Review and Case Report. *Children*. 2022;9(7):1046. doi:https://doi.org/10.3390/children9071046
- Aiello D, Nucera R, Costa S, Michele Mario Figliuzzi, Paduano S. A Simplified Digital Approach to Treatment a Postpuberty Patient with a Class III Malocclusion and Bilateral Crossbite. *Case Reports in Dentistry*. 2021;2021:1-12. doi:https://doi.org/10.1155/2021/3883187
- Nucera R, Costa S, Bellocchio AM, et al. Evaluation of palatal bone depth, cortical bone, and mucosa thickness for optimal orthodontic miniscrew placement performed according to the third palatal ruga clinical reference. *European Journal of Orthodontics*. 2022;44(5):530-536. doi:https://doi.org/10.1093/ejo/cjac007
- Janson G, Mariana Pracucio Gigliotti, Sérgio Estelita, Chiqueto K. Influence of miniscrew dental root proximity on its degree of late stability. *International Journal of Oral and Maxillofacial Surgery*. 2013;42(4):527-534. doi:https://doi.org/10.1016/j.ijom.2012.09.010
- Inchingolo F, Tatullo M, Marrelli M, et al. Combined occlusal and pharmacological therapy in the treatment of temporomandibular disorders. *European review for medical and pharmacological sciences*. 2011;15(11):1296-1300.
- Maciej Jedliński, Janiszewska-Olszowska J, Mazur M, Katarzyna Grocholewicz, Pedro Suárez Suquía, David Suárez Quintanilla. How Does Orthodontic Mini-Implant Thread Minidesign Influence the Stability?—Systematic Review with Meta-Analysis. *Journal of Clinical Medicine*. 2022;11(18):5304-5304. doi:https://doi.org/10.3390/jcm11185304
- Jedliński M, Janiszewska-Olszowska J, Mazur M, Ottolenghi L, Grocholewicz K, Galluccio G. Guided Insertion of Temporary Anchorage Device in Form of Orthodontic Titanium Miniscrews with Customized 3D Templates—A Systematic Review with Meta-Analysis of Clinical Studies. *Coatings*. 2021;11(12):1488. doi:https://doi.org/10.3390/coatings11121488
- Inchingolo F, Ballini A, Cagiano R, et al. Immediately loaded dental implants bioactivated with platelet-rich plasma (PRP) placed in maxillary and mandibular region. *La Clinica Terapeutica*. 2015;166(3):e146-152. doi:https://doi.org/10.7417/CT.2015.1845
- Papageorgiou SN, Zogakis IP, Papadopoulos MA. Failure rates and associated risk factors of orthodontic miniscrew implants: A meta-analysis. *American Journal of Orthodontics and Dentofacial Orthopedics*. 2012;142(5):577-595.e7. doi:https://doi.org/10.1016/j.ajodo.2012.05.016
- Dimonte M, Inchingolo F, Minonne A, Arditi G, Dipalma G. Bone SPECT in management of mandibular condyle hyperplasia. Report of a case and review of literature. *Minerva stomatologica*. 2004;53(5):281-285.
- Makade CS, Meshram GK, Warhadpande M, Patil PG. A comparative evaluation of fracture resistance of endodontically treated teeth restored with different post core systems - an in-vitro study. *The Journal of Advanced Prosthodontics*. 2011;3(2):90. doi:https://doi.org/10.4047/jap.2011.3.2.90
- Scarano A, Pecora G, Piattelli M, Piattelli A. Osseointegration in a Sinus Augmented With Bovine Porous Bone Mineral: Histological Results in an Implant Retrieved 4 Years After Insertion. A Case Report. *Journal of Periodontology*. 2004;75(8):1161-1166. doi:https://doi.org/10.1902/jop.2004.75.8.1161
- Kuroda S, Yamada K, Deguchi T, Hashimoto T, Kyung HM, Yamamoto TT. Root proximity is a major factor for screw failure in orthodontic anchorage. *American Journal of Orthodontics and Dentofacial Orthopedics*. 2007;131(4):S68-S73. doi:https://doi.org/10.1016/j.ajodo.2006.06.017
- Kuroda S, Sugawara Y, Deguchi T, Kyung HM, Takano-Yamamoto T. Clinical use of miniscrew implants as orthodontic anchorage: Success rates and postoperative discomfort. *American Journal of Orthodontics and Dentofacial Orthopedics*. 2007;131(1):9-15. doi:https://doi.org/10.1016/j.ajodo.2005.02.032
- Piattelli A, Scarano A, Piattelli M. Detection of alkaline and acid phosphatases around titanium implants: a light microscopical and histochemical study in rabbits. *Biomaterials*. 1995;16(17):1333-1338. doi:https://doi.org/10.1016/0142-9612(95)91049-5
- Jones JP, Elnagar MH, Perez DE. Temporary Skeletal Anchorage Techniques. *Oral and Maxillofacial Surgery Clinics of North America*. 2020;32(1):27-37. doi:https://doi.org/10.1016/j.coms.2019.08.003
- Mohammed H, Wafaie K, Rizk MZ, Almuzian M, Sosly R, Bearn DR. Role of anatomical sites and correlated risk factors on the survival of orthodontic miniscrew implants: a systematic review and meta-analysis. *Progress in Orthodontics*. 2018;19(1). doi:https://doi.org/10.1186/s40510-018-0225-1
- Poggio PM, Incorvati C, Velo S, Carano A. “Safe Zones”: A Guide for Miniscrew Positioning in the Maxillary and Mandibular Arch. *The Angle Orthodontist*. 2006;76(2):191-197. doi:https://doi.org/10.1043/0003-3219(2006)076%5B0191:SZAGFM%5D2.0.CO;2
- Truong VM, Kim S, Kim J, Lee JW, Park YS. Revisiting the Complications of Orthodontic Miniscrew. *BioMed Research International*. 2022;2022:8720412. doi:https://doi.org/10.1155/2022/8720412

21. Page MJ, McKenzie JE, Bossuyt PM, et al. The PRISMA 2020 statement: an Updated Guideline for Reporting Systematic Reviews. *British Medical Journal*. 2021;372(71). doi:<https://doi.org/10.1136/bmj.n71>
22. Ahmed VKS, Krishnaswamy NR, Thavarajah R. Miniscrew implant fracture and effects of such retained tip on dentin-pulp complex: a histological report. *Dental traumatology*. 2015;32(2):161-165. doi:<https://doi.org/10.1111/edt.12225>
23. Shafae H, Ghanbarzadeh M, Heravi F, et al. Cementum and dentin repair following root damage caused by the insertion of self-tapping and self-drilling miniscrews. *Journal of orthodontic science*. 2017;6(3):91. doi:https://doi.org/10.4103/jos.jos_150_16
24. Hwang YC, Hwang HS. Surgical repair of root perforation caused by an orthodontic miniscrew implant. *American Journal of Orthodontics and Dentofacial Orthopedics*. 2011;139(3):407-411. doi:<https://doi.org/10.1016/j.ajodo.2008.11.032>
25. Kadioglu O, Büyükyilmaz T, Zachrisson BU, Maino BG. Contact damage to root surfaces of premolars touching miniscrews during orthodontic treatment. *American Journal of Orthodontics and Dentofacial Orthopedics*. 2008;134(3):353-360. doi:<https://doi.org/10.1016/j.ajodo.2006.09.069>
26. Lim G, Kim KD, Park W, Jung BY, Pang NS. Endodontic and Surgical Treatment of Root Damage Caused by Orthodontic Miniscrew Placement. *Journal of endodontics*. 2013;39(8):1073-1077. doi:<https://doi.org/10.1016/j.joen.2013.04.037>
27. Baik U, Kook YA, Tanaka OM, Kim KB. Root contact with miniscrews during mesiodistal movement of the molar. *Journal of the World Federation of Orthodontists*. 2014;3(2):e95-e100. doi:<https://doi.org/10.1016/j.ejwf.2014.02.001>
28. McCabe P, Kavanagh C. Root perforation associated with the use of a miniscrew implant used for orthodontic anchorage: a case report. *International Endodontic Journal*. 2012;45(7):678-688. doi:<https://doi.org/10.1111/j.1365-2591.2012.02022.x>
29. Maino B g, Weiland F, Attanasi A, Zachrisson B, Buyukyilmaz T. Root damage and repair after contact with miniscrews. *Journal of clinical orthodontics*. 2007;41(12):762-766; quiz 750.
30. Ahmed V KS, Rooban T, Krishnaswamy NR, Mani K, Kalladka G. Root damage and repair in patients with temporary skeletal anchorage devices. *American Journal of Orthodontics and Dentofacial Orthopedics*. 2012;141(5):547-555. doi:<https://doi.org/10.1016/j.ajodo.2011.11.014>
31. Hourfar J, Bister D, Lissou JA, Ludwig B. Incidence of pulp sensibility loss of anterior teeth after paramedian insertion of orthodontic mini-implants in the anterior maxilla. *Head & Face Medicine*. 2017;13(1). doi:<https://doi.org/10.1186/s13005-016-0134-9>
32. Yerawadekar SA, Rahalkar JS, Darda M, Sarode SC, Sarode GS. Histological Evaluation of Root Repair after Damage due to Intentional Contact with Orthodontic Micro-Screw Implants: An in vivo Study. *JOURNAL OF CLINICAL AND DIAGNOSTIC RESEARCH*. Published online 2018. doi:<https://doi.org/10.7860/jcdr/2018/31166.11157>
33. Shinohara A, Motoyoshi M, Uchida Y, Shimizu N. Root proximity and inclination of orthodontic mini-implants after placement: Cone-beam computed tomography evaluation. *American Journal of Orthodontics and Dentofacial Orthopedics*. 2013;144(1):50-56. doi:<https://doi.org/10.1016/j.ajodo.2013.02.021>
34. Çelik Güler Ö, Malkoç S. Effects of orthodontic force on root surface damage caused by contact with temporary anchorage devices and on the repair process. *The Korean Journal of Orthodontics*. 2019;49(2):106. doi:<https://doi.org/10.4041/kjod.2019.49.2.106>
35. Watanabe H, Deguchi T, Hasegawa M, Ito M, Kim S, Takano-Yamamoto T. Orthodontic miniscrew failure rate and root proximity, insertion angle, bone contact length, and bone density. *Orthodontics & Craniofacial Research*. 2012;16(1):44-55. doi:<https://doi.org/10.1111/ocr.12003>
36. Ryosuke Ikenaka, Koizumi S, Otsuka T, Yamaguchi T. Effects of root contact length on the failure rate of anchor screw. *Journal of Oral Science*. 2022;64(3):232-235. doi:<https://doi.org/10.2334/josnusd.21-0536>
37. Inchingolo F, Martelli FS, Gargiulo Isacco C, et al. Chronic Periodontitis and Immunity, Towards the Implementation of a Personalized Medicine: A Translational Research on Gene Single Nucleotide Polymorphisms (SNPs) Linked to Chronic Oral Dysbiosis in 96 Caucasian Patients. *Biomedicines*. 2020;8(5):E115. doi:<https://doi.org/10.3390/biomedicines8050115>
38. Kravitz ND, Kusnoto B. Risks and complications of orthodontic miniscrews. *American Journal of Orthodontics and Dentofacial Orthopedics*. 2007;131(4):S43-S51. doi:<https://doi.org/10.1016/j.ajodo.2006.04.027>
39. Dao V, Rahul Renjen, Prasad HS, Rohrer MD, Maganzini AL, Kraut RA. Cementum, Pulp, Periodontal Ligament, and Bone Response After Direct Injury With Orthodontic Anchorage Screws: A Histomorphologic Study in an Animal Model. *Journal of oral and maxillofacial surgery*. 2009;67(11):2440-2445. doi:<https://doi.org/10.1016/j.joms.2009.04.138>
40. Asscherickx K, Vannet BV, Wehrbein H, Sabzevar MM. Root repair after injury from mini-screw. *Clinical Oral Implants Research*. 2005;16(5):575-578. doi:<https://doi.org/10.1111/j.1600-0501.2005.01146.x>
41. Gopikrishna V, Pradeep G, Venkateshbabu N. Assessment of pulp vitality: a review. *International Journal of Paediatric Dentistry*. 2009;19(1):3-15. doi:<https://doi.org/10.1111/j.1365-263x.2008.00955.x>
42. Chauhan R, Rasaratnam L, Alani A, Djemal S. Adult Dental Trauma: What Should the Dental Practitioner Know? *Primary Dental Journal*. 2016;5(3):70-81. doi:<https://doi.org/10.1177/205016841600500308>
43. Han G, Hu M, Zhang Y, Jiang H. Pulp vitality and histologic changes in human dental pulp after the application of moderate and severe intrusive orthodontic forces. *American Journal of Orthodontics and Dentofacial Orthopedics*.

- 2013;144(4):518-522. doi:<https://doi.org/10.1016/j.ajodo.2013.05.005>
44. Alghaithy RA, Qualtrough AJE. Pulp sensibility and vitality tests for diagnosing pulpal health in permanent teeth: a critical review. *International Endodontic Journal*. 2016;50(2):135-142. doi:<https://doi.org/10.1111/iej.12611>
 45. Yi J, Ge M, Li M, et al. Comparison of the success rate between self-drilling and self-tapping miniscrews: a systematic review and meta-analysis. *The European Journal of Orthodontics*. 2016;39(3):cjlw036. doi:<https://doi.org/10.1093/ejo/cjlw036>
 46. Cantore S, Ballini A, De Vito D, et al. Characterization of human apical papilla-derived stem cells. *J Biol Regul Homeost Agents*. 2017;31(4):901-910.
 47. Son S, Motoyoshi M, Uchida Y, Shimizu N. Comparative study of the primary stability of self-drilling and self-tapping orthodontic miniscrews. *American Journal of Orthodontics and Dentofacial Orthopedics*. 2014;145(4):480-485. doi:<https://doi.org/10.1016/j.ajodo.2013.12.020>
 48. Aminoshariae A, Hartwell GR, Moon PC. Placement of Mineral Trioxide Aggregate Using Two Different Techniques. *Journal of Endodontics*. 2003;29(10):679-682. doi:<https://doi.org/10.1097/00004770-200310000-00017>
 49. Holland R, Arlindo Otoboni Filho J, de Souza V, Juvenal Nery M, Felício Estrada Bernabé P, Dezan EJr. Mineral Trioxide Aggregate Repair of Lateral Root Perforations. *Journal of Endodontics*. 2001;27(4):281-284. doi:<https://doi.org/10.1097/00004770-200104000-00011>
 50. Tronstad L. Root resorption - etiology, terminology and clinical manifestations. *Dental Traumatology*. 1988;4(6):241-252. doi:<https://doi.org/10.1111/j.1600-9657.1988.tb00642.x>



Review

ANTIBACTERIAL ACTIVITY OF TITANIUM NITRIDE COATING: A SYSTEMATIC REVIEW

S. Oliva¹, A. Scarano¹, O. Trubiani¹, S.R. Tari¹, M. Capogreco², C. Bugea¹ and G. Murmura¹

¹Department of Innovative Technologies in Medicine and Dentistry, University “G. d’Annunzio” of Chieti-Pescara, Chieti, Italy;

²Department of Life, Health and Environmental Sciences, University of L’Aquila, L’Aquila;

Correspondence to:

Antonio Scarano, DDS

Department of Innovative Technologies in Medicine and Dentistry,
University “G. d’Annunzio” of Chieti-Pescara

Strada Marcello Mucci 38,
67100 Chieti, Italy

e-mail: ascarano@unich.it

ABSTRACT

In recent years, titanium nitride (TiN) coating has been used as an adjunctive surface treatment to improve the physico-mechanical and aesthetic properties of dental implants. Several studies have investigated the antibacterial activity of TiN coatings on dental implants, demonstrating their potential to mitigate bacterial colonization and biofilm formation. The aim of this systematic review was to evaluate the actual efficacy of TiN-coated implants on antibacterial activity. Data was collected following the identification of PICO. The review was based on the Preferred Reporting Items for Systematic Reviews and Meta-Analyses (PRISMA) guidelines. A search was performed on PubMed-Medline, Embase, Web of Knowledge, and Google Scholar for studies published until February 2023, including the following keywords: “titanium nitride, dental implant coating, antibacterial activity, biofilm formation, plaque formation, modified implant surfaces, implant abutments”. After evaluating and scanning the articles that met the study inclusion criteria, it can be stated that the TiN implant coating can inhibit the initial biofilm formation involved in mucositis by reducing the progression into peri-implantitis related to the bio-corrosion activity of the TiN of the implant surface. In the light of these findings, more clinical studies need to be performed.

KEYWORDS: *systematic review, titanium nitride, TiN, antibacterial activity, dental implant coating, peri-implantitis, bacterial adhesion*

INTRODUCTION

In recent decades, the development of dental implants to restore masticatory function and dental aesthetics compromised by partial or complete edentulism has been a turning point in dentistry (1, 2). Every year, a significant number of dental implants are placed, and a substantial proportion of these will experience biological issues, such as inflammation and the deterioration of peri-implant bone loss. When implants are affected by peri-implant mucositis, they display clinical indicators of inflammation. These signs include reddened soft tissue surrounding the implant, bleeding, and/or pus formation when probed (3-5). If left untreated, peri-implant mucositis progresses to a permanent condition known as peri-implantitis.

Received: 15 May 2024
Accepted: 04 June 2024

ISSN 2038-4106 print
ISSN 2975-044X online
Copyright © by BIOLIFE 2024

This publication and/or article is for individual use only and may not be further reproduced without written permission from the copyright holder. Unauthorized reproduction may result in financial and other penalties. Disclosure: All authors report no conflicts of interest relevant to this article.

In peri-implantitis, the soft tissue around the implant becomes inflamed, leading to bleeding and/or pus formation upon probing (6, 7). Additionally, there is an increase in probing depth, which can extend to 6 mm or more (8). Studies suggest that the prevalence of peri-implant mucositis and peri-implantitis is approximately 43% in Europe and 22% in South and North America. Treatment outcomes for this condition have been less than satisfactory in the long term, with 75% of cases remaining unresolved or recurring after 5 years. Therefore, it is advisable to prevent peri-implantitis at all stages (9). Currently, there is a consensus among scientists that bacterial plaque is the primary cause of peri-implant disease, and its removal is crucial for restoring healthy peri-implant tissue (10). In fact, peri-implant infection can occur at any time from the moment implants are placed. However, the initial four weeks following implantation are considered the most susceptible period for infection (11). This is because the implant and the bone interface have not yet fully integrated, resulting in a relatively weak anti-infective capability. Consequently, there is a risk of early implant failure before the crown is placed. Additionally, it is crucial to have a long-lasting antibacterial effect on the implant surface to prevent infection until the complete formation of the integrated interface (12-14). Recent advancements have been made in modifying the surface of implant materials to reduce bacterial adhesion and hinder biofilm formation, aiming to prevent infection during the early stages after implantation (15).

Nevertheless, coatings with antibacterial properties applied to titanium surfaces using non-covalent adsorption methods (such as hydrogen bonding and electrostatic interactions) are less durable, as the antibacterial components can quickly detach from the surface. To overcome these problems, titanium nitride (TiN) coating has recently been introduced in titanium dental implants (16). TiN is commonly used to coat numerous metal instruments, including surgical ones, to improve their surface properties and aesthetics (due to its golden color) (17).

TiN-coated dental implants have higher physical-mechanical properties and allow for better camouflage under the gum tissue compared to traditional grey titanium implants. Physical Vapour Deposition (PVD) is the most common technique for coating pure titanium with TiN. It is generated in the vapor phase by interacting pure titanium with gaseous nitrogen prior to deposition (18). Thin coatings of TiN and TiO₂ are applied with PVD techniques, altering the surface's chemical composition and crystal structure while maintaining the implant surface's micro-thinness (19). This process results in an oxide layer on the implant surface that alters its chemical composition (20).

The aim of this systematic review was to study the antibacterial properties of the TiN coating of the dental implant on microbial biofilm adhesion and suppression of bacterial growth.

MATERIALS AND METHODS

Search strategy

This systematic review adhered to the PRISMA (Preferred Reporting Items for Systematic Reviews and Meta-analyses) guidelines and utilized the PICO(S) approach (Patient or Population, Intervention, Control or Comparison, Outcome, and Study types) (21), as illustrated in Fig. 1. Thorough research was conducted on relevant literature and papers exploring the antibacterial properties of TiN-coated dental implants. Databases such as PubMed (Medline), Scopus, Web of Knowledge, and Cochrane were extensively searched.

Various combinations of keywords were employed, including Titanium nitride, dental implant coating, antibacterial activity, biofilm formation, plaque formation, modified implant surfaces, and implant abutments. Only articles in the English language were considered, and to eliminate duplicates, the references from identified records were uploaded as Research Information Systems files into Zotero (RRCHNM, Fairfax, Virginia). The PICO question was formulated as follows: P-population: *in vitro* studies and patients with dental implants; I-intervention: titanium disks with TiN coating or abutment; C-control: conventionally produced/restored teeth and implants; O-outcome: assessment of antibacterial activity of TiN coating; S-study designs: *in vivo* and *in vitro* studies, systematic and narrative reviews. The search strategy aligned with the focused PICOS question is presented in Fig. 2. The review was registered in Prospero under ID CRD42023467563.

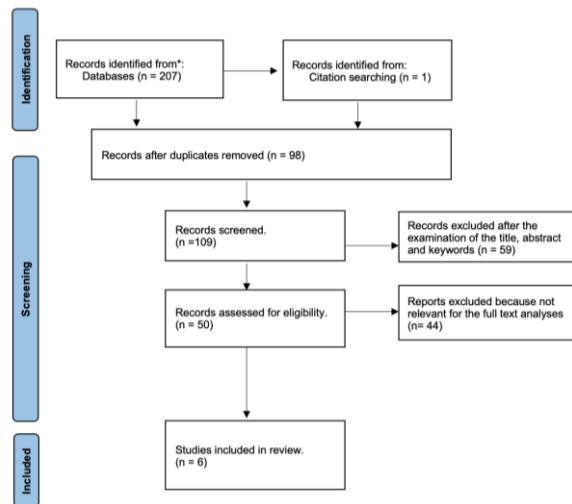


Fig. 1. Search flowchart as described in the PRISMA guidelines. Caption: (n = number of records).

Focused (PICO)	Question	Do TiN-coated implants exhibit antibacterial properties according to <i>in vivo</i> and <i>in vitro</i> studies?	
Search strategy	Population	<i>in vitro</i> studies and patients with dental implants;	
	Intervention	titanium disks with TiN coating or abutment;	
	Comparison	conventionally produced/manufactured restorations (natural teeth and implants);	
	Outcome	evaluation of the antibacterial activity of titanium nitride coating.	

Fig. 2. Search strategy according to the focused question (PICO).

Inclusion and exclusion criteria

Articles were considered appropriate when satisfying the following inclusion criteria:

1. articles addressing at least one of the following topics regarding dental implants TiN coatings: antibacterial activity, bacterial growth, and proliferation-related to TiN coating disks compared to titanium alone or other coatings;
2. studies performed *in vitro* or *in vivo*;
3. systematic and narrative reviews.

Articles that did not have the above information were excluded from the review.

Paper selection

Clinical and *in vitro* studies were selected according to title and abstract. The participants, intervention, comparison, and outcomes (PICO) were determined to formulate a specific question: What is the efficacy of TiN on antibacterial activity?

Data extraction

Authors independently gathered the following information from the included studies: study design, coating type, control group, test procedure, and the effect of abutment coating on bacteria. Evaluations were conducted separately by the authors and subsequently verified through comparison.

Quality and risk of bias assessment

The clinical study was evaluated using the revised RoB tool based on the Cochrane RoB assessment method (22). For *in vitro* studies; the QUIN Tool was used, which was formulated to assess the quality and measure the risk of bias in *in vitro* studies. This Tool presents 12 points. The QUIN final assessment ranked each study aspect at a ‘low’, ‘medium’, or ‘high’ risk of bias (23).

RESULTS

The preliminary search included 207 articles. It was decreased to 204 after duplicates were removed. After the title and abstract screening, 12 articles were read in full text. Six articles were chosen after a final examination included in the systematic review. Only one human study was included in the review; the other 5 were *in vitro*. It was described in Fig. 1; moreover, *In vitro* studies included in the review were assessed using the Quality Assessment Tool For *In vitro* Studies (QUIN Tool) (Table I, II). A low risk of bias was found in three studies (24-26). The other three studies exhibit a medium risk of bias.

Table I. *The QUIN Tool assessment.*

Author	Clearly Stated Aims/Objectives	Detailed Explanation of Sample Size Calculation	Detailed Explanation of Sampling Technique	Details of Comparison Group	Detailed Explanation of Methodology	Operator Details	Randomization	Method of Measurement of Outcome	Outcome Assessor Details
Großner-Schreiber et al.	2	2	2	2	2	2	1	2	2
Zhang et al.	2	1	2	2	2	2	1	1	1
Ji et al.	2	1	2	2	2	1	1	2	1
Brunello et al.	2	2	2	2	2	2	1	2	2
Camargo et al.	2	1	1	2	2	1	1	2	1

Table II. *The QUIN Tool assessment.*

Author	Blinding	Statistical Analysis	Presentation of Results	Total Score	Risk of Bias
Großner-Schreiber et al.	1	2	2	22	L
Zhang et al.	0	1	1	16	M
Ji et al.	0	2	2	18	L
Brunello et al.	0	1	1	19	L
Camargo et al.	0	2	1	16	M

Table III. *Risk of bias of the included studies, according to the ROBINS-I tool.*

Author	Bias due to confounding	Bias in the selection of participants for the study	Bias in classifying interventions	Bias due to deviations from intended interventions	Bias due to missing data	Bias to measuring outcomes	Bias in selecting reported results	The overall risk of biased judgment
Scarano et al. (2003)	Low	Low	Low	Moderate	Low	Low	Low	Low

The Cochrane Collaboration tool was used to assess the risk of bias for the only *in vivo* human study that showed a low risk of bias (Table III). The extracted data of the included studies were synthesized in Table IV.

Table IV. Extracted data from included studies.

Author (Year)	Study design	Coating	Control group	Bacteria used	Test procedure	Influence of coating on bacteria
Scarano et al. (2003)	<i>In vivo</i>	TiN coated implants	Uncoated grade 4 titanium implants	Percentage of surface covered by bacteria	Light microscope connected to a high-resolution video camera	The extent of bacterial coverage on test implants was significantly reduced compared to control implants (P<0.0001).
Großner-Schreiber et al. (2000)	<i>In vitro</i>	TiN	Pure titanium discs grade 2	S. Sanguis S. Mutans	Fluorescence microscope	The significantly lower number of bacteria on TiN-coated discs (p=0.0036)
Zhang et al. (2015)	<i>In vitro</i>	TiN	Commercial pure Ti grade 2	S. Mutans A. Viscosus P. Gingivalis	Scanning electron microscope (SEM), white light interferometer (WLI), and confocal laser scanning microscope (CLSM)	No difference in biofilm formation
Ji et al. (2015)	<i>In vitro</i>	TiN	Commercially pure titanium grade 2	S. Mutans P. Gingivalis	SEM	The number of <i>S. mutans</i> colonies on TiN decreased significantly (p<0.05)
Brunello et al. (2018)	<i>In vitro</i>	TiN	TiAl6V4, grade 5 disks	S. Sanguis S. Salivarius S. Mutans S. Sobrinus S. Oralis	Flow cytometry	The proportion of deceased bacteria was elevated in the biofilms cultivated on the disks coated with TiN.
Camargo et al. (2020)	<i>In vitro</i>	TiN	High pure titanium	P. Gingivalis	Fluorescence and SEM	Biofilm coverage was lower in TiN (24.22%) compared to uncoated samples (85.2%) p<0.05

DISCUSSION

TiN is a ceramic material with significant chemical and physical characteristics. These include a high level of hardness (measuring 2000 kg/mm²), an elevated decomposition temperature (2949 °C), modified stoichiometry, chemical stability at room temperature, excellent conductivity, and a distinctive golden-yellow color. Primarily employed as a coating, TiN enhances the properties of other materials. It contributes to near-zero hemolysis rates and exhibits exceptional biological traits, such as minimizing the release of cobalt-chromium-molybdenum ions (CoCrMo).

Previous research has revealed that TiN coatings effectively hinder the initial colonization of bacteria and the formation of biofilms. Significantly, this inhibition does not compromise the adhesion, proliferation, and differentiation of bone marrow mesenchymal cells, thereby preserving the material's biocompatibility. Studies have demonstrated that compared to polished titanium, the deposition of TiN coatings through Physical Vapor Deposition results in increased fibroblast numbers on zirconium nitride and TiN surfaces. It is worth noting that surface roughness can facilitate bacterial adhesion, and to prevent plaque formation, the roughness average (RA) value should not exceed 0.2 µm to maintain a stable soft tissue seal around the abutment (27, 28). In light of this, the TiN coating is generally below this threshold, with documented Ra values of 0.159 ±0.040 µm and 0.217 ±0.025 µm assessed by confocal microscopy and white light interferometry (29).

TiN/ZrN film coatings have also been investigated for their potential to improve the surface properties of pure titanium, increasing wear resistance and abrasive hardness. Thus, the primary objective of this review was to establish the state of the art in the literature regarding the antibacterial activity and suppression of bacterial growth by TiN hard coating materials. However, the number of clinical trials published in peer-reviewed journals using TiN as a coating for implant abutments is still limited, preventing a comprehensive systematic review of clinical studies (29-31).

Therefore, our review primarily focused on five *in vitro* studies and only one human trial. This limited scope should be considered a limitation of this systematic review. Nevertheless, the antibacterial effect of TiN is summarized in Table IV. All included studies compared the antibacterial activity of TiN coating versus pure titanium using different bacteria and laboratory methods (32-34).

The only *in vivo* study included in this review, conducted by Scarano et al., examined early bacterial colonization of TiN-coated implant abutments. After 24 h, the test group (TiN-coated implants) showed no bacterial or salivary proteins in widely distributed zones, with only small colonies of a few cocci found in other areas. The bacterial coverage on TiN-coated implants was found to be $13.1\% \pm 2.01\%$. In contrast, the control group, consisting of uncoated implants, displayed plaque containing a small number of cocci and a higher proportion of rod-shaped and filamentous-shaped bacteria. Additionally, a significant portion of the surface was covered by salivary proteins. The bacterial coverage on the control implants was measured to be $21.3\% \pm 1.9\%$. The authors concluded that the extent of bacterial coverage on TiN-coated implants was significantly lower compared to the control implants ($P=0.0001$) (34). It is important to note that these findings were attributed to the distinct chemical and physical composition of the implant surface rather than differences in surface roughness, as the roughness was similar in both the test and control implants.

In their study, Grossner-Schreiber et al. investigated the effects of TiN coatings on bacterial adhesion in comparison to control surfaces with equivalent roughness. They specifically examined the adhesion of *Streptococcus mutans* and *Streptococcus Sanguis*. The findings revealed a significant decrease in bacterial colonies on TiN-coated surfaces (25).

Our study used hard coatings (TiTiN and Ti-ZrN) to examine their impact on plaque accumulation. These coatings effectively masked the highly reactive titanium surface underneath, regardless of the surface roughness. Previous research has suggested that physical modifications like hard coatings could influence bacterial adherence. Coating the metal components of partial dentures with TiN was found to reduce plaque formation. Notably, there was a greater reduction in *S. sanguis* than *S. mutans* due to the former's more hydrophobic surface, which exhibited a stronger affinity for the TiN coating film.

TiN coating for the implant portion in contact with soft tissue can potentially reduce plaque formation and mucosal inflammation (25, 26, 34-36). Zhang et al. (35) found no difference in biofilm formation between TiN-coated and uncoated disks after 14 days of incubation when examining the effects of *S. mutans*, *A. viscosus*, and *P. gingivalis*. Ji et al. (26), evaluated bacterial adhesion and osteoblast-like cell viability, focusing on *S. mutans*, which is correlated with bacterial adhesion to implant surfaces in the human oral cavity, and *P. Gingivalis*, which stimulates toxin production and inflammation associated with peri-implantitis. They reported a significant reduction in the number of *S. mutans* colonies on TiN-coated surfaces compared to polished titanium ($P<0.05$). However, no difference in bacterial colony counts was observed between the two surfaces for *P. gingivalis*.

Brunello et al. (36), investigated the antibacterial activity of TiN-coated machined titanium compared to uncoated titanium surfaces against five different bacterial strains (*Streptococcus salivarius*, *S. sanguinis*, *S. mutans*, *S. sobrinus*, and *S. oralis*) (35). The percentage of dead bacteria was calculated, and they found a higher percentage of dead bacteria on TiN-coated disks compared to uncoated samples. For example, the percentage of dead *S. oralis* on the TiN-treated disks was $51.84\% \pm 3.73\%$ ($P<0.001$). Similar results were found for the other bacterial strains. The authors concluded that TiN-coated titanium exhibited antibacterial activity against several species associated with peri-implant infections.

In another study, Camargo et al. (37), tested the antibacterial activity of TiN-coated titanium disks compared to uncoated titanium against *P. gingivalis*. They observed a significant reduction in the number of *P. gingivalis* on TiN-coated disks (24.22%) compared to uncoated samples (85.2%, $p<0.05$) (37). Moreover, it has recently been reported that *Streptococcus gordonii* is an early bacterial colonizer and is essential for the initial colonization of abutments and tooth surfaces by other bacterial species. Its growth *in vitro* is significantly reduced on untreated titanium NiTi surfaces.

To summarize, the findings of this systematic review suggest that TiN-coated implants and abutments can effectively reduce mucositis and peri-implant inflammation. The TiN coating demonstrates a remarkable decrease in bacterial adherence, reducing plaque formation and potentially improving the long-term stability of the implant. However, it is important to note that further clinical trials are needed to validate these findings and explore the clinical effectiveness of TiN-coated implants.

CONCLUSIONS

To the best of the authors' knowledge, the first review on TiN coatings in clinical dentistry was published in 1992 based on their biocompatibility, mechanical properties, and corrosion (10). This systematic review demonstrated how TiN-coated implants and abutments could effectively reduce the initial biofilm formation involved in mucositis,

improving implant long-term stability due to the strong influence related to the TiN bio-corrosion activity of dental implant surface.

The main limitation of this study is that only one human study was included in this systematic review; further clinical investigations need to be conducted.

REFERENCES

1. Adell R, Lekholm U, Rockler B, Branemark PI. A 15-year study of osseointegrated implants in the treatment of the edentulous jaw. *Int J Oral Surg.* 1981;10(6):387-416. doi:https://doi.org/10.1016/s0300-9785(81)80077-4
2. Malchiodi L, Scarano A, Quaranta M, Piattelli A. Rigid fixation using titanium mesh in edentulous ridge expansion for horizontal ridge augmentation in the maxilla. *Int J Oral Maxillofac Implants.* 1998;13(5):701-705.
3. Abrahamsson I, Berglundh T, Wennstrom J, Lindhe J. The peri-implant hard and soft tissues at different implant systems. A comparative study in the dog. *Clin Oral Implants Res.* 1996;7(3):212-219. doi:https://doi.org/10.1034/j.1600-0501.1996.070303.x
4. Abrahamsson I, Zitzmann NU, Berglundh T, Linder E, Wennerberg A, Lindhe J. The mucosal attachment to titanium implants with different surface characteristics: an experimental study in dogs. *J Clin Periodontol.* 2002;29(5):448-455. doi:https://doi.org/10.1034/j.1600-051x.2002.290510.x
5. Scarano A, Khater AGA, Gehrke SA, et al. Current Status of Peri-Implant Diseases: A Clinical Review for Evidence-Based Decision Making. *J Funct Biomater.* 2023;14(4):doi:https://doi.org/10.3390/jfb14040210
6. Derks J, Tomasi C. Peri-implant health and disease. A systematic review of current epidemiology. *J Clin Periodontol.* 2015;42 Suppl 16(S158-171. doi:https://doi.org/10.1111/jcpe.12334
7. Guo T, Gulati K, Arora H, Han P, Fournier B, Ivanovski S. Race to invade: Understanding soft tissue integration at the transmucosal region of titanium dental implants. *Dent Mater.* 2021;37(5):816-831. doi:https://doi.org/10.1016/j.dental.2021.02.005
8. Lindhe J, Meyle J, Group DoEWoP. Peri-implant diseases: Consensus Report of the Sixth European Workshop on Periodontology. *J Clin Periodontol.* 2008;35(8 Suppl):282-285. doi:https://doi.org/10.1111/j.1600-051X.2008.01283.x
9. Berglundh T, Persson L, Klinge B. A systematic review of the incidence of biological and technical complications in implant dentistry reported in prospective longitudinal studies of at least 5 years. *J Clin Periodontol.* 2002;29 Suppl 3(197-212; discussion 232-193. doi:https://doi.org/10.1034/j.1600-051x.29.s3.12.x
10. Ong ES, Newman HN, Wilson M, Bulman JS. The occurrence of periodontitis-related microorganisms in relation to titanium implants. *J Periodontol.* 1992;63(3):200-205. doi:https://doi.org/10.1902/jop.1992.63.3.200
11. Scarano A, Cholakis AK, Piattelli A. Histologic Evaluation of Sinus Grafting Materials After Peri-implantitis-Induced Failure: A Case Series. *Int J Oral Maxillofac Implants.* 2017;32(2):e69-e75. doi:https://doi.org/10.11607/jomi.5303
12. Lindhe J, Berglundh T, Ericsson I, Liljenberg B, Marinello C. Experimental breakdown of peri-implant and periodontal tissues. A study in the beagle dog. *Clin Oral Implants Res.* 1992;3(1):9-16. doi:https://doi.org/10.1034/j.1600-0501.1992.030102.x
13. Scarano A, de Oliveira PS, Leo L, Festa F, Carinci F, Lorusso F. Evaluation of a new antibacterial coating of the internal chamber of an implant via real-time measurement of Volatile Organic Compounds (VOCs). *Front Biosci (Elite Ed).* 2021;13(2):216-225. doi:https://doi.org/10.52586/E879
14. Scarano A, Piattelli A, Polimeni A, Di Iorio D, Carinci F. Bacterial adhesion on commercially pure titanium and anatase-coated titanium healing screws: an *in vivo* human study. *J Periodontol.* 2010;81(10):1466-1471. doi:https://doi.org/10.1902/jop.2010.100061
15. Mezger PR, Creugers NH. Titanium nitride coatings in clinical dentistry. *J Dent.* 1992;20(6):342-344. doi:https://doi.org/10.1016/0300-5712(92)90021-4
16. Pappas MJ, Makris G, Buechel FF. Titanium nitride ceramic film against polyethylene. A 48 million cycle wear test. *Clin Orthop Relat Res.* 1995;317):64-70.
17. Yenyol S, Bölükbaşı N, Bilir A, Çakır AF, Yenyol M, Ozdemir T. Relative Contributions of Surface Roughness and Crystalline Structure to the Biocompatibility of Titanium Nitride and Titanium Oxide Coatings Deposited by PVD and TPS Coatings. In: *ISRN Biomaterials* 2013. pp. e783873.
18. Wu S, Xu J, Zou L, et al. Long-lasting renewable antibacterial porous polymeric coatings enable titanium biomaterials to prevent and treat peri-implant infection. *Nat Commun.* 2021;12(1):3303. doi:https://doi.org/10.1038/s41467-021-23069-0
19. Renvert S, Persson GR, Pirih FQ, Camargo PM. Peri-implant health, peri-implant mucositis, and peri-implantitis: Case definitions and diagnostic considerations. *J Periodontol.* 2018;89 Suppl 1(S304-S312. doi:https://doi.org/10.1002/JPER.17-0588
20. Sitek R, Kamiński J, Adamczyk-Cieślak B, et al. Effect of Plasma Nitriding on Structure and Properties of Titanium Grade 2 Produced by Direct Metal Laser Sintering. *Metallogr Microstruct Anal.* 2022;11(6):852-863.

21. Shamseer L, Moher D, Clarke M, et al. Preferred reporting items for systematic review and meta-analysis protocols (PRISMA-P) 2015: elaboration and explanation. *BMJ*. 2015;350(g7647). doi:<https://doi.org/10.1136/bmj.g7647>
22. Sterne JA, Hernan MA, Reeves BC, et al. ROBINS-I: a tool for assessing risk of bias in non-randomised studies of interventions. *BMJ*. 2016;355(i4919). doi:<https://doi.org/10.1136/bmj.i4919>
23. Sheth VH, Shah NP, Jain R, Bhanushali N, Bhatnagar V. Development and validation of a risk-of-bias tool for assessing *in vitro* studies conducted in dentistry: The QUIN. *J Prosthet Dent*. 2022;doi:<https://doi.org/10.1016/j.prosdent.2022.05.019>
24. Tran L, Tam DNH, Elshafay A, Dang T, Hirayama K, Huy NT. Quality assessment tools used in systematic reviews of *in vitro* studies: A systematic review. *BMC Medical Research Methodology*. 2021 21(1):
25. Grossner-Schreiber B, Griepentrog M, Hausteiner I, et al. Plaque formation on surface modified dental implants. An *in vitro* study. *Clin Oral Implants Res*. 2001;12(6):543-551. doi:<https://doi.org/10.1034/j.1600-0501.2001.120601.x>
26. Ji MK, Park SW, Lee K, et al. Evaluation of antibacterial activity and osteoblast-like cell viability of TiN, ZrN and (Ti1-xZrx)N coating on titanium. *J Adv Prosthodont*. 2015;7(2):166-171. doi:<https://doi.org/10.4047/jap.2015.7.2.166>
27. Del Castillo R, Chochlidakis K, Galindo-Moreno P, Ercoli C. Titanium Nitride Coated Implant Abutments: From Technical Aspects And Soft tissue Biocompatibility to Clinical Applications. A Literature Review. *J Prosthodont*. 2022;31(7):571-578. doi:<https://doi.org/10.1111/jopr.13446>
28. Prachar P, Bartakova S, Brezina V, Cvrcek L, Vanek J. Cytocompatibility of implants coated with titanium nitride and zirconium nitride. *Bratisl Lek Listy*. 2015;116(3):154-156. doi:https://doi.org/10.4149/bl_2015_031
29. Yeo IL. Modifications of Dental Implant Surfaces at the Micro- and Nano-Level for Enhanced Osseointegration. *Materials (Basel)*. 2019;13(1):doi:<https://doi.org/10.3390/ma13010089>
30. Durual S, Pernet F, Rieder P, Mekki M, Cattani-Lorente M, Wiskott HW. Titanium nitride oxide coating on rough titanium stimulates the proliferation of human primary osteoblasts. *Clin Oral Implants Res*. 2011;22(5):552-559. doi:<https://doi.org/10.1111/j.1600-0501.2010.02033.x>
31. Zhurakivska K, Ciacci N, Troiano G, et al. Nitride-Coated and Anodic-Oxidized Titanium Promote a Higher Fibroblast and Reduced Streptococcus gordonii Proliferation Compared to the Uncoated Titanium. *Prosthesis* 2020;2(4):333-339.
32. Miyazaki T, Mitamura H, Miyoshi S, Soejima K, Aizawa Y, Ogawa S. Autonomic and antiarrhythmic drug modulation of ST segment elevation in patients with Brugada syndrome. *J Am Coll Cardiol*. 1996;27(5):1061-1070. doi:[https://doi.org/10.1016/0735-1097\(95\)00613-3](https://doi.org/10.1016/0735-1097(95)00613-3)
33. Alsabeeha NH, Swain MV, Payne AG. Clinical performance and material properties of single-implant overdenture attachment systems. *Int J Prosthodont*. 2011;24(3):247-254.
34. Scarano A, Piattelli M, Vrespa G, Caputi S, Piattelli A. Bacterial adhesion on titanium nitride-coated and uncoated implants: an *in vivo* human study. *J Oral Implantol*. 2003;29(2):80-85. doi:[https://doi.org/10.1563/1548-1336\(2003\)029<0080:BAOTNA>2.3.CO;2](https://doi.org/10.1563/1548-1336(2003)029<0080:BAOTNA>2.3.CO;2)
35. Zhang Y, Zheng Y, Li Y, et al. Tantalum Nitride-Decorated Titanium with Enhanced Resistance to Microbiologically Induced Corrosion and Mechanical Property for Dental Application. *PLoS One*. 2015;10(6):e0130774. doi:<https://doi.org/10.1371/journal.pone.0130774>
36. Brunello G, Brun P, Gardin C, et al. Biocompatibility and antibacterial properties of zirconium nitride coating on titanium abutments: An *in vitro* study. *PLoS One*. 2018;13(6):e0199591. doi:<https://doi.org/10.1371/journal.pone.0199591>
37. Camargo SEA, Roy T, Xia X, et al. Novel Coatings to Minimize Corrosion of Titanium in Oral Biofilm. *Materials (Basel)*. 2021;14(2):doi:<https://doi.org/10.3390/ma14020342>



Review

PROTEIN ADSORPTION ON IMPLANT SURFACES TREATED WITH ATMOSPHERIC PLASMA

A. Scarano¹, S.A. Gehrke², M. Nicotra³, G. Di Palma⁵ and S.R. Tari¹

¹Department of Innovative Technologies in Medicine & Dentistry, University of Chieti-Pescara, Italy

²Department of Research, Bioface/PgO/UCAM, Montevideo, Uruguay, Department of Biotechnology, Universidad Católica de Murcia (UCAM), Murcia, Spain

⁴School of Biosciences and Veterinary Medicine, University of Camerino, Matelica, Italy

⁵University of Bari Italy

Correspondence to:

Antonio Scarano, DDS

University of Chieti-Pescara,

Via Dei Vestini 31,

66100 Chieti Italy

e-mail: ascarano@unich.it

ABSTRACT

The peri-implant bone density can determine long-term maintenance of the implant osteointegration. Thus, numerous types of research have been done to increase the quality and quantity of the peri-implant alveolar bone to improve implant survival and reduce the healing period. Many *in vivo* and *in vitro* studies have demonstrated that implant surfaces can influence cellular response and peri-implant bone. This work aimed to evaluate the role of the implant surface in protein absorption. Biochemical analyses were performed on 80 implants, 40 sandblasted/acid-etched (C = control), and 40 sandblasted/acid-etched and treated with cold plasma (T = test). Protein absorption in C and T surfaces was 2.15 ± 0.47 mg/ml and 2.66 ± 0.48 mg/ml, respectively. The difference in protein absorption between C and T implants was statistically significant ($***P < 0.001$). In conclusion, since the chemical composition, shape, and size of the C and T implants were similar, we can state that the cold plasma treatment determined the differences in protein adsorption observed.

KEYWORDS: *atmospheric plasma, cold plasma, dental implants, peri-implant bone, implant surface, protein adsorption*

INTRODUCTION

Implant rehabilitation is a successful treatment for most edentulous patients who can be successfully treated with titanium implants, allowing predictable clinical results. The long-term maintenance of implant osseointegration is also influenced by peri-implant bone contact and density (1, 2). For this reason, a great deal of research has been conducted

Received: 06 May 2024
Accepted: 03 June 2024

ISSN 2038-4106 print
ISSN 2975-044X online
Copyright © by BIOLIFE 2024

This publication and/or article is for individual use only and may not be further reproduced without written permission from the copyright holder. Unauthorized reproduction may result in financial and other penalties. Disclosure: All authors report no conflicts of interest relevant to this article.

to increase the quality and quantity of peri-implant bone to improve implant survival and reduce bone healing time so that implants can be loaded immediately or early (3). The implant surface can be treated with a chemical or physical agent to increase roughness. These treatments aim to increase undifferentiated mesenchymal cells and blood elements that induce bone formation at an early stage of osseointegration (4). Surface roughness can be produced by sandblasting, acid-etching, PVD (Physical Vapour Deposition) coating, plasma spray, or nano-coating (5). Surface roughness is one factor in determining the long-term prognosis of implants (6). Surface chemistry is also a factor influencing cellular response. Dental implant placement triggers a series of cellular and molecular events that generally lead to bone healing, and these mechanisms are very similar to those occurring in a wound or bone fracture.

Cytokines, released following surgical wounding, induce the proliferation and differentiation of preosteoblasts into osteoblasts simultaneously with the differentiation of periosteal and endosteal cells. Thus begins the production of osteoid matrix and subsequent mineralization with the formation of bone in contact with the implant and subsequent remodeling according to load (7). Peri-implant bone healing is, therefore, a complex phenomenon involving cell differentiation, migration, proliferation, protein synthesis, osteoid matrix deposition, and subsequent mineralization. All these phenomena can be influenced by hormones and local factors such as the chemical or roughness of the implant surface (8). One way to influence cellular events is to treat surfaces with cold atmospheric plasma (9). Sandblasting, oxidation and ultraviolet irradiation, alkali treatment, acid etching, calcium phosphate deposition, and cold plasma are surface treatments that can promote initial osteogenesis by increasing bone density in contact with the implant surface (10). Plasma represents the fourth stage of the matter and is a neutral ionized gas with high potential energy. It contains particles such as electrons, photons, atoms, positive and negative ions, free radicals, and excited and non-excited molecules used in many medical fields (11). Treatment of the implant with atmospheric plasma effectively improves hydrophilicity and promotes the attachment of bone marrow mesenchymal stem cells without changing the surface morphology of the metal (12). Osteoblast differentiation would be favored by cold plasma treatment that enhances osteoblastic proliferation, leading to increased production of peri-implant alkaline phosphatase by osteoblasts (13). The aim of this study is to evaluate the effect of surface treatment with cold plasma on protein absorption.

MATERIALS AND METHODS

Biochemical evaluations

For this type of evaluation, 80 threaded sandblasted/acid-etched implants surfaces screw-shaped implants (Isomed, DUE CARRARE, Padova, Italy) were used, 40 of which were control (C) and 40 with an atmospheric plasma-treated surface (T). The C and T implants were immersed for 15 seconds in a protein solution of bovine serum albumin at 100 mg/ml. This solution was prepared using bovine serum albumin powder produced by SIGMA (code A3294). Protein adsorption on the implant surface was determined by two methods:

1. readings at 280 nm of the protein solutions extracted from the dental implants using the spectrophotometer (Hewlett Packard mod. 8453);
2. evaluation using a SIGMA protein determination kit.

Statistical analysis

Data were analyzed using GraphPad Prism 9 software (GraphPad Software, Inc., La Jolla, CA, USA). All data are presented as the mean \pm standard deviation (SD) and were first checked for normality using the D'Agostino-Pearson and Shapiro-Wilk normality test. Differences in protein uptake between the C and T implants were analyzed using a Mann-Whitney test. A $*P < 0.05$ was considered significant.

RESULTS

A significant increase in protein uptake on atmospheric plasma-treated surfaces concerning the control, from 2.15 ± 0.47 mg/ml to 2.66 ± 0.48 mg/ml ($***P < 0.001$), was observed (Fig. 1, 2).

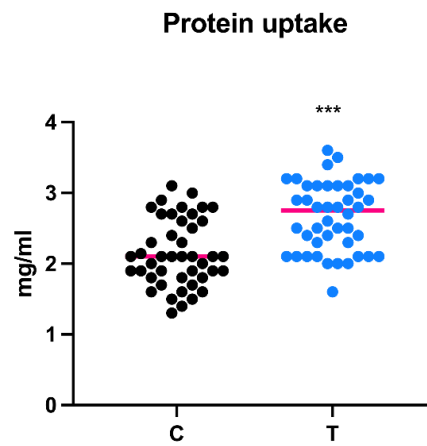


Fig. 1. Graphical representation of the protein uptake on the control and atmospheric plasma-treated surfaces ($***P < 0.001$).




Fig. 2. Plasma treatment of an implant.

DISCUSSION

The results of this study show that implants treated with cold plasma absorb more protein. Bovine serum albumin (BSA) is a globular blood plasma protein that transports various compounds and is often used as a reference protein for adsorption experiments (14). Surface roughness and composition are the most important factors influencing cell activity. Titanium used during *in vivo* implantation needs the immediate adhesion of body fluids and protein molecules in the blood to continue the cell migration and proliferation via the protein-coated layer (15). Several studies show that it is possible to absorb proteins on the surface of the biomaterial to increase the amount of bone around the biomaterial, thus reducing healing time. In the present study, we treated the surface of the implant with atmospheric plasma to make it more absorbent towards plasma proteins. Our results show that cold plasma-treated surfaces absorb more albumin *in vitro* and *in vivo*, which can promote better bone healing with increased bone-titanium contact. Increased protein uptake by surfaces treated with cold plasma could play a key role in bone regeneration by increasing the concentration of the implant of proteins involved in bone neoformation processes (16). It is known that modifying the geometry, microporosity, and layer of titanium dioxide makes it possible to make it more osteoconductive or even osteoinductive. The cold plasma-treated surface absorbs more BMP (morphogenetic), OP (osteogenetic), fibronectin, and osteopontin proteins released at the implant site after surgery. Surface wettability, therefore, plays a key role in protein adsorption; it is a key feature in achieving good binding between proteins dispersed in the extracellular matrix and the biomaterial (17). Once surgically inserted into the bone, the titanium first comes into contact with blood proteins, which form a clot around its surface; the

proteins tend to adsorb onto the implant's surface, creating a macromolecular layer and influencing the behavior of the surrounding cells.

Albumin and fibrinogen are the first proteins to adhere to and adsorb the implant surface (18, 19). Cold Plasma treatment was used to increase surface energy and wettability without changing the surface characteristics to prove protein adsorption and promote the biological behavior of the cells (20). Cold plasma treatment was used before surgery to reduce carbon contamination, thus improving osseointegration and reducing the time of healing procedures (21).

It can be stated that, from the values that emerged from our experimentation, the T-surfaces show a higher uptake of bovine serum albumin than the C surfaces. In conclusion, since the chemical composition, shape, and size of the C and T implants are similar, the differences in protein adsorption observed are determined by the cold plasma treatment.

Acknowledgments

We thank Dr. Francesco Tricca for his technical collaboration.

REFERENCES

1. Diz P, Scully C, Sanz M. Dental implants in the medically compromised patient. *J Dent.* 2013;41(3):195-206. doi:https://doi.org/10.1016/j.jdent.2012.12.008
2. Greco G, Borgia R, Casto C. Occlusal-vertical rebalancing for implant prosthetic planning: technical considerations. *European Journal of Musculoskeletal Diseases* 2023;12((1)-(SPECIAL ISSUE 1)):13-18.
3. Lorusso F, Ascani G, Inchingolo F, Tari SR, Bugea C, Scarano A. The bone-implant contact and osseointegration of different implant surface treatment: the findings from a systematic literature review. *European Journal of Musculoskeletal Diseases* 2023;12(3):95-117.
4. Gehrke SA, Scarano A, Cortellari GC, Fernandes GVO, Mesquita AMM, Bianchini MA. Marginal Bone Level and Biomechanical Behavior of Titanium-Indexed Abutment Base of Conical Connection Used for Single Ceramic Crowns on Morse-Taper Implant: A Clinical Retrospective Study. *J Funct Biomater.* 2023;14(3):doi:https://doi.org/10.3390/jfb14030128
5. Pellegrini G, Francetti L, Barbaro B, Del Fabbro M. Novel surfaces and osseointegration in implant dentistry. *J Investig Clin Dent.* 2018;9(4):e12349. doi:https://doi.org/10.1111/jicd.12349
6. Alterman M, Jensen OT, Glick PL, Mazor D, Casap N. Dental implant risk factors for peri-implant disease: a narrative review. *Front Oral Maxillofac Med.* 2023
7. Zhi Q, Zhang Y, Wei J, Lv X, Qiao S, Lai H. Cell Responses to Calcium- and Protein-Conditioned Titanium: An In Vitro Study. *J Funct Biomater.* 2023;14(5):doi:https://doi.org/10.3390/jfb14050253
8. Silva IRD, Barreto A, Seixas RS, et al. Novel Strategy for Surface Modification of Titanium Implants towards the Improvement of Osseointegration Property and Antibiotic Local Delivery. *Materials (Basel).* 2023;16(7):doi:https://doi.org/10.3390/ma16072755
9. Bencina M, Rawat N, Lakota K, Sodin-Semrl S, Igljic A, Junkar I. Bio-Performance of Hydrothermally and Plasma-Treated Titanium: The New Generation of Vascular Stents. *Int J Mol Sci.* 2021;22(21):doi:https://doi.org/10.3390/ijms222111858
10. Fujiwara S, Botticelli D, Kaneko N, Urbizo Velez J, Tumedei M, Bengazi F. Effect of low-speed drilling without irrigation on osseointegration: an experimental study in dogs. *Oral Maxillofac Surg.* 2022;26(4):595-601. doi:https://doi.org/10.1007/s10006-021-01023-0
11. Scarano A, Di Giulio R, Gehrke SA, Tagariello G, Romano F, Lorusso F. Atmospheric Plasma Lingual Frenectomy Followed by Post Operative Tongue Exercises: A Case Series. *Children (Basel).* 2023;10(1):doi:https://doi.org/10.3390/children10010105
12. Ujino D, Nishizaki H, Higuchi S, Komasa S, Okazaki J. Effect of Plasma Treatment of Titanium Surface on Biocompatibility. *Appl Sci.* 2019;11(
13. Przekora A, Pawlat J, Terebun P, Duday D, Canal C, Hermans S. The effect of low temperature atmospheric nitrogen plasma on MC3T3-E1 preosteoblast proliferation and differentiation in vitro. *J Phys Appl Phys.* 2019;52(27):
14. Park KH, Song HJ, Park YJ. Albumin adsorption on microwave-treated titanium dioxide for dental implant materials. *Colloids Surf B Biointerfaces.* 2021;208(112124). doi:https://doi.org/10.1016/j.colsurfb.2021.112124
15. Jenney CR, Anderson JM. Adsorbed serum proteins responsible for surface dependent human macrophage behavior. *J Biomed Mater Res.* 2000;49(4):435-447. doi:https://doi.org/10.1002/(sici)1097-4636(20000315)49:4<435::aid-jbm2>3.0.co;2-y
16. Park KH, Song HJ, Park YJ. Microwave Treatment of Calcium Phosphate/Titanium Dioxide Composite to Improve Protein Adsorption. *Materials (Basel).* 2022;15(14):doi:https://doi.org/10.3390/ma15144773
17. Scarano A, Tari Rexhep S, Leo L, Lorusso F. Wettability of implant surfaces: Blood vs autologous platelet liquid (APL). *J Mech Behav Biomed Mater.* 2022;126(104773). doi:https://doi.org/10.1016/j.jmbbm.2021.104773
18. Klinger A, Steinberg D, Kohavi D, Sela MN. Mechanism of adsorption of human albumin to titanium in vitro. *J Biomed Mater Res.* 1997;36(3):387-392. doi:https://doi.org/10.1002/(sici)1097-4636(19970905)36:3<387::aid-jbm13>3.0.co;2-b

19. Kanagaraja S, Lundstrom I, Nygren H, Tengvall P. Platelet binding and protein adsorption to titanium and gold after short time exposure to heparinized plasma and whole blood. *Biomaterials*. 1996;17(23):2225-2232. doi:[https://doi.org/10.1016/0142-9612\(95\)00311-8](https://doi.org/10.1016/0142-9612(95)00311-8)
20. Duske K, Jablonowski L, Koban I, et al. Cold atmospheric plasma in combination with mechanical treatment improves osteoblast growth on biofilm covered titanium discs. *Biomaterials*. 2015;52(327-334). doi:<https://doi.org/10.1016/j.biomaterials.2015.02.035>
21. Henningsen A, Smeets R, Hartjen P, et al. Photofunctionalization and non-thermal plasma activation of titanium surfaces. *Clin Oral Investig*. 2018;22(2):1045-1054. doi:<https://doi.org/10.1007/s00784-017-2186-z>



Review

SURFACE ELECTROMYOGRAPHY AS AN EVALUATION TOOL FOR BITE THERAPY IN PATIENTS WITH CRANIO-MANDIBULAR PAIN: A SYSTEMATIC REVIEW

A. Mancini^{1†}, F. Inchingolo^{1†}, A. M. Inchingolo^{1†}, F. Cardarelli¹, F. Piras¹, L. Ferrante¹, A. Palermo², A. Scarano^{3*}, S. R. Tari³, A. D. Inchingolo¹ and G. Dipalma¹

¹Department of Interdisciplinary Medicine, University of Bari “Aldo Moro”, Bari, Italy;

²College of Medicine and Dentistry, Birmingham, UK;

³Department of Innovative Technologies in Medicine and Dentistry, University of Chieti–Pescara, Chieti, Italy

*Correspondence to:

Antonio Scarano, DDS

Department of Innovative Technologies in Medicine and Dentistry,

University of Chieti-Pescara,

Via Dei Vestini 31,

66100 Chieti Italy

e-mail: ascarano@unich.it

ABSTRACT

Temporomandibular disorders (TMD) represent a complex and multifaceted group of conditions affecting the temporomandibular joint and associated muscles, resulting in a range of symptoms and impaired quality of life. Surface Electromyography (sEMG) has emerged as a non-invasive tool for assessing masticatory muscle function and evaluating the efficacy of bite therapy in TMD patients. It provides valuable insights into muscle activity, activation patterns, and neuromuscular dysfunctions associated with TMD. The purpose of this article is to review bite therapy, which is aimed at improving the occlusal relationship and is a rational approach to managing TMD by reducing abnormal occlusal forces and muscle hyperactivity. A literature search from 1 January 2002 through 18 July 2023 of PubMed, Scopus, and Web of Science databases was conducted analyzing the rationale for bite therapy in TMD using these terms: “pain” AND (“temporomandibular disorder*” OR “temporomandibular dysfunction*”) AND “surface electromyography” AND “masticatory muscle activity” AND “splint therapy”. At the end of the selection process, 38 articles resulted. sEMG is a non-invasive tool for assessing masticatory muscle function in cranio-mandibular pain. It enhances bite therapy evaluation and patient engagement through biofeedback. Further research is needed to optimize TMD management and explore additional treatment options.

KEYWORDS: *bite therapy, temporomandibular disorders, surface electromyography, occlusal splint, temporomandibular dysfunction, craniomandibular pain, occlusal relationship*

INTRODUCTION

Cranio-mandibular pain, or TMD, constitutes a group of conditions affecting the temporomandibular joint (TMJ) and associated muscles (1). TMD presents a broad spectrum of symptoms, including pain, joint sounds, muscle tenderness,

Received: 04 May 2024
Accepted: 07 June 2024

ISSN 2038-4106 print
ISSN 2975-044X online

Copyright © by BIOLIFE 2024

This publication and/or article is for individual use only and may not be further reproduced without written permission from the copyright holder. Unauthorized reproduction may result in financial and other penalties. Disclosure: All authors report no conflicts of interest relevant to this article.

limited jaw movement, and headaches (2). This debilitating condition affects a significant portion of the global population, leading to decreased quality of life, impaired masticatory function, and psychosocial disturbances (3).

As TMD has a multifactorial etiology, successful management demands a comprehensive approach that includes accurate diagnosis, targeted interventions, and careful evaluation of treatment outcomes (4). Surface Electromyography (sEMG) has emerged as a promising noninvasive tool for assessing masticatory muscle function and evaluating the efficacy of bite therapy in patients with craniomandibular pain (5).

Temporomandibular disorders: a complex and multifaceted condition

TMD encompasses a diverse group of conditions affecting the TMJ, masticatory muscles, and other structures in the craniofacial region (6). The prevalence of TMD varies across populations, with studies reporting rates ranging from 5% to 12% globally (7). Although the exact pathogenesis remains elusive, TMD is believed to result from the interplay of genetic, biomechanical, hormonal, psychosocial, and environmental factors (8).

Trauma to the jaw, parafunctional habits (e.g., clenching, bruxism), malocclusion, stress, and joint abnormalities are common predisposing factors for TMD (9). TMD's complex and multifaceted nature makes it challenging to diagnose and manage effectively. Consequently, an accurate assessment of the disorder, including the evaluation of masticatory muscle function, is critical for devising appropriate treatment strategies (10).

Surface electromyography: fundamentals and applications in dentistry

sEMG is a non-invasive diagnostic technique that measures the electrical activity of skeletal muscles through surface electrodes placed on the skin above the targeted muscle groups (11). By capturing action potentials generated by motor units during muscle contractions, sEMG provides valuable insights into muscle function, activation patterns, and timing (12). This technology has found extensive applications in various fields, including rehabilitation, sports science, ergonomics, and dentistry (13).

In the dental context, sEMG has gained recognition as a reliable and objective tool for assessing masticatory muscle activity and function (Fig. 1) (14). By analyzing muscle activity during rest, maximal clenching, chewing, and other jaw movements, clinicians can gain essential information about muscle imbalances, asymmetries, and potential neuromuscular dysfunctions associated with TMD (15).

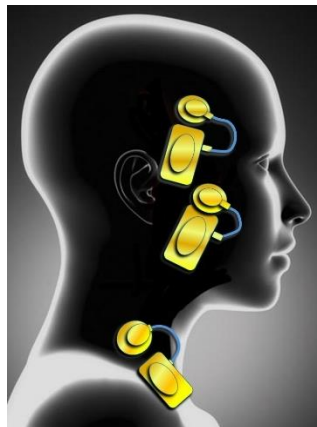


Fig. 1. Placement of the electrodes for surveying the function of the main masticatory muscles.

The rationale for bite therapy in TMD management

Bite therapy, also known as occlusal therapy (Fig. 2), is a treatment approach to improve the occlusal relationship and balance the occlusal system (16). The underlying rationale for bite therapy in TMD management is to minimize abnormal occlusal forces, reduce masticatory muscle hyperactivity, eliminate parafunctional habits, and enhance joint stability (17).

The ultimate goal is to alleviate pain, restore normal jaw function, and improve the patient's overall quality of life (18). Various bite therapy modalities exist, ranging from occlusal adjustments and splint therapy to orthodontic interventions (19). Selecting the most appropriate treatment approach depends on factors such as the patient's clinical presentation, occlusal findings, and the severity of TMD symptoms (20).

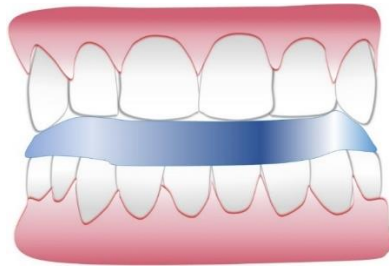

Fig. 2. Bite therapy to rebalance occlusal forces and relationships.

sEMG as a diagnostic tool for cranio-mandibular pain

sEMG is particularly advantageous in evaluating cranio-mandibular pain because it provides objective, real-time data on masticatory muscle activity. By comparing muscle activation patterns between symptomatic and asymptomatic sides, sEMG helps clinicians identify specific muscle imbalances or asymmetries that may contribute to TMD symptoms. During sEMG assessment, the patient is instructed to perform a series of standardized tasks, such as clenching, biting on a force transducer, and chewing (21).

The data obtained from these tasks allow the clinician to quantify muscle activity, assess coordination, and determine whether excessive muscle activity is present during various functional tasks. Furthermore, sEMG can be used to evaluate the effects of bite therapy on masticatory muscle function. By measuring changes in muscle activity before and after treatment, clinicians can objectively assess the treatment's effectiveness and adjust the therapeutic approach as needed.

sEMG in evaluating the efficacy of bite therapy

The use of sEMG in evaluating the efficacy of bite therapy in patients with cranio-mandibular pain offers several advantages. Firstly, sEMG objectively assesses muscle function, which can complement subjective patient-reported outcomes. Quantitative measurements of muscle activity before and after bite therapy can help clinicians track improvements and make data-driven decisions in treatment planning (22). Secondly, sEMG can aid in identifying potential muscle imbalances and asymmetries that may contribute to TMD symptoms.

By analyzing muscle activity during different tasks, such as chewing or clenching, clinicians can pinpoint areas of concern and tailor bite therapy to address these issues (23). Moreover, sEMG allows for real-time biofeedback, enabling patients to visualize their muscle activity and learn to modify their behaviors. This biofeedback mechanism encourages active patient participation, improving treatment compliance and outcomes (24).

The Role of sEMG in biofeedback and patient education

Beyond its diagnostic utility, sEMG offers significant benefits in terms of biofeedback and patient education (25–28). By visualizing their muscle activity in real-time, patients can better understand their condition and actively participate in their treatment (19). This biofeedback mechanism empowers patients to modify parafunctional habits, adopt healthier behaviors, and engage in self-management techniques, enhancing treatment outcomes.

MATERIALS AND METHODS

Protocol and registration

The PRISMA (Preferred Reporting Items for Systematic Reviews and Meta-Analyses) protocols were followed when conducting this review, and it was submitted to PROSPERO with a temporary number (n. 452358) (29).

Search processing

We searched PubMed, Scopus, Web of Science, and ScienceDirect with a constraint on English-language papers from 1 January 2002 through 18 July 2023 that matched our topic. The following Boolean keywords were utilized in the search strategy: “pain” AND (“temporomandibular disorder*” OR “temporomandibular dysfunction*”) AND “surface electromyography” AND “masticatory muscle activity” AND “splint therapy”. These terms were chosen because they best described the goal of our inquiry, which was to learn more about the electromyographic evaluation of the effectiveness of therapy on TMD using occlusal splints (OS).

Inclusion criteria

All appropriate trials were assessed by three reviewers using the following selected criteria: (A) only studies with human subjects; (B) open-access studies that other researchers can access for free; (C) scientific research evaluating the positive beneficial effects of OS in the treatment of TMD. The PICO model was developed in the following manner:

- population: human subjects with TMD. No restrictions on health status, sex, and age;
- intervention: OS;
- comparison: groups with different types of splints or other appliances;
- outcome: pre- and post- treatment with electromyographic evaluation.

Exclusion criteria

Exclusion criteria included articles in non-English languages, ineligible research design, ineligible outcome measure, and ineligible population, such as studies on TMD patients who did not have pain, studies on patients with congenital craniofacial deformities, case reports, reviews, and animal studies.

Data processing

Author differences over the article selection were discussed and resolved.

Article identification procedure

Two reviewers (F.I. and F.P.) completed the suitability evaluation separately. A manual search was also done to expand the pool of articles for full-text examination. Articles published in English that fit the inclusion requirements were considered, while duplicates and disqualified articles were labeled with the reason for exclusion.

Study Evaluation

The reviewers independently evaluated the article data using a special electronic form designed according to the following categories: authors, year of study, study model design, diagnostic criteria, patient age, study groups, participants, outcomes, and results.

RESULTS

A total of 1443 publications were discovered from the following databases: PubMed (537), Scopus (417), and Web of Science (489), producing 1125 articles after deleting duplicates (318). The analysis of the title and abstract resulted in the exclusion of 969 items. The remaining 156 papers were successfully retrieved and verified for eligibility by the writers. The process resulted in the elimination of 118 items for being off-topic. The examination comprises the final 38 articles for qualitative analysis (Fig. 3). The items included are schematized in Table I (6, 8-11, 13, 16, 17, 20, 22, 26, 30-47).

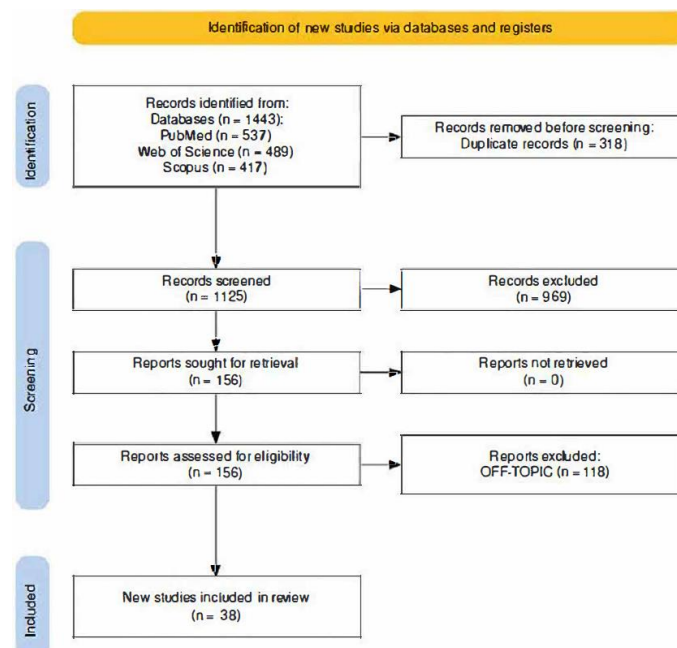


Fig. 3. PRISMA flowchart diagram of the inclusion process.

Table I. *Characteristics of the studies.*

Authors Years	Type of the study	Study groups	Materials and methods	Results
Ferrario et al. (2002) (30)	Clinical exam	Among the TMD, individuals with internal derangement type I were chosen.	EMG was done on all patients shortly before and after the splint was inserted, and results were compared using paired t-tests.	The splint lowered the electrical activity of the muscles studied, making it more balanced between the left and right sides and between the temporal (TA) and masseter muscles (MM).
Amorim et al. (2010) (31)	Cross-sectional study	Fifteen women	The effects of an OS on the electric activity of the MM were examined using sEMG in a group of people with sleep bruxism (SB), and the clinical aspects of SB were used to characterize it.	When MM was evaluated during mandible occlusion without clenching, decreased values were reported following splint wearing on both sides.
Botelho et al. (2010) (32)	Randomized controlled trial	Thirty people were studied, 15 of whom had TMD (TMD Group) and 15 were healthy (Control Group).	Each patient in the TMD Group received a durable OS constructed of 2 mm thick silicon that covered all teeth. The EMG was done both before and after the splint was installed.	The symmetry index values in the Control Group were greater than in the TMD Initial Group and similar to those in the TMD Group after the splint was installed. When compared to the Controls, the torque index values in the TMD Initial Group were greater. Impact values were lower than normal in the TMD Initial Group and were recovered once the splint was installed.
Cruz-Reyes et al. (2011) (33)	Randomized controlled trial	16 persons	Two groups of eight patients were assessed, each wearing the same occlusal splint for 7 to 9 weeks. Each patient underwent two EMG tests before applying the splint and during therapy.	While the drop in the experimental group may have been caused by a negative or decremental process of muscular organization to limit the recruitment of new motor units, the rise in muscle electrical activity in the control group may have resulted from a neuromuscular recovery process. Therefore, occlusal stability splints are preferred over soft OSs.
Nanda et al. (2011) (34)	Longitudinal study	10 patients	EMG activity of the anterior TA and MM was recorded bilaterally for patients whose vertical was restored using a centric stabilizing splint. Each subject's postural rest posture and maximal voluntary clenching were recorded before the commencement of treatment, immediately after the splint was placed, and at subsequent recall sessions, with and without the splint.	EMG activity in postural rest posture (PRP) and maximal voluntary clench (MVC) was reduced for both muscles until 1 month. In month 3, both with and without the splint, there was an increase in muscle activity near normality at PRP. At MVC in month 3, muscle activity without the splint dropped considerably compared to pretreatment values for the anterior TA and MM, but with the splint increased beyond pretreatment levels.

Daif et al. (2012) (35)	Randomized controlled trial	This research comprised forty individuals with TMD and myofascial pain.	The first group (A) received OS treatment for 6 months, while the second group (B) served as a control. A clinical evaluation and sEMG of the masticatory muscles were done at the start of the trial and again 6 months afterward. The data was statistically examined using the paired t-test.	The findings revealed that 85% of Group A either entirely recovered (35%) or clinically improved (50%), whereas only 20% of Group B improved spontaneously. After 6 months, the means of the electromyographic amplitude recordings (mV) of the monitored muscles in group A had reduced. However, the drop was statistically insignificant among the 15% of patients with no clinical changes ($p > 0.05$). In group B, the means of the muscle recordings (mV) on the left rose significantly, while those on the right fell somewhat.
Vieira e Silva et al. (2012) (36)	Randomized controlled trial	15 subjects with disc displacement and 15 asymptomatic subjects	EMG data was acquired and recorded on the day the splint was placed, one week later, and five weeks later.	Following therapy, significant changes in mouth opening and pain remission were seen. There were no statistically significant changes between the three sessions, with or without the splint. Except for total muscle activity, there were substantial differences between the TMD and control groups in all indices of muscular symmetry, activity, and torque.
Amorim et al. (2012) (37)	Clinical exam	15 women with SB and temporomandibular problems as a result of professional stress	sEMG was done on the right and left MM and TA muscles. EMG signals were obtained twice for each subject.	The parametric t-paired test evaluated root mean square (RMS) amplitude changes between pre and post-splint data for resting and maximal clenching effort.
Takahashi et al. (2013) (13)	Cross-sectional study	23 patients	To evaluate SB, portable EMG was used to detect MM activity while sleeping with stabilization splints (SS) or palatal splints (PS)	The SS group showed a significant decrease in the number of bruxism events per hour.
Fei-yu et al. (2013) (38)	Randomized controlled double-blind trial	Thirty-six patients took part in the trial. All Participants with myofascial TMD were divided into two groups of 18 each.	Clinical evaluations were conducted at the start of the trial and one month following therapy. MM's sEMG measurements were taken one month after treatment at the mandibular postural position (MPP) and maximal intercuspal contacting position (ICP).	It was revealed that 89% of Group A either completely recovered (39%) or improved clinically (50%), but just 22% of Group B improved spontaneously.
Lickteig et al. (2013) (39)	Longitudinal study	14 subjects with TMD	Before and after two weeks of therapy with an individually customized OS, pain rating, kinematic examinations of occlusal motions, and jaw muscle EMG were assessed at tooth functional magnetic resonance imaging (fMRI).	Patients' subjective pain ratings dropped throughout treatment, and condylar movement symmetry improved. EMG of the jaw muscles revealed more relaxed resting conditions and greater activity during maximum occlusion after treatment. During treatment, fMRI during occlusion revealed reduced activity in

				the right anterior insula and right cerebellum.
De Paula Gomes et al. (2014) (40)	Randomized clinical trial	Sixty people with severe TMD and SB were randomly assigned to one of four therapy groups.	Block randomization and sealed opaque envelopes were used to disguise the allocation. All groups underwent electromyographic examination of the MM and anterior TA muscles before and after therapy.	Prior to treatment, there were no statistically significant variations in median frequency across the groups, according to the inter-group analysis of variance. There were no statistically significant differences between groups.
Caria et al. (2014) (22)	Randomized controlled trial	Thirty police officers were chosen based on TMD Research Diagnostic Criteria and clinical tests. Volunteers (ten per group) were divided into three groups based on their OSs: group A was the control group, group B was the Michigan Occlusal Splint (MOS), and group C was the Planas Appliance (PA). The experimental groups were evaluated clinically for temporomandibular joint discomfort using a visual analog pain scale (VAPS).	Bilateral surface electromyographic activity of the anterior and posterior TA, MM, and suprahyoid muscles at rest and during clenching was recorded before and after four weeks of wearing Oss.	After utilizing both splints, the sensitivity of the left and right TA and MM diminished. Pain symptoms rose in group A (Control) while decreasing in group C.
Matsumoto et al. (2015) (41)	Randomized controlled trial	Twenty bruxers were randomly assigned to one of two groups: continuous or intermittent.	The researchers examined the amount of nocturnal MM electromyographic episodes, duration, and overall activity of SB.	The nocturnal MM electromyographic events and duration were significantly reduced in the continuous group immediately and one week after the stabilizer splint was applied. However, no reduction was seen two, three, or four weeks later. The number and duration of nocturnal MM electromyographic episodes were significantly reduced in the intermittent group immediately after and four weeks after the stabilizer splint was applied.
Trindade et al. (2015) (42)	Comparative study	Two groups of 11 bruxism patients were treated with either an OS paired with cognitive behavioral therapy or an OS alone.	Before and after therapy, sEMG of the MM and anterior TA muscles was conducted.	Except for the right anterior TA muscle in the group treated with an OS alone, the mean amplitude of activity of all muscles decreased following treatment. The anterior TA muscles have bigger mean amplitudes than the MM.
Giannakopoulos et al. (2018) (9)	Randomized controlled trial	45 patients	Sensorimotor training and traditional splint therapy were the two treatment groups. EMG activity was recorded at the initial session and three months afterward.	The first and last sessions' EMG activity under submaximal biting force were not substantially different. After the treatment period, EMG activity for the MM was roughly 20% higher during maximal biting in both groups. In contrast, only the sensorimotor training group

				showed a substantial increase in the TA muscle. Furthermore, sensorimotor training was substantially more difficult to utilize than the splint.
Castroflorio et al. (2018) (6)	Randomized controlled trial	Sixty patients with SB who needed orthodontic treatment were included in the trial and randomly allocated to one of three groups: 20 received clear aligners (CAT), 20 received an OS, and 20 received a placebo splint (PMS).	All groups were observed for 6 months, and SB was detected using portable electromyographic-electrocardiographic (EMG-ECG) equipment.	When compared to PMS, MOS individuals reduced MM contractions after 6 months of therapy but increased phasic contractions related to SB after 3 months of treatment and tonic contractions related to SB throughout the six months of treatment. When compared to PMS, CAT individuals had more phasic contractions due to SB throughout the first and third months of therapy. There were no significant variations in the SB index for any of the three groups at any period. Although MOS and CAT had varied effects on EMG signals during sleep, they did not affect the total SB score.
Rój et al. (2018) (20)	Longitudinal study	Forty edentulous individuals with TMD.	sEMG was used to evaluate the electromyographic activity of the TA muscle and MM. For 74 days, all patients wore acrylic OSS.	Patients who received combo treatment exhibited less TA muscle activity asymmetry.
Kobayashi et al. (2019) (43)	Randomized controlled trial	76 children	All participants will be subjected to a clinical assessment before and after treatments to assess muscle activity and salivary biomarkers. EMG of mastication, MM, and TA muscles will be used to confirm muscular activation and salivary biomarkers such as cortisol and dopamine levels will be measured.	Researchers are interested in photobiomodulation treatment since this noninvasive technology has shown excellent effects in muscle tissue disorders.
Lan et al. (2019) (26)	Comparative study	21 people with centric bruxism (CB) and 21 people with eccentric bruxism (ECB). Sixteen participants did not have bruxism.	EMG signals from the TA and superficial MM were recorded in various jaw positions and while eating. The parameters of EMG amplitude and chewing cycle duration were then examined.	The CB group had less muscular maximum motor units, with a more prominent MM. A higher proportion of muscle contractions were engaged for the same amount of chewing activity, and there was a longer chewing cycle. The ECB group had more TA maximal motor units and higher MM activity on the nonworking side while chewing unilaterally.
Ernst et al. (2020) (8)	Cross-sectional study	13 patients	fMRI of the depiction of occlusal motions on natural teeth and on an individually fitting mandibular splint was used to evaluate individuals with TMD and moderate pain intensity	Pain and anticipatory anterior insular activation are moderately reduced after three months of mandibular splint treatment.

			before, after 2 weeks, and after 12 weeks.	
Hara et al. (2020) (10)	Cross-sectional study	19 TMD patients	Patients wore the vibratory splint (VibS) or an OS for two weeks as a control. The outcome variables were sleep clenching (SC) frequency and pain, measured using a portable EMG detector analyzer.	After two weeks of usage, VibS encouraged a significant reduction, whereas acrylic OS increased SC frequency.
Deregibus et al. (2021) (44)	Randomized controlled trial	Forty adult patients had myofascial pain on at least one MM that had been present for at least three months. The patients were randomly divided into two groups: Group 1 had upper Michigan OS, and Group 2 received mandibular OS.	The following outcomes were measured at various points: myofascial pain by Visual Analog Scale (VAS), range of motion (ROM) of mandibular movements, and activity of the primary masticatory muscles by sEMG.	There were no significant intra-group variations in the outcome measures tested in both groups. Group 2 exhibited considerably greater correct lateral mandibular ROM at T2 and significantly greater left lateral mandibular ROM at T3. We discovered no statistically significant differences in any of the sEMG values.
Pita et al. (2021) (17)	Comparative study	20 asymptomatic subjects	EMG measurements were taken with and without the 3- and 6-mm splints, which recorded microvolt data (V).	Masticatory muscle electrical activity increased during tooth clenching compared to rest, with more activity in the MM. The electrical activity did not differ between splint thickness or males and females.
Lukic et al. (2021) (16)	Randomized controlled trial	10 subjects	A splint and an NTI-tss device were made separately and used randomly. In weeks 1, 4, and 7, electromyographic jaw muscle activity was measured for four consecutive nights with and without a splint. Participants noted splint comfort and side effects.	Muscle activation diminished only when using the NTL-tss device. Most patients favored the Michigan splint because of its higher wearing comfort.
He et al. (2021) (24)	Randomized controlled trial	46 patients with TMD and 34 controls	Twenty-three patients and 17 controls used a stabilizing splint. The remaining participants were monitored without any intervention. The EMG recordings and clinical assessments were repeated three months later.	Patients had greater baseline EMG values at rest and EMG value fluctuations following movements than controls. There was no difference in EMG results between patients and controls after therapy.
Inchingolo et al. (2022) (11)	Cross-sectional study	25 patients	Based on the electromyographic data, a therapy plan was developed to alleviate the symptoms of dysfunctional athletes. A follow-up was done one month after initiating therapy with an OS, and the outcomes were compared to the original data.	Patients had greater baseline EMG values at rest and EMG value fluctuations following movements than controls. There was no difference in EMG results between patients and controls after therapy.
Wiechens et al. (2022) (45)	Prospective clinical trial	A total of 29 individuals with myofascial pain were studied.	Patients were treated with Michigan splints that were administered nightly for three months. Patients were registered using an electronic ultrasonography	According to the qualitative evaluation, 24 of 29 patients improved in pain symptoms, with 17 experiencing total remission.

			instrument before (T1) and after three months of therapy (T2).	
Akat et al. (2023) (46)	Randomized controlled trial	There were 17 controls and 51 patients divided into three groups.	Each subgroup was allocated to wear a distinct OS (hard, soft, or semi-soft) for three months and was evaluated by ultrasonography and EMG before (BT) and after (AT).	EMG activity decreased with all three splint types, with the hard OS group showing the greatest reduction. Ultrasonographic measures of muscle length and thickness should be employed in conjunction with EMG to quantify muscle activity in bruxism patients.
Lei et al. (2023) (47)	Cross-sectional study	16 patients	Patients with an entire dentition and a stable occlusal connection who were reported to have nocturnal bruxism were chosen for the investigation. All participants had their intermaxillary space and baseline EMG activity of the anterior TA and MM measured. The subjects were fitted with three different splints, and their results were assessed using the comfort index, occlusion, and sEMG of the anterior TA and MM.	EMG data were considerably lower in persons who used a modified anterior splint than those who used a hard, soft, or no OS. Individuals with no splint had the most biting force and bite area, whereas individuals with a modified anterior splint had the least. At rest, intermaxillary space expanded, and masticatory muscles showed a considerable drop in EMG data.

DISCUSSION

This work explores the role of OSs, mandibular repositioning appliances (MRAs), and other appliances in TMD treatment. In recent years, oral appliances have gained recognition as an effective non-invasive treatment option for TMD. Among these appliances, OSs and MRAs have been extensively studied and applied in clinical practice. Additionally, some studies have explored the use of other types of appliances, such as soft occlusive splints and soft stabilization splints, in TMD management (10).

Occlusal splints (OSs)

OSs, known as bite splints or mouthguards, are custom-made oral appliances designed to reposition the jaw and provide a more stable bite. These appliances commonly manage TMD symptoms, bruxism, and other dental conditions.

Amorim et al. conducted a study to assess the effects of OS wearing on sleep bruxers, focusing on electromyographic activity in the Masseter Muscle (MM) and anterior temporalis (TA) muscles (37). Sleep-related Bruxism (SB) is a form of bruxism that occurs during sleep and can contribute to TMD symptoms. The study found that OS wearing decreased EMG activity in these muscles, suggesting a reduction in nocturnal bruxism activity. This result indicates that OSs can effectively manage SB, which may alleviate TMD symptoms associated with this condition. Caria et al. investigated the efficiency of OSs in police officers with TMD. The study revealed positive outcomes, indicating that OSs effectively improved TMD symptoms in this specific group of individuals. Police officers often face high-stress situations and may unconsciously clench their jaws, contributing to TMD. The use of OSs can provide relief from the symptoms associated with TMD in this population (22).

Costa et al. conducted a controlled clinical study to evaluate the orofacial effects of light-emitting diode (LED) therapy alone and in combination with OSs in individuals with TMD. LED therapy is a non-invasive treatment modality that uses low-level laser therapy to promote tissue healing and reduce inflammation. The results indicated that the combination of LED therapy and OSs positively affected orofacial evaluation, suggesting potential synergistic benefits in TMD management. The study highlights the potential of combining different treatment approaches to enhance TMD outcomes (48).

Daif investigated the correlation between the outcome of splint therapy and EMG activity in masticatory muscles in TMD patients with myofascial discomfort. Myofascial pain is a common TMD subtype characterized by localized muscle pain and tenderness (35). The study indicated a link between improved TMD symptoms and changes in EMG

readings, suggesting that OSs may positively impact myofascial pain in TMD patients. The findings further support the use of OSs as a viable treatment option for managing TMD-related myofascial pain.

Gomes et al. conducted a randomized clinical trial to assess the effects of massage therapy and OS therapy on electromyographic activity and the intensity of signs and symptoms in individuals with TMD and SB (40). The study aimed to explore how these therapeutic interventions influenced muscle activity and TMD-related symptoms in this specific patient population. The findings from this trial could be particularly significant as they shed light on the potential benefits of combining massage therapy with OS therapy for TMD management. However, we cannot provide an in-depth analysis of the results without specific details from the article. Nonetheless, this study highlights the importance of considering complementary therapies in TMD treatment, as multiple approaches may work synergistically to improve patient outcomes.

Deregibus conducted a randomized controlled trial to investigate the effectiveness of OSs in alleviating myofascial pain in patients with muscle-related TMD (44). Myofascial pain is a common subtype of TMD characterized by localized muscle pain and tenderness. The study aimed to determine whether OSs could relieve myofascial pain and improve overall TMD symptoms in this patient population. The results from this randomized controlled trial are crucial in understanding the efficacy of OSs in managing myofascial pain. By comparing the outcomes of patients receiving OS therapy with a control group, the study provides valuable insights into the appliance's specific effects on myofascial pain reduction.

Fei-yu et al. conducted a study to evaluate the effect of OSs in managing patients with myofascial pain. Similar to the previous study, this research focuses on the specific impact of OS on myofascial pain reduction (38). This study's findings would provide further evidence of the effectiveness of OSs in managing myofascial pain, potentially corroborating results from previous research and strengthening the case for the appliance's inclusion in TMD treatment protocols.

Akat et al. conducted a study to evaluate the effects of three types of OSs on masticatory muscle activity, muscle thickness, and muscle length in patients with bruxism (46). The study utilized both ultrasonographic and electromyographic assessments to gain insights into the impact of different OSs on muscle function and morphology in individuals with bruxism. This research is valuable as it provides information on the potential influence of various OSs on masticatory muscle activity and structure. Understanding the differences between different splint types may aid in selecting the most appropriate appliance for specific patient needs.

Amorim et al. conducted a study to analyze the electromyographic activity of the MM in individuals with SB (31, 37). The study aimed to assess muscle activity patterns during SB episodes, providing insights into the pathophysiology of sleep-related bruxism. This research contributes to our understanding of the underlying mechanisms of SB, particularly related to muscle activity. As SB can exacerbate TMD symptoms, studying its electromyographic patterns is relevant to identifying effective treatment strategies.

Botelho et al. investigated the immediate effect of the resilient splint on patients with TMD using sEMG. The study aimed to assess the appliance's impact on muscle activity in patients shortly after its application (32). This research provides insights into the immediate changes in muscle activity induced by the resilient splint. Understanding the appliance's immediate effects can help clinicians gauge its potential benefits and make necessary adjustments to optimize treatment outcomes (32). Carbonari et al. compared performance, balance, and posture variations with OS and Taopatch® devices. Evaluating the effects of different appliances on muscle activity and overall performance, the research may have implications for athletes or individuals with TMD-related functional limitations (5).

Castroflorio et al. investigated the effects of clear aligners (CAT) on SB. This randomized controlled trial explored the potential impact of orthodontic treatment on SB episodes (6). The findings may have implications for TMD management and highlight the need to consider SB during orthodontic treatment planning.

Cruz-Reyes et al. (33) assessed the influence of occlusal stabilization splints and soft OSs on the electromyographic pattern in patients with bruxism. By examining the effects of different splint types on muscle activity during bruxism episodes, the research offers valuable insights for selecting appropriate appliances for specific patient needs. Ernst et al. investigated the effects of centric mandibular splint therapy on orofacial pain and cerebral activation patterns (8). Understanding how splint therapy impacts pain perception and neural activity is critical for elucidating the mechanisms involved in TMD pain relief.

Giannakopoulos et al. compared the efficacy of device-supported sensorimotor training and splint intervention for managing myofascial TMD pain. By assessing different treatment modalities, this research aims to identify effective approaches for myofascial pain-related TMD (9). The pilot study by Hara and colleagues investigated the effectiveness of vibratory splint therapy in decreasing sleep-clenching (SC). The research explored a novel approach to managing SB using vibratory stimulation through a splint. This non-invasive method may have implications for reducing sleep-related bruxism episodes, offering potential benefits for patients with TMD and improving their overall sleep quality (10).

He et al. focused on using a stabilization splint on masticatory muscle activities in TMD patients with centric relation-maximum intercuspals discrepancy and absence of anterior/lateral guidance. Understanding how splints affect muscle activity in patients with specific occlusal discrepancies can help tailor treatment approaches and improve outcomes in this subgroup of TMD patients (24). The experimental analysis of EMG in athletes of Inchingolo et al. sheds light on the use of cranial EMG in athletes and potential applications in the assessment and management of TMD in this specific population. Understanding the potential impact of athletic activities on the craniofacial muscles can guide preventive strategies and therapeutic interventions (11).

Lan et al.'s comparative study of sEMG of masticatory muscles in patients with bruxism investigated the electromyographic patterns associated with various bruxism types. Understanding the differences in muscle activity among different bruxism types can aid in developing targeted therapeutic approaches for each subgroup of TMD patients (26).

Lei et al. evaluated the neuromuscular and occlusion analysis to assess the efficacy of three splints on patients with bruxism (47). Investigating the effects of different splints on neuromuscular function and occlusion can provide valuable insights for selecting the most suitable appliance for individual TMD patients, optimizing treatment outcomes, and effectively managing bruxism-related symptoms.

Lickteig et al. investigated the changes in brain activity associated with successful therapy for temporomandibular pain (39). The authors used neuroimaging techniques to assess alterations in brain representations of occlusion following treatment. The findings suggest that successful therapy alleviates pain and has neuroplastic effects, leading to changes in brain regions related to pain perception and sensory-motor control.

The study of Matsumoto et al. aimed to investigate the effect of intermittent use of OSs on SB (41). The researchers utilized a portable electromyographic recording device to monitor muscle activity during sleep. The findings indicated that intermittent use of OSs may reduce SB activity, suggesting a potential therapeutic approach for managing this condition.

Nanda et al. assessed the optimal time duration for splints to raise the vertical dimension in patients with generalized tooth attrition. The study aimed to find the most effective splint therapy duration to achieve the desired results (34). The findings suggest that a specific time duration of splint usage can improve outcomes in patients with dental attrition.

Pita et al. investigated the effect of OS thickness on masticatory muscle activity during rest and clenching. EMG was used to measure muscle activity while participants wore splints of different thicknesses (17). The results indicated that splint thickness influenced masticatory muscle activity, highlighting the importance of considering the design of splints for optimal therapeutic outcomes.

Takahashi et al. examined the relationship between managing sleep-time masticatory muscle activity using stabilization splints and psychological stress. The researchers assessed stress levels in patients with TMD before and after using the splints (13). The findings suggest that stabilization splints may reduce masticatory muscle activity and positively impact psychological stress levels in TMD patients.

Trindade et al. explored an interdisciplinary approach to bruxism treatment involving both OS and cognitive-behavioral therapy (CBT). The study aimed to investigate the potential benefits of combining these two treatment modalities (42). The findings suggest an interdisciplinary approach may improve outcomes in managing bruxism and associated symptoms. Vieira e Silva et al. evaluated the treatment of TMD using OS combined with electromyographic control. The researchers applied the FARC (Facial Analysis, Reeducation, and Conditioning) protocol in a Brazilian population to manage TMD symptoms. The findings indicate that this combined treatment approach may effectively improve TMD-related symptoms in this population (36).

The studies on OSs demonstrate their effectiveness in alleviating TMD symptoms, particularly in managing SB and myofascial pain. OSs can promote a more stable jaw position, reduce clenching and grinding, and relieve muscle tension and discomfort. However, it is crucial to consider patient-specific factors, such as the type of TMD and co-existing conditions, when recommending OSs as part of a comprehensive TMD treatment plan.

Mandibular repositioning appliances (MRAs)

MRAs are primarily used to treat sleep-related breathing disorders, such as obstructive sleep apnea, by slightly repositioning the lower jaw to open the airway during sleep. These appliances have also shown potential benefits for managing TMD (25).

Shousha et al. (49) conducted a study to compare the effects of low-level laser therapy (LLL) and soft occlusive splints on mouth opening and sEMG in females with TMD. While this study did not directly investigate MRAs, it is worth mentioning in the context of TMD management. The results suggested that LLLT may improve mouth opening and sEMG in individuals with TMD.

While more research is needed on the role of MRAs in TMD management, this study indicates the potential of incorporating alternative therapies alongside conventional appliances (49). Wiechens et al. investigated the changes in maximal mandibular mobility caused by splint treatment in TMD patients (45). The study aimed to understand how MRAs impact mandibular mobility, crucial for alleviating TMD symptoms. The findings indicated that MRAs positively impacted mandibular mobility, which may contribute to improved TMD outcomes. The study emphasizes the importance of evaluating the functional aspects of TMD treatment, including jaw mobility, to gauge treatment effectiveness.

The articles related to MRAs highlight the potential benefits of these appliances in managing TMD. While further research is needed to establish their effectiveness in TMD treatment specifically, MRAs have shown promise in improving mandibular mobility. They may play a role in addressing specific TMD symptoms. Additionally, using MRAs for sleep-related breathing disorders may indirectly contribute to TMD symptom relief, as improved sleep quality can positively impact overall well-being.

Other appliances

Some studies have explored the use of other types of appliances in TMD treatment in addition to OSs and MRAs. Ferrario et al. investigated the immediate effect of a stabilizing splint on masticatory muscle activity in patients with TMD. This study aimed to understand how the appliance influenced muscle activity shortly after its application (30). The immediate effect of a stabilizing splint on masticatory muscle activity is crucial as it can provide insights into the appliance's initial impact on muscle tension and function. While long-term effects are also essential, understanding the immediate response helps clinicians gauge the appliance's potential benefits and make necessary adjustments. Zieliński et al. investigated the influence of a soft stabilization splint on electromyographic patterns in masticatory and neck muscles in healthy women (50). Although this study did not focus on TMD patients, it provides insights into the impact of soft stabilization splints on muscle activity. The results indicated changes in electromyographic patterns in masticatory and neck muscles, suggesting potential effects on muscle function. While this study does not directly assess the effectiveness of soft stabilization splints for TMD treatment, it highlights the relevance of considering various types of appliances in TMD management (50).

Kobayashi et al. evaluated the effectiveness of infrared LED photobiomodulation in children with SB and studied its potential application in managing SB episodes in children. The research aimed to identify noninvasive, safe, and effective therapies for pediatric patients with sleep-related bruxism (43).

Dalewski et al. compared the efficacy of OSs and modified nociceptive trigeminal inhibition (NTI) splints in bruxism therapy. The study utilized sEMG to assess muscle activity in bruxism patients. The findings showed that both OSs and modified NTI splints effectively alleviated bruxism-related muscle activity. However, the OS group exhibited better results. This suggests that OSs may be more beneficial in managing bruxism-related TMD symptoms (51).

Boulad et al. investigated the effects of treatment with NTI splints on EMG in TMD patients; this study shed light on the potential efficacy of NTI splints as a therapeutic option for managing TMD-related pain. NTI splints have been proposed to alter muscle activity, reducing the intensity of parafunctional behaviors like bruxism, and may benefit certain TMD patients (4).

Lukic et al. evaluated the short-term effects of two different OSs, partial type covering only central incisors (NTI-Tss) and Michigan splint, on nocturnal jaw muscle activity. The study used EMG to assess muscle activity during sleep. The results suggest that both types of splints may have a positive effect in reducing nocturnal jaw muscle activity, with potential implications for the management of bruxism (16).

Rój et al. explored the effects of magnetostimulation on muscle activity and pain in edentulous adults with TMD. The use of magnetostimulation is investigated as a potential therapeutic approach for managing TMD symptoms. The results suggest that magnetostimulation may have positive effects on muscle activity and pain levels in these patients (20).

Investigating other appliances, such as soft stabilization splints, is essential for understanding their potential benefits in TMD treatment. As TMD management evolves, exploring alternative and adjunctive therapies can lead to more personalized treatment plans that address individual patient needs.

Treatment considerations

While appliances can be valuable tools in TMD management, it is crucial to recognize that each patient's condition is unique, and a comprehensive approach is necessary. Treatment considerations should encompass the following aspects:

1. **Patient Evaluation and Diagnosis:** accurate diagnosis is fundamental to developing an effective treatment plan for TMD. A thorough evaluation should include medical and dental history, clinical examination, and diagnostic imaging when necessary. Identifying the underlying causes and specific manifestations of TMD is essential to guide treatment decisions.

2. **Multidisciplinary Collaboration:** TMD treatment often benefits from a multidisciplinary approach involving dentists, oral and maxillofacial specialists, physical therapists, and other healthcare professionals. Collaboration allows for comprehensive assessment and the integration of various therapeutic modalities, optimizing treatment outcomes.
3. **Customized Treatment Plans:** each patient's TMD condition is unique, and treatment plans should be tailored to address individual needs and goals. Customizing appliances, such as OSs and MRAs, ensures proper fit and function, leading to better treatment outcomes.
4. **Combination Therapies:** as seen in some of the provided articles, combining different treatment modalities, such as LED therapy with OSs, can offer synergistic benefits. Integrating complementary therapies may enhance the overall effectiveness of TMD treatment.
5. **Follow-up and Monitoring:** regular follow-up appointments are essential to evaluate treatment progress and make necessary adjustments. Monitoring TMD symptoms and appliance functionality allows for timely interventions, ensuring favorable outcomes.

Potential future developments

The field of TMD treatment continues to advance, and potential future developments hold promise for improved patient care. Some areas of interest and ongoing research include the following directions:

1. technological advances may lead to the development of more sophisticated appliances for TMD treatment. Computer-aided design and manufacturing (CAD/CAM) technologies can enable precise customization and enhanced treatment outcomes.
2. further biomechanical studies can provide a deeper understanding of how appliances influence jaw function, muscle activity, and joint biomechanics. This knowledge can inform the design of more targeted and effective appliances.
3. the integration of digital health solutions, such as telemedicine and remote monitoring, can enhance patient access to care and enable real-time assessment of treatment progress.
4. advancements in personalized medicine may allow for tailored treatment approaches based on individual patient characteristics, genetics, and responses to therapy.

Limitations and considerations in sEMG application

While sEMG is a valuable tool, it is essential to recognize its limitations and consider certain factors when applying it in clinical practice. One limitation is the need for skilled interpretation of sEMG data. Interpreting muscle activity patterns requires expertise, understanding normal and abnormal muscle function, and considering the individual's unique physiology. Additionally, sEMG provides information on muscle activation but does not directly measure muscle force. Muscle force is influenced by factors beyond electrical activity, such as muscle size, fiber type composition, and biomechanical factors.

Various factors can influence the accuracy of sEMG data, including electrode placement, skin impedance, and the position of the head and neck. Standardization of electrode placement and protocols is essential to ensure reproducible and reliable results. Furthermore, sEMG assessment should be complemented by a comprehensive clinical examination, imaging studies, and other diagnostic tools to obtain a holistic understanding of the patient's condition.

CONCLUSIONS

sEMG holds significant promise as an objective and noninvasive evaluation tool for assessing masticatory muscle function in patients with craniomandibular pain. Its applications in bite therapy evaluation allow for evidence-based treatment decisions while incorporating biofeedback, which enhances patient engagement and self-management. However, sEMG should be utilized as part of a comprehensive diagnostic approach, considering other clinical findings and diagnostic modalities to develop personalized and effective treatment plans.

As research in this area advances, sEMG will likely play an increasingly pivotal role in improving the diagnosis and management of cranio-mandibular pain and enhancing the overall quality of life for TMD patients. The studies exploring massage and OS therapy and their combination underscore the significance of considering various therapeutic approaches to improve TMD outcomes. Additionally, the research on OSs' effectiveness in alleviating myofascial pain is vital, as this subtype of TMD often requires targeted management strategies.

The collective evidence from these articles supports the use of OSs as a viable treatment option for TMD, particularly in managing myofascial pain, SB, and muscle-related symptoms. However, it is essential to emphasize that TMD treatment should be individualized based on each patient's specific diagnosis, symptoms, and treatment response.

Furthermore, while the provided articles contribute significantly to the existing literature on TMD management, more research is needed to continue advancing the field. Future studies should explore additional appliances, compare treatment modalities, investigate long-term effects, and consider the potential benefits of combining multiple therapies.

As TMD treatment evolves, incorporating evidence-based findings and embracing innovation will ultimately lead to improved patient care and enhanced quality of life for individuals affected by TMD. In conclusion, using appliances represents a valuable therapeutic option in the multifaceted management of TMD, offering hope for patients seeking relief from TMD-related symptoms and discomfort.

REFERENCES

1. Crincoli V, Anelli MG, Quercia E, Piancino MG, Di Comite M. Temporomandibular Disorders and Oral Features in Early Rheumatoid Arthritis Patients: An Observational Study. *Int J Med Sci.* 2019;16(2):253-263. doi:<https://doi.org/10.7150/ijms.28361>
2. Dimitroulis G. Management of temporomandibular joint disorders: A surgeon's perspective. *Aust Dent J.* 2018;63 Suppl 1(S79-S90). doi:<https://doi.org/10.1111/adj.12593>
3. Tegnander T, Chladek G, Hovland A, Zmudzki J, Wojtek P. Relationship between Clinical Symptoms and Magnetic Resonance Imaging in Temporomandibular Disorder (TMD) Patients Utilizing the Piper MRI Diagnostic System. *J Clin Med.* 2021;10(20):doi:<https://doi.org/10.3390/jcm10204698>
4. Boulad JMK, Al-Sabbagh RA, Burhan AS, Kouchaji CN, Nawaya FR. Effects of Treatment with Nociceptive Trigeminal Inhibition Splints on Electromyography in Temporomandibular Joint Disorder Patients. *J Contemp Dent Pract.* 2019;20(5):598-602.
5. Carbonari B, Balducci F, Cesaretti G, Cesanelli L, Botticelli D, Messina G. Performance, balance and posture variations with Occlusal Splint and Taopatch(R) devices: a retrospective cross-over study. *J Sports Med Phys Fitness.* 2021;61(2):317-323. doi:<https://doi.org/10.23736/S0022-4707.20.11053-3>
6. Castroflorio T, Bargellini A, Lucchese A, et al. Effects of clear aligners on sleep bruxism: randomized controlled trial. *J Biol Regul Homeost Agents.* 2018;32(2 Suppl. 2):21-29.
7. Inchingolo F, Tatullo M, Marrelli M, et al. Combined occlusal and pharmacological therapy in the treatment of temporomandibular disorders. *Eur Rev Med Pharmacol Sci.* 2011;15(11):1296-1300.
8. Ernst M, Schenkenberger AE, Domin M, Kordass B, Lotze M. Effects of centric mandibular splint therapy on orofacial pain and cerebral activation patterns. *Clin Oral Investig.* 2020;24(6):2005-2013. doi:<https://doi.org/10.1007/s00784-019-03064-y>
9. Giannakopoulos NN, Rauer AK, Hellmann D, Hugger S, Schmitter M, Hugger A. Comparison of device-supported sensorimotor training and splint intervention for myofascial temporomandibular disorder pain patients. *J Oral Rehabil.* 2018;45(9):669-676. doi:<https://doi.org/10.1111/joor.12662>
10. Hara ES, Witzel AL, Minakuchi H, et al. Vibratory splint therapy for decreasing sleep clenching: A pilot study. *Cranio.* 2020;38(1):15-21. doi:<https://doi.org/10.1080/08869634.2018.1488652>
11. Inchingolo AD, Pezzolla C, Patano A, et al. Experimental Analysis of the Use of Cranial Electromyography in Athletes and Clinical Implications. *Int J Environ Res Public Health.* 2022;19(13):doi:<https://doi.org/10.3390/ijerph19137975>
12. Ispirgil EP, Erdogan SBP, Akin AP, Sakar OP. The hemodynamic effects of occlusal splint therapy on the masseter muscle of patients with myofascial pain accompanied by bruxism. *Cranio.* 2020;38(2):99-108. doi:<https://doi.org/10.1080/08869634.2018.1491929>
13. Takahashi H, Masaki C, Makino M, et al. Management of sleep-time masticatory muscle activity using stabilisation splints affects psychological stress. *J Oral Rehabil.* 2013;40(12):892-899. doi:<https://doi.org/10.1111/joor.12110>
14. Inchingolo F, Tatullo M, Abenavoli FM, et al. Oral piercing and oral diseases: a short time retrospective study. *Int J Med Sci.* 2011;8(8):649-652. doi:<https://doi.org/10.7150/ijms.8.649>
15. Inchingolo AM, Fatone MC, Malcangi G, et al. Modifiable Risk Factors of Non-Syndromic Orofacial Clefts: A Systematic Review. *Children (Basel).* 2022;9(12):doi:<https://doi.org/10.3390/children9121846>
16. Lukic N, Saxer T, Hou MY, Zumbunn Wojczynska A, Gallo LM, Colombo V. Short-term effects of NTI-tss and Michigan splint on nocturnal jaw muscle activity: A pilot study. *Clin Exp Dent Res.* 2021;7(3):323-330. doi:<https://doi.org/10.1002/cre2.371>
17. Pita MS, Ribeiro AB, Garcia AR, Pedrazzi V, Zuim PR. Effect of occlusal splint thickness on electrical masticatory muscle activity during rest and clenching. *Braz Oral Res.* 2011;25(6):506-511. doi:<https://doi.org/10.1590/s1806-83242011000600006>
18. Inchingolo AD, Ferrara I, Viapiano F, et al. Rapid Maxillary Expansion on the Adolescent Patient: Systematic Review and Case Report. *Children (Basel).* 2022;9(7):doi:<https://doi.org/10.3390/children9071046>
19. de Leeuw R, Klasser GD. *Orofacial Pain: Guidelines for Assessment, Diagnosis, and Management.* Berlin: Quintessence Publishing; 2018.
20. Roj R, Chladek G, Wyszynska M, Morawiec T, Kasperski J. Effects of magnetostimulation on muscle activity and pain in edentulous adults with temporomandibular disorders. *Acta Bioeng Biomech.* 2018;20(2):89-100.

21. Inchingolo F, Tatullo M, Abenavoli FM, et al. Non-syndromic multiple supernumerary teeth in a family unit with a normal karyotype: case report. *Int J Med Sci.* 2010;7(6):378-384. doi:<https://doi.org/10.7150/ijms.7.378>
22. Caria PHF, Faria RJA, Faria CRSD, Croci CS, Negrão Filho R. Efficiency of Occlusal Splints on Police Officers with TMD. *Braz. J. Oral Sci.* 2014;13(292-296).
23. Coloccia G, Inchingolo AD, Inchingolo AM, et al. Effectiveness of Dental and Maxillary Transverse Changes in Tooth-Borne, Bone-Borne, and Hybrid Palatal Expansion through Cone-Beam Tomography: A Systematic Review of the Literature. *Medicina (Kaunas).* 2021;57(3):doi:<https://doi.org/10.3390/medicina57030288>
24. He S, Wang S, Song F, Wu S, Chen J, Chen S. Effect of the use of stabilization splint on masticatory muscle activities in TMD patients with centric relation-maximum intercuspation discrepancy and absence of anterior/lateral guidance. *Cranio.* 2021;39(5):424-432. doi:<https://doi.org/10.1080/08869634.2019.1655861>
25. He BJ, Nolte G, Nagata K, et al. Abstracts of Presentations at the International Conference on Basic and Clinical Multimodal Imaging (BaCI), a Joint Conference of the International Society for Neuroimaging in Psychiatry (ISNIP), the International Society for Functional Source Imaging (ISFSI), the International Society for Bioelectromagnetism (ISBEM), the International Society for Brain Electromagnetic Topography (ISBET), and the EEG and Clinical Neuroscience Society (ECNS), in Geneva, Switzerland, September 5-8, 2013. *Clin EEG Neurosci.* 2013;doi:<https://doi.org/10.1177/1550059413507209>
26. Lan KW, Jiang LL, Yan Y. Comparative study of surface electromyography of masticatory muscles in patients with different types of bruxism. *World J Clin Cases.* 2022;10(20):6876-6889. doi:<https://doi.org/10.12998/wjcc.v10.i20.6876>
27. Weisdorf S, Gangstad SW, Duun-Henriksen J, Mosholt KSS, Kjaer TW. High similarity between EEG from subcutaneous and proximate scalp electrodes in patients with temporal lobe epilepsy. *J Neurophysiol.* 2018;120(3):1451-1460. doi:<https://doi.org/10.1152/jn.00320.2018>
28. Lobbezoo F, Ahlberg J, Raphael KG, et al. International consensus on the assessment of bruxism: Report of a work in progress. *J Oral Rehabil.* 2018;45(11):837-844. doi:<https://doi.org/10.1111/joor.12663>
29. Page MJ, McKenzie JE, Bossuyt PM, et al. The PRISMA 2020 statement: an updated guideline for reporting systematic reviews. *BMJ.* 2021;372(n71). doi:<https://doi.org/10.1136/bmj.n71>
30. Ferrario VF, Sforza C, Tartaglia GM, Dellavia C. Immediate effect of a stabilization splint on masticatory muscle activity in temporomandibular disorder patients. *Journal of Oral Rehabilitation.* 2002;29(9):810-815. doi:<https://doi.org/10.1046/j.1365-2842.2002.00927.x>
31. Amorim CF, Vasconcelos Paes FJ, de Faria Junior NS, de Oliveira LV, Politti F. Electromyographic analysis of masseter and anterior temporalis muscle in sleep bruxers after occlusal splint wearing. *J Bodyw Mov Ther.* 2012;16(2):199-203. doi:<https://doi.org/10.1016/j.jbmt.2011.04.001>
32. Botelho AL, Silva BC, Gentil FHU, Sforza C, da Silva MAMR. Immediate effect of the resilient splint evaluated using surface electromyography in patients with TMD. *Cranio: The Journal of Craniomandibular Practice.* 2010;28(4):266-273. doi:<https://doi.org/10.1179/crn.2010.034>
33. Cruz-Reyes RA, Martínez-Aragón I, Guerrero-Arias RE, García-Zura DA, González-Sánchez LE. Influence of occlusal stabilization splints and soft occlusal splints on the electromyographic pattern, in basal state and at the end of six weeks treatment in patients with bruxism. *Acta Odontol Latinoam AOL.* 2011;24(1):66-74.
34. Nanda A, Srivastava A, Jain V. An electromyographic study to assess the minimal time duration for using the splint to raise the vertical dimension in patients with generalized attrition of teeth. *Indian Journal of Dental Research.* 2011;22(2):303. doi:<https://doi.org/10.4103/0970-9290.84309>
35. Daif ET. Correlation of splint therapy outcome with the electromyography of masticatory muscles in temporomandibular disorder with myofascial pain. *Acta Odontologica Scandinavica.* 2011;70(1):72-77. doi:<https://doi.org/10.3109/00016357.2011.597776>
36. Vieira e Silva CA, Rodrigues da Silva MAM, Melchior M de O, de Felício CM, Sforza C, Tartaglia GM. Treatment for TMD with Occlusal Splint and Electromyographic Control: Application of the FARC Protocol in a Brazilian Population. *CRANIO®.* 2012;30(3):218-226. doi:<https://doi.org/10.1179/crn.2012.033>
37. Amorim CF, Jose F, Santos N, Vicente L, Politti F. Electromyographic analysis of masseter and anterior temporalis muscle in sleep bruxers after occlusal splint wearing. *J Bodyw Mov Ther.* 2012;16(2):199-203. doi:<https://doi.org/10.1016/j.jbmt.2011.04.001>
38. Zhang FY, Wang XG, Dong J, Zhang JF, Lü YL. Effect of occlusal splints for the management of patients with myofascial pain: a randomized, controlled, double-blind study. *Chinese Medical Journal.* 2013;126(12):2270-2275.
39. Lickteig R, Lotze M, Kordass B. Successful therapy for temporomandibular pain alters anterior insula and cerebellar representations of occlusion. *Cephalalgia.* 2013;33(15):1248-1257. doi:<https://doi.org/10.1177/0333102413491028>
40. Gomes CAF de P, Politti F, Andrade DV, et al. Effects of Massage Therapy and Occlusal Splint Therapy on Mandibular Range of Motion in Individuals With Temporomandibular Disorder: A Randomized Clinical Trial. *Journal of Manipulative and Physiological Therapeutics.* 2014;37(3):164-169. doi:<https://doi.org/10.1016/j.jmpt.2013.12.007>
41. Matsumoto H, Tsukiyama Y, Kuwatsuru R, Koyano K. The effect of intermittent use of occlusal splint devices on sleep bruxism: a 4-week observation with a portable electromyographic recording device. *Journal of Oral Rehabilitation.* 2015;42(4):251-258. doi:<https://doi.org/10.1111/joor.12251>

42. Trindade M, Orestes-Cardoso S, de Siqueira TC. Interdisciplinary treatment of bruxism with an occlusal splint and cognitive behavioral therapy. *General Dentistry*. 2015;63(5):e1-4.
43. Kobayashi FY, Castelo PM, Gonçalves MLL, et al. Evaluation of the effectiveness of infrared light-emitting diode photobiomodulation in children with sleep bruxism: Study protocol for randomized clinical trial. *Medicine*. 2019;98(38):e17193. doi:<https://doi.org/10.1097/MD.00000000000017193>
44. Deregibus A. Are occlusal splints effective in reducing myofascial pain in patients with muscle-related temporomandibular disorders? A randomized-controlled trial. *Turkish Journal of Physical Medicine and Rehabilitation*. 2021;67(1):32-40. doi:<https://doi.org/10.5606/tftrd.2021.6615>
45. Wiechens B, Paschereit S, Hampe T, Wassmann T, Gersdorff N, Bürgers R. Changes in Maximum Mandibular Mobility Due to Splint Therapy in Patients with Temporomandibular Disorders. *Healthcare*. 2022;10(6):1070-1070. doi:<https://doi.org/10.3390/healthcare10061070>
46. Akat B, Görür SA, Bayrak A, et al. Ultrasonographic and electromyographic evaluation of three types of occlusal splints on masticatory muscle activity, thickness, and length in patients with bruxism. *Cranio: The Journal of Craniomandibular Practice*. 2020;41:1-10. doi:<https://doi.org/10.1080/08869634.2020.1820685>
47. Lei Q, Lin D, Liu Y, Lin K, Huang W, Wu D. Neuromuscular and occlusion analysis to evaluate the efficacy of three splints on patients with bruxism. *BMC Oral Health*. 2023;23(1). doi:<https://doi.org/10.1186/s12903-023-03044-5>
48. Costa DR, Pessoa DR, Seefeldt VB, et al. Orofacial evaluation of individuals with temporomandibular disorder after LED therapy associated or not of occlusal splint: a randomized double-blind controlled clinical study. *Lasers in Medical Science*. 2021;36(8):1681-1689. doi:<https://doi.org/10.1007/s10103-021-03269-2>
49. Shousha T, Alayat M, Moustafa I. Effects of low-level laser therapy versus soft occlusive splints on mouth opening and surface electromyography in females with temporomandibular dysfunction: A randomized-controlled study. Abdelbasset WK, ed. *PLOS ONE*. 2021;16(10):e0258063. doi:<https://doi.org/10.1371/journal.pone.0258063>
50. Zieliński G, Wójcicki M, Baszczowski M, et al. Influence of Soft Stabilization Splint on Electromyographic Patterns in Masticatory and Neck Muscles in Healthy Women. *Journal of clinical medicine*. 2023;12(6):2318-2318. doi:<https://doi.org/10.3390/jcm12062318>
51. Dalewski B, Chruściel-Nogalska M, Frączak B. Occlusal splint versus modified nociceptive trigeminal inhibition splint in bruxism therapy: a randomized, controlled trial using surface electromyography. *Australian Dental Journal*. 2015;60(4):445-454. doi:<https://doi.org/10.1111/adj.12259>