Volume 13, no. 3(3), September-December 2024

ISSN 2038-4106/2024

European Journal of Musculoskeletal Diseases

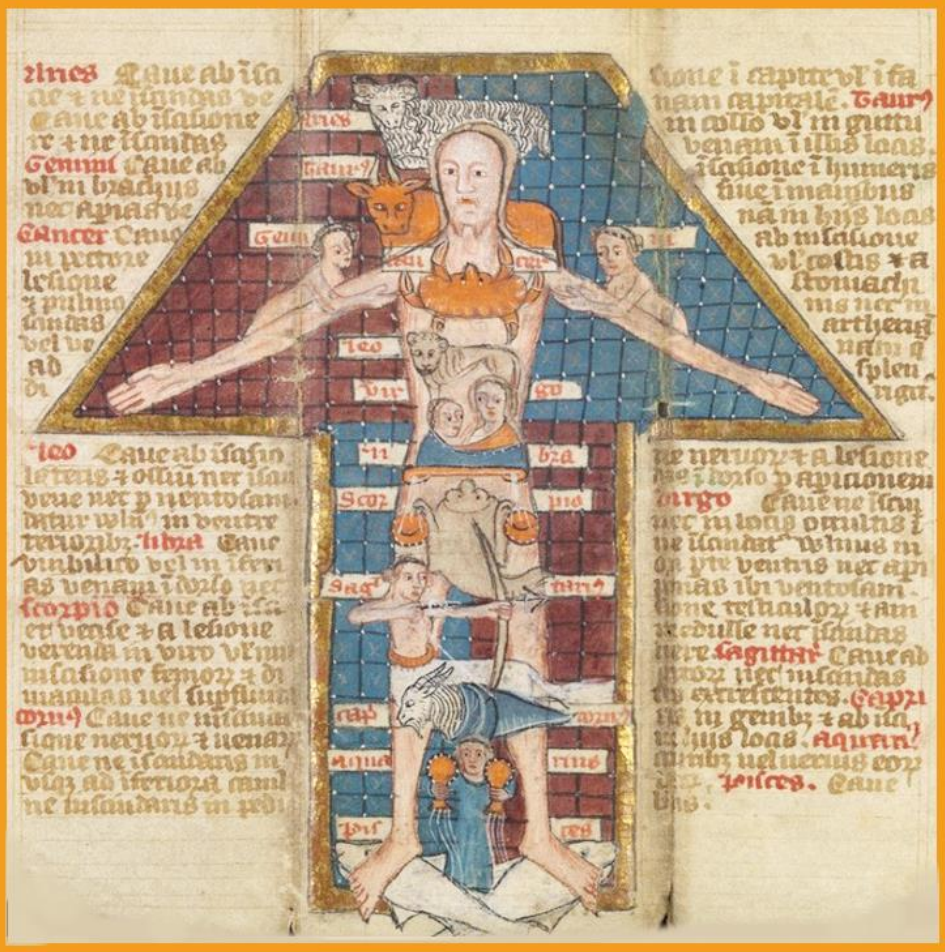

Illumination from an English folding almanac in Latin, ca. 1417

Published by
Biolife

www.biolife-publisher.it

European Journal of Musculoskeletal Diseases

13(3) September-December 2024

CONTENTS

INTEGRATED THERMAL CARE AND BIO-PHYSICO-METRIC APPROACH FOR THE TREATMENT OF LONG-COVID PATIENTS. G. Barassi, L. Prosperi, R. Pellegrino, A. Di Iorio, V. Guglielmi, A. Younes, C. Marinucci, M.P. Della Rovere and M. Panunzio …… 1-10

INTEGRATED APPROACH IN CHRONIC PAIN FROM MUSCULOSKELETAL STIFFNESS: MUSIC THERAPY AND VIBRO-ACOUSTIC PLATFORM. G. Barassi, R. Pellegrino, G.L. Matera, L. Prosperi, A. Younes, V. Guglielmi, M. Cuozzo, C. Parone, A. Di Iorio and M. Panunzio ……...…….. 11-17

CLEIDOCRANIAL DYSPLASIA AND DENTAL IMPLANTS. C. Annicchiarico, A Annicchiarico, A Coppola and R Padula ……...…… 18-19

GINGIVA INFECTION AND INFLAMMATION CAN LEAD TO PERIODONTAL DISEASE AND AUTOIMMUNITY. A. Coppola, R. Padula, A. Annicchiarico and C. Annicchiarico ……...……...…… 20-22

ANTI-INFLAMMATORY DRUG-LOADED POLYMERIC NANO-HYBRIDS HAVE SIGNIFICANT POTENTIAL IN THE FIELD OF DENTISTRY. A. Coppola, R. Padula, A. Annicchiarico and C. Annicchiarico …...…… 23-25

BONE GRAFTING STIMULATES PRECURSOR CELLS TO DIFFERENTIATE AND PROMOTE REGENERATION. A. Coppola, R. Padula, A. Annicchiarico and C. Annicchiarico ...…….. 26-29

PROSPECTIVE COMPARATIVE STUDY OF CSR IMPLANTS PROSTHESIZED WITH CONOMETRIC TECHNIQUE: ANALOG VS DIGITAL TECHNIQUE. F. Ferrini, F. Mazzoleni, M. Barbini, C. Coppo, F. Cattoni and E.F. Gherlone ……..…….. 30-39

NEEDLE-FREE INFILTRATION OF KEY MYOFASCIAL TRIGGER POINTS IN THE TREATMENT OF POSTURAL DYSFUNCTION ASSOCIATED WITH CHRONIC MYOFASCIAL PAIN SYNDROME. G. Barassi, M. Panunzio, L. Prosperi, G.L. Matera, V. Guglielmi, C. Marinucci, S. Cristiani, G. Ianieri, P. Galasso and P.E. Gallenga …...…….. 40-46

UNDERSTANDING GLUTEAL TENDINOPATHY: DIAGNOSIS AND TREATMENT. A NARRATIVE REVIEW. D. Tarantino, R. Pellegrino, A. Di Iorio, R. Mottola, R. Saggini, C. Ruosi and R. Aicale ……...…….. 47-59

COMPREHENSIVE REVIEW OF PES ANSERINUS SYNDROME: ETIOLOGY, DIAGNOSIS, AND MANAGEMENT. R. Aicale, R. Pellegrino, D.I. Angelo, R. Mottola, R. Saggini, C. Ruosi and D. Tarantino ……. 60-69

READING DEPTH EVALUATION OF INTRAORAL SCANNERS. AN IN VITRO STUDY. F. Ferrini, G. Gastaldi, F. Cattoni, L. Colella and E. Gherlone ……..……..…… 70-75

European Journal of Musculoskeletal Diseases
ISSN 2038-4106 print - ISSN 2975-044X online

Retrospective Observational Study

INTEGRATED THERMAL CARE AND BIO-PHYSICO-METRIC APPROACH FOR THE TREATMENT OF LONG-COVID PATIENTS

G. Barassi[1,2]*, L. Prosperi[2], R. Pellegrino[3], A. Di Iorio[4], V. Guglielmi[2], A. Younes[2], C. Marinucci[2], M.P. Della Rovere[2] and M. Panunzio[5]

[1] Castelnuovo della Daunia Thermal Medicine Center, Castelnuovo della Daunia, Italy;
[2] Center for Physiotherapy, Rehabilitation and Re-Education (Ce.Fi.R.R.) venue "G. d'Annunzio" University of Chieti-Pescara, Chieti, Italy;
[3] Department of Scientific Research, Campus Ludes, Off-Campus Semmelweis University, Lugano, Switzerland;
[4] Antalgic Mini-Invasive and Rehab-Outpatients Unit, Department of Innovative Technologies in Medicine & Dentistry, "G. D'Annunzio" University of Chieti-Pescara, Chieti, Italy;
[5] Responsible Research Hospital, Campobasso, Italy.

Correspondence to:
Giovanni Barassi, PhD, MSc, PT, DO
Center for Physiotherapy, Rehabilitation and Re-Education (CeFiRR)
University of Chieti-Pescara, "G. d'Annunzio"
Chieti, 66013, Italy.
e-mail: coordftgb@unich.it

ABSTRACT

COVID-19 has involved many aspects of society and, in particular, for most of those who were affected by it, the disease determined the development of prolonged pulmonary, musculoskeletal, and neurological symptoms, generating the so-called Long COVID-19 Syndrome. The aim of this study is to evaluate the effects of an Integrated Rehabilitation Care protocol, applied according to principles of assessment and treatment derived from a Bio-Physico- Metric approach, in post-COVID patients. Data from a group of 30 patients affected by Long COVID-19 Syndrome were collected right before the beginning and immediately after the end of an 8-week thermal rehabilitation protocol, performed 5 times a week for a total of 40 sessions of treatment. The Chronic Obstructive Pulmonary Disease (COPD) Assessment Test (CAT), the Medical Research Council Dyspnea Score (MRC-DS), and the software-assessed head-pelvis alignment angle were considered as assessment methods of respiratory, musculoskeletal, and neurological symptoms. Data observation showed a significant improvement in both CAT (p=0.001) and MRC-DS (p=0.001) scores after applying the Integrated Rehabilitation Care protocol. Therefore, the Integrated Thermal Care rehabilitation protocol seems to be a promising strategy to reduce symptoms of Long COVID-19 Syndrome and improve patients' quality of life healing from SARS-CoV-2 infection.

KEYWORDS*: COVID-19, long haul COVID-19, rehabilitation, physical therapy, thermal care, balneotherapy, mineral waters*

Received: 26 July 2024
Accepted: 30 September 2024

ISSN 2038-4106 print
ISSN 2975-044X online Copyright © by BIOLIFE 2024
This publication and/or article is for individual use only and may not be further reproduced without written permission from the copyright holder. Unauthorized reproduction may result in financial and other penalties. Disclosure: All authors report no conflicts of interest relevant to this article.

INTRODUCTION

Coronavirus disease 2019 (COVID-19) can be considered a multi-system disorder, manifesting commonly with respiratory, cardiovascular, hematologic, neurological, and neuropsychiatric symptoms, alone or in combination. Several descriptions of long-term COVID-19 have been documented (1), as well as its multifaceted nature that could involve multiple organ systems and multiple body functions such as breathing, taste and olfactory perceptions, pain perception, physical resistance and strength, etc. (2,3). Many patients affected by COVID-19, with different levels of severity and duration, could develop a so-called Long COVID-19 Syndrome (4-6). In fact, despite improvements in radiologic and lung function tests, Arnold et al. found that the symptoms of COVID-19 may persist and could even evolve into other severe pathologies despite the patient having completely recovered from the viral infection underlying the pathology (7). Although the definition of Long COVID-19 Syndrome is currently still debated and evolving, it is practical and acceptable to define it as the persistence of symptoms or development of sequelae beyond 3 or 4 weeks from the onset of acute symptoms of COVID-19, as replication-competent SARS-CoV-2 has not been isolated after 3 weeks (8). The literature suggests that Long COVID-19 Syndrome could be related to a persistent state of fatigue of the autonomic nervous system (9), involving the prolonged alteration of neurophysiological pathways (10,11). This chronic fatigue at a nervous level, which usually manifests itself already during the infection, would seem to favor the establishment and perpetuation of neurophysiological changes; these modifications are capable of heavily influencing the state of health of the patient, also impacting his neuro-psychological and musculoskeletal wellbeing through sensory, humoral, performance and postural alterations.

Considering the spreading of Long COVID-19 Syndrome and the deleterious effects that this can cause on the health of patients, particularly in the case of frail people already suffering from severe musculoskeletal and neurological pathologies, it is essential for medical and rehabilitation sciences to find treatment strategies for the Syndrome. These therapeutic strategies should be equally widespread in various geographical areas, easily applicable, accessible to large portions of the population, and cheap.

In this context, all over the world, there has been an attempt to investigate new therapeutic approaches based also, among others, on traditional and complementary medicines, such as herbal medicine, Yoga, and Tai Chi, up to the point of considering approaches more complex and specific to the field of global wellbeing and rehabilitation falling within the field of thermal medicine (12).

Thermal medicine is a naturalistic branch of medicine with a wide diffusion worldwide; it is often applied in the treatment of localized and systemic pathologies in curative, preventive, and rehabilitative fields (13) through the use of applications of natural techniques and substances that exploit thermal waters rich in minerals, hot mud, steam jets, assisted ventilation, massages, and swimming pool baths.

According to our previous experiences, a rehabilitation system defined as “Integrated Thermal Care”, based on the combination of several treatment techniques typical of thermal medicine, seems to be a promising therapeutic approach in the treatment of many acute and chronic musculoskeletal and neurological pathologies, particularly if combined with the principles of what we define as “Bio-Physico-Metric” approach (14,15). This operative approach is aimed at concretely identifying the most dysfunctional areas of the body of the patient, at a somatic level, to intervene quickly, effectively, and minimally invasively on the neurophysiological and mechano-postural symptoms through mechanisms involving the balancing of the activity of visceral, somatic and nervous components of the human body.

Therefore, given the ability of thermal medicine and the “Bio-Physico-Metric” approach to improve the state of health of subjects affected by a multitude of pathological states, the aim of the present study is to monitor the effects of the “Integrated Thermal Care” approach on pulmonary, musculoskeletal and neuro-physiological signs and symptoms in subjects affected by Long COVID-19 syndrome.

MATERIALS AND METHODS

This is a retrospective observational study aimed at analyzing the correlation between applying the “Integrated Thermal Care” approach and modifying the symptoms related to Long COVID-19 Syndrome in patients undergoing a thermal rehabilitation protocol. The rehabilitation protocol to which the patients were subjected is safe; it is accessible to all patients who do not highlight specific contraindications to the initial clinical evaluation necessary for all patients who access the facility where the study is carried out; furthermore, the protocol does not constitute an experimental practice, as it is the same therapeutic protocol used for all patients who do not present the aforementioned contraindications.

The study was conducted in accordance with the ethical principles outlined in the Declaration of Helsinki. Written informed consent was obtained at enrolment from participants who were willing and able; alternatively, informed consent was obtained from caregivers. Because of all these considerations and the lack of incontrovertible national legislation regarding the need to submit retrospective and/or non-pharmacological observational studies to an ethics committee, the normal ethics committee clearance was not required (16).

From June to December 2021, in the Thermal Medical Center of Castelnuovo della Daunia (Foggia, Italy), operating within the National Health Service, a total of 30 post-COVID patients were identified among those about to start a therapeutic thermal rehabilitation protocol to regain a state of wellbeing in the presence of a generalized malaise following a previous SARS-CoV-2 infection.

The main inclusion criteria were:

- symptoms associated with Long COVID-19 Syndrome as defined by the current literature on the subject (8), in particular in terms of perceived respiratory dysfunctions, neurophysiological dysfunctions (such as fatigue or sleep disorders), musculoskeletal pain and concurrent spinal postural alteration influencing the state of well-being of the patients. The symptoms that have arisen and can be associated with COVID-19 had to be present in the patient, in whole or in part, for more than 4 weeks after their onset post-infection, even if the infection is undetectable by molecular and antigenic swabs.

The exclusion criteria were:

- critical cognitive impairments (severely limited sensory and communication skills) or heavily compromised immune functions;
- general contraindications to balneotherapy and physical therapies, such as severe cardiovascular problems, infections, neoplasms and tumors, epilepsy, electronic or metallic-electroconductive implants, pregnancy;
- inability to read and understand own native language;
- concomitant use of other medical treatments during the observation period of the present study.

All patients underwent a specific evaluation of neuro-sensory and motor-postural symptoms resulting from Long COVID-19 Syndrome. The data collection and the procedures applied were part of the standard clinical routine of the facility where the study was carried out for patients showing symptoms of Long COVID-19 Syndrome. In order to obtain data that were easily understandable and interpretable, as well as of rapid collection, the patients observed for the present study were evaluated through:

- CAT [Chronic Obstructive Pulmonary Disease (COPD) Assessment Test]: used to evaluate the health status of patients with COPD and other respiratory diseases. Indeed, it contains items focused on respiratory symptoms and non-respiratory symptoms such as sleeping disturbance or limitations in activities at home. In particular, the rating scale is made up of 8 items that investigate various aspects related to the respiratory capacity of the patient, such as cough, mucus, chest tightness, physical resistance to walking, physical resistance to domestic activities, perceived safety in leaving the home environment, noise of the sleep and perceived energy level. Each item assesses the severity of the symptomatology with a score from 0 (no symptoms) to 5 (extremely present and disabling symptom) (17,18). Although the scale was created to evaluate chronic obstructive pulmonary disease, it has been demonstrated that this score can be a valid evaluation and predictive system in the context of COVID-19 and the post-infectious symptoms of the same pathology (19).
- MRC-DS (Medical Research Council Dyspnea Scale): a simple and valid method of categorizing patients with COPD and other respiratory diseases in terms of the influence of the respiratory deficit on their physical capacity. The scale measures the level of dyspnea perceived by the patient in a classification system divided into 5 levels of onset of breathing difficulties depending on the intensity of the activity performed (grade 0 = dyspnea after intense physical activity, grade 1 = dyspnea after walking at fast pace or uphill, grade 2 = dyspnea after walking at a slow pace on level ground, grade 3 = dyspnea after just 100 meters of walking, grade 4 = dyspnea when dressing/undressing). This scale has been successfully applied to evaluate dyspnea in many respiratory diseases, and a new application for COVID-19 monitoring has been recently found (20).
- Sa.B.B. (Safe Bead Balance): it is a postural markers-free assessment tool based on the use of a Microsft Kinect® camera that, when paired with an exclusive software, possesses the ability to reconstruct a three- dimensional avatar known as Skeletal View, composed by 20 anatomical landmarks. The software works at a frequency of 30 frames per second, and each single analysis has a total duration of no more than 5 seconds, with an average capture of 150 frames in a single assessment. The avatar obtained through the combination of all the frames captured is formed by two projections, a frontal one and a sagittal one, which contain and highlight different postural setting parameters both of a single body district and of multiple districts in more or less direct relationship with each other, such as the spine, the shoulders, the hips and various other body parts (21).

For this study, the evaluation parameter considered in the assessment made through the Sa.B.B. software was the head-pelvis alignment, understood as the angle that is formed between the line perpendicular to the center of the pelvis (understood as the center of the bisiliac line) and the line that connects this same point to the ideal center of the skull of the patient, with values that can take on negative numbering (sloping to the right) or positive (sloping to the left). This angle is the most intuitive parameter for evaluating the general postural alignment of the patient in relation to his spine, allowing us to investigate how he positions the skull and, more generally, the upper part of the body compared to the lower one. Basically, through this parameter, we can guess to what extent the spine of the patient is aligned or in a state of compensation for musculoskeletal and/or neurosensory alterations.

The subjects were evaluated at times T0 (admission and first medical examination in the facility) and T1 (8 weeks after the beginning of the protocol). All patients underwent the rehabilitation protocol five times a week for a total of 40 sessions of treatment. All patients observed for this study completed the investigated protocol entirely and without side effects.

The rehabilitation protocol, as defined by the “Integrated Thermal Care” approach, was performed for each daily session according to the following operative scheme:

1. drinking a total of 4 glasses, 200 ml each, daily of exogenous mineral water (alkaline-earthy-bicarbonate-sulfate), which promotes the general well-being of the organism, showing anti-inflammatory effects at the gastric, intestinal, and urological levels (22, 23);
2. steam inhalations with direct hot humid jets that are carried out through individual devices from which the mineral water comes out from a nozzle in the form of a homogeneous mist at a pressure of 1.5 atmospheres and at a temperature of 37°-38° (24, 25) lasting about 20 minutes. This phase was coupled with a manual pressure stimulation of Key myofascial Trigger Points (KTrPs) located in muscles present in the main body areas involved in breathing (neck, thorax, upper back, lower back, and abdomen). The manual pressure stimulation was performed for about 30 to 60 seconds on each KTrP previously instrumentally identified as abnormally resistant to the passage of a current generated by an impedance meter neuromodulation device (ENF Studio Physio, Fast Therapies S.r.l., Carpenedolo, Italy). The assessment of KTrPs was made by the physiotherapist right before the beginning of the inhalation treatment, according to the principles of the Bio-Physico-Metric approach, aimed at re-establishing a general state of well-being through manual stimulation of so-called KTrPs (26);
3. tympanic insufflations (Polizer), used to reduce inflammation in the upper airways (performed according to specialist medical indication) (27);
4. pulmonary mechanical ventilation, practiced after inhalation and insufflation therapies with mineral water. The treatment was applied with an automatic frequency of no more than 14 breaths per minute (according to specialist medical indication) (28);
5. mud therapy (with thermal water and "Bentonite" volcanic clay) was applied on body parts where KTrPs previously identified in phase 2 were located on the region of the neck, thorax, upper back, lower back, and abdomen (29);
6. assisted hydrokinesitherapy in thermal water, associated with the manual treatment performed by the physiotherapist on KTrPs previously identified in phase 2 (30);
7. auxiergic vascular path performed in thermal water through underwater ozone-enriched hydromassage jets.

Data were analyzed to assess departure from linearity, using the Skewness and Kurtosis test for linearity (SKTEST procedure) and accordingly for continuous variables (CAT and Sa.B.B.); since no deviation was found, the Paired T-Test was applied to assess between times differences. For categorical variables (MRC-DS), a chi-square test for trend was applied. A statistically significant level was set for p-value <0.05; data analysis was performed using STATA (Statacorp LLC, College Station, Texas, USA).

RESULTS

The demographic characterization of the sample is detailed in Table I. It is important to underline that, in addition to the symptoms of Long COVID-19 Syndrome subjectively reported by all the patients considered, some of them, at the time of admission, had CAT (≥10) or MRC-DS (≥2) scores considered symptomatic for COVID-19 respiratory dysfunction according to the standards currently most widespread in the literature (31).

Table I. *Demographic characteristics of participants.*

Characteristic	Total	Males	Females
Number of patients (%)	30 (100)	15 (50)	15 (50)
Mean age ± SD	58.8 ± 12.8	58.1 ± 15.2	59.5 ± 10.3
Ethnicity			
Caucasian Mediterranean (%)	30 (100)	15 (50)	15 (50)
Other (%)	0 (0)	0 (0)	0 (0)
Initial CAT Score ≥10 (%)	23 (77)	12 (40)	11 (37)
Initial MRC-DS Score ≥2 (%)	12 (40)	6 (20)	6 (20)
Initial CAT Score ≥10 + MRC-DS Score ≥2 (%)	11 (37)	6 (20)	5 (17)

All patients successfully completed the total sessions required for the rehabilitation protocol, and no adverse events were detected at any stage of the treatment process. CAT score showed a statistically significant reduction (T0=16.76±8.48; T1= 8.73±5.22, p-value <0.001), indicating a halving of the severity of respiratory and fatigue symptoms perceived by patients in relation to the presence of Long COVID-19 Syndrome. At the same time, the value of Sa.B.B. head-pelvis alignment angle highlighted a reduction in the value (T0=2.38±3.20; T1= 1.95±3.06, p-value not statistically significant) which, although not statistically significant, could indicate that the treatment had a modest effect on the postural setting of the treated patients, particularly at the spine level, despite the very high variability of the initial and final reference values, highlighted by the large standard deviation values detected during the analysis (Table II).

Table II. *Paired T-Test results for continuous variables.*

Variable	T0	T1	*p*-value
CAT Score	16.76±8.48	8.73±5.22	<0.001
Sa.B.B. head-pelvis alignment angle	2.38±3.20	1.95±3.06	n.s.

Finally, the categorical variable MRC-DS highlighted a statistically significant (for trend p-value <0.001) reduction in the severity of dyspnea related to the presence of Long COVID-19 Syndrome in patients (Fig. 1); in fact 20/30 (66%) subjects improved their symptomatology, whereas 9/30 (30%) were stable and only one subjects worsened, with a general reduction in the mean value detected before and after treatments (T0=1.53±0.97; T1=0.80±0.66). The reduction of the two scores evaluated significantly improves the well-being of subjects observed for the study.

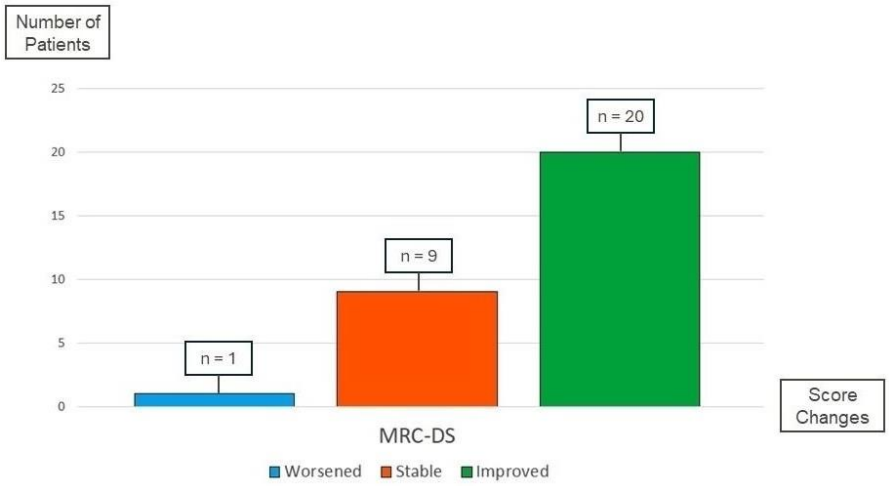

Fig. 1. *Changes in MRC-DS Scores after the rehabilitation protocol (chi-square test for trend analysis).*

DISCUSSION

The main results of our study underly that after 8 weeks of rehabilitation through the principles of "Integrated Thermal Care" combined with the "Bio-Physico-Metric" approach, patients showed a significant improvement in CAT and MRC-DS scores but only a slight non-significant improvement in the Sa.B.B. head-pelvis alignment angle.

Long-term management of COVID-19 symptoms requires multiple, multidimensional approaches (32) and can benefit from evidence-based complementary techniques, such as thermal medicine (12). Thermal medicine has, in fact, a centuries-old tradition as a therapeutic approach and is widely spread in different parts of the world where thermal realities constitute an important element of mass therapy. It is relatively simple, economical, and usable by a large portion of the local population, presenting some differences in the physical-chemical characteristics of the specific thermal environments (12).

The World Health Organization itself, by virtue of the therapeutic potential of traditional and complementary medicines, hopes for the development of a scientific investigation regarding the application of these alternative medicines to identify strategies for the containment of widely spread pathologies, especially in a context of globalization which could promote the increasingly frequent emergence of pandemics such as COVID-19 (33). It is important to ensure that the medical environment is prepared as much as possible to face global health emergencies, exploiting every existing therapeutic approach that is sufficiently effective and scientifically investigated, even in the case of traditional, alternative, and complementary medicines. It is no coincidence, in this regard, that the World Health Organization has committed itself to promoting, over the last decade, a program of investigation and development of traditional and complementary medicines carried out from 2014 to 2023 and extended until 2025 while waiting to evaluate the effects and possible future developments (33).

Based on these considerations, in this study, we tried to evaluate a methodologically more scientific and structured approach in the context of rehabilitation for Long COVID-19 Syndrome. In this approach, patients received treatments typical of thermal therapy combined with manual (somatic) stimulation of KTrPs identified through the Bio- Physico-Metric pathway, aiming to restore the best possible somato-visceral reflex activity and vice versa.

This approach is based on observing objective measurement parameters to identify dysfunctional areas defined as KTrPs. These specific points are overstimulated areas within a contracted band found in the myofibrils of a muscle belly (34), characterized by a chronic circumscribed myofibrillar shortening. KTrPs contribute to establishing and maintaining musculoskeletal dysfunctions and neurological symptoms directly (from the local inflammatory process and mechanical alteration) and indirectly (through reflex neurophysiological pathways and systemic inflammation). KTrPs are characterized by palpatory tenderness, referred tension, motor dysfunction, and autonomic manifestations (34). In addition to manifesting themselves locally, these symptoms often take on the characteristics of distant irradiation, following the dermatomal path of the area originally affected and leading to the genesis of Satellite Trigger Points at a distance from the KTrP. These irradiative and expansive phenomena of KTrPs increase their dysfunctional intrusiveness, favoring the perpetuation and chronicity of musculoskeletal and neurophysiological symptoms (34). The stimulation of KTrPs, through manual treatment and/or through instrumental stimulation (electrical, thermal, or mechanical), tends to reduce pain and functional limitations, as well as neuro-sensory symptoms determined locally and/or systemically by KTrPs (27).

Indeed, to reduce symptoms from Long COVID-19 Syndrome, subjects were treated with typical thermal medicine techniques in combination with soft tissue manipulative therapy and mud application on the identified KTrPs through the use of an impedance meter neuromodulation device.

The improvement of respiratory symptoms and fatigue observed through the CAT and the MRC-DS scores was obtained through the association of hydroponic and inhalation treatments and a multimodal stimulation (manual, with hot mud and assisted hydrokinetic therapy) of the KTrPs in the muscle of the areas bodily involved in breathing, as already observed by us in other pathological contexts (13). In this regard, the current literature on the topic suggests that the symptoms of Long COVID-19 Syndrome can persist in the human body for very long intervals, on average ranging from 3 months to over 6 months (8,20). Considering that the patients analyzed in this study had respiratory and psychophysical symptoms of COVID-19 for at least 4 weeks at the time of admission and that the duration of the treatment protocol was 8 weeks, it seems unlikely that the detected improvements of the CAT and MRC-DS scores were purely the result of the time that has passed since the first assessment was carried out. This appears in agreement with what was highlighted by a large prospective study on the subject, which showed that in patients suffering from Long COVID-19 Syndrome, CAT and MRC-DS scores would appear to improve to a limited or non-existent extent in the absence of adequate therapeutic intervention (20).

Equally interesting are the considerations that can be made regarding the influence of the treatment protocol on the postural setting of the treated subjects. By observing the variation between T0 and T1 of the head-pelvis alignment angle value detected using the Sa.B.B. system, it seems that the Integrated Thermal Care treatment coupled with the Bio-Physico-Metric Approach was able to induce positive variations in the postural setting of patients, with an explicit although not significant tendency towards postural realignment at the level of the spine. This phenomenon was detected despite a very high variability and lack of homogeneity in the starting postural malalignment values of the 30 patients

observed in this study, which allows us to assume the possibility of obtaining a clearer and more marked positive effect in populations that are more homogeneous regarding the degree of postural dysfunction. In fact, the literature highlights that postural dysfunctions would require to be considered in a very specific way, from an evaluative and therapeutic point of view, both with regard to the demographic characteristics of the sample analyzed and the body systems and subsystems involved (35). For example, it is known that Long COVID-19 Syndrome is often associated with the presence of the so-called Postural Orthostatic Tachycardia Syndrome, in the presence of which it is possible to witness the appearance of autonomic symptoms in relation to the posture assumed by infected subjects (36, 37).

In a recent review on Long-Covid (38), many of these things were elucidated, also covering the fields of micro-thrombi (39), mainly IL-1 induced (40), and the rare case of anaphylaxis among the vaccinated population (41). The proposed project paves the way to devote more attention to the blood white cells, as well-known messenger monocytes (42-43) and macrophages, through charging from the ACE receptor and P2X7 receptor (44).

Increased fatigue severity is associated with stronger signs of monocyte activation in long COVID patients, potentially pointing toward monocyte-endothelial interaction. These abnormalities were present against a background of immune abnormalities common to the entire group of long COVID patients.

The correlations with Long-Covid deserve new insights. The Integrated Thermal Care and Bio-Physico-Metric Approach for treating Long-Covid is a proposal that can help Long-Covid patients overcome correlated difficulties better.

Considering the reciprocal influence existing between the nervous system and the musculoskeletal system, the results of this study, although characterized by a mixed magnitude and significance, seem to confirm that an approach based on both metabolic and musculoskeletal stimulations might be able to positively influence complex pathologies like Long COVID-19 Syndrome, especially if the stimuli are provided according to specific and organized operative principles, such as those of the Bio-Physico-Metric Approach (27).

Despite the relatively small sample size, this protocol seems to cover a broad range of positive effects on patient's health, even for mostly neurologically induced manifestations such as breathing difficulties in the absence of clear pulmonary anomalies and symptoms such as fatigue and sleep disturbances.

This study, however, presents some limitations. Firstly, the characteristics of the sample appear to be small in relation to the general diffusion of Long COVID-19 Syndrome and rather heterogeneous by virtue of the observational nature of the study, which prevented the characteristics of the sample (age, sex, BMI, and comorbidities) from being meticulously standardized. Secondly, there is a lack of an extended follow-up to observe the effectiveness of the protocol in the medium-long term, which would be desirable to better monitor the evolution of Long COVID-19 Syndrome characterized by a duration of specific symptoms that tends to be rather long. Thirdly, there is an evident lack of a control group that could allow us to evaluate the magnitude of the protocol implemented in speeding up recovery from Long COVID-19 Syndrome. To bypass these limitations, further studies with a larger and more homogeneous sample, subjected to a follow-up long after the intervention and to the comparison with a control group, would be necessary to define a relevant protocol.

However, we must also consider some important strengths of our study and, more generally, the observational research in the context of widespread pathologies such as COVID-19 and its syndromic derivations. First of all, observational studies such as the one proposed allow us to identify and monitor in a real situation the therapeutic potential of some treatment approaches that would otherwise find little interest in research, bypassed by the predominant pharmacological and surgical approaches (45, 46). This allows us to identify, at least on a preliminary basis, the complementary and alternative approaches in which it is worth investing in research, thus reducing the costs and timing of identifying new therapeutic avenues, especially in rapidly spreading pathologies such as Long COVID-19 Syndrome (45, 46).

Furthermore, it has been observed several times in the literature that, contrary to what is commonly believed in the scientific field, there is a quite close concordance between the results of well-designed observational studies and controlled and randomized studies on the same topic, obviously provided that the observations are accompanied by a correct and honest analysis of potential biases (46). Finally, it should be highlighted that the results of observational studies in the therapeutic field are often difficult to dispute when the magnitude of the results obtained is so important as to be incontrovertible (47). Net of this, we believe that our study, without having any presumption of having identified a new therapeutic gold standard in the treatment of Long COVID-19 Syndrome, could provide the right ideas to investigate the therapeutic potential of an approach that finds its strengths in its reduced invasiveness and high tolerability by patients. We may also outline the high level of adherence to the protocol highlighted in the patients under observation.

The timing and the relationship with the health professionals increased curiosity and motivation to undergo the protocol, providing better adherence to the therapies, which translated into positive therapeutic results in accordance with the principles of the Biopsychosocial model of health (48). This positive finding of our study is also particularly relevant since it has been observed that psychosocial symptoms like depression, fear, and kinesiophobia, which are also typically associated with Long COVID-19 Syndrome, may have a negative impact on the quality of life and pain perception of

these patients (49). Given the general positivity of the results obtained, the rehabilitation approach proposed in the present study could represent a new vision of cooperating between thermal care and rehabilitation with a view to defining a new, structured and scientifically validated alternative therapeutic approach to Long COVID-19 Syndrome.

CONCLUSIONS

Long COVID-19 Syndrome affects multiple organ systems, and its management requires a comprehensive approach. This may include the association between thermalism and somatic therapy of the dysfunctional reflex areas, which often represent the expression of internal organic and neurological dysfunctions leading to the genesis of symptoms such as pain, sensory alterations, fatigue, and postural alterations. This approach can improve health outcomes, at least in the short term, while reducing unnecessary hospital admissions, thus preventing the depletion of healthcare resources that have already been significantly strained worldwide during the COVID-19 pandemic.

Since the Long COVID-19 Syndrome can be particularly disabling and also occur in fragile subjects affected by neuromuscular pathologies that reduce their movement capabilities and tolerance to active work, a minimally invasive treatment approach such as the one observed in this study could represent a valid complementary or alternative therapeutic solution compared to classic approaches to date proposed for the syndrome (such as athletic reconditioning through physical exercise). Larger and more structured studies are needed regarding the approach we observed; confirming the positive results we obtained in a purely observational setting would allow us to expand the therapeutic arsenal to address the long-term consequences of a pandemic-wide pathology such as COVID-19. In fact, based on observations of the data obtained, the proposed “Integrated Thermal Care” protocol could be an innovative approach that improves the health status of COVID-19 patients, helping them recover even from the long-term effects of the pathology.

Despite the limitations, the high adherence to the protocol and the significant improvements observed in this study provide a basis for further research. Larger, randomized, controlled trials with longer follow-up periods are needed to confirm these preliminary results and demonstrate the long-term efficacy and safety of the protocol.

In conclusion, while this study provides promising evidence for the use of Integrated Thermal Care and the Bio-Physico-Metric approach in the treatment of Long COVID-19 Syndrome, further research is needed to address the limitations of the current study and to validate the effectiveness of this rehabilitation strategy fully.

Funding
No external funding has been received to carry out the research.

Conflict of interest
The authors declare that they have no conflict of interest.

REFERENCES

1. Callard F, Perego E. How and why patients made Long Covid. Social Science & Medicine. 2021; 268:113426. 10.1016/j.socscimed.2020.113426
2. McMahon DE., Gallman AE, Hruza GJ, et al. COVID in the skin: a registry analysis of COVID-19 dermatological duration. The Lancet Infectious Diseases. 2021; 21(3):313-314. 10.1016/S1473-3099(20)30986-5
3. Stavem K, Ghanima W, Olsen MK, Gilboe HM, Einvik G. Persistent symptoms 1.5–6 months after COVID-19 in non- hospitalised subjects: a population-based cohort study. Thorax. 2021; 76(4):405-407. 10.1136/thoraxjnl-2020-216377
4. Lu Y, Li X, Geng D, et al. Cerebral micro-structural changes in COVID-19 patients–an MRI-based 3-month follow-up study. EClinical Medicine. 2020; 25. 10.1016/j.eclinm.2020.100484
5. Dennis A, Wamil M, Alberts J, et al. Multiorgan impairment in low-risk individuals with post-COVID-19 syndrome: a prospective, community-based study. BMJ Open. 2021; 11(3):048391. 10.1136/bmjopen-2020-048391
6. Townsend L, Dowds J, O’Brien K, et al. Persistent poor health after COVID-19 is not associated with respiratory complications or initial disease severity. Annals of the American Thoracic Society. 2021; 18(6):997-1003. 10.1513/AnnalsATS.202009-1175OC
7. Arnold DT, Hamilton FW, Milne A, et al. Patient outcomes after hospitalisation with COVID-19 and implications for follow-up: results from a prospective UK cohort. Thorax. 2021; 76(4):399-401. 10.1136/thoraxjnl-2020-216086

8. Nalbandian A, Sehgal K, Gupta A, et al. Post-acute COVID-19 syndrome. Nature Medicine. 2021; 27(4):601-615. 10.1038/s41591-021-01283-z
9. Dani M, Dirksen A, Taraborrelli P, Torocastro M, Panagopoulos D, Sutton R, Lim PB. Autonomic dysfunction in 'long COVID': rationale, physiology and management strategies. Clinical Medicine. 2021; 21(1):63. 10.7861/clinmed.2020- 0896
10. D'Ardes D, Carrarini C, Russo M, et al. Low molecular weight heparin in COVID-19 patients prevents delirium and shortens hospitalization. Neurological Sciences. 2021; 42:1527-1530. 10.1007/s10072-020-04887-4
11. Lombardi G, Paganelli R, Abate M, et al. Leukocyte-derived ratios are associated with late-life any type dementia: a cross-sectional analysis of the Mugello study. Geroscience. 2021; 43(6):2785-2793. 10.1007/s11357-021-00474-3
12. Bailly M, Evrard B, Coudeyre E, et al. Health management of patients with COVID-19: is there a room for hydrotherapeutic approaches? International Journal of Biometeorology. 2022; 66(5):1031-1038. 10.1007/s00484-022- 02246-w
13. Scanu A, Tognolo L, Maccarone MC, Masiero S. Immunological Events, Emerging Pharmaceutical Treatments and Therapeutic Potential of Balneo therapy on Osteoarthritis. Front Pharmacology. 2021; 12:681871. 10.3389/fphar.2021.681871
14. Barassi G, Panunzio M, Di Iulio A, et al. Integrated Thermal Rehabilitation Care: An Intervention Study. Healthcare. 2023; 11(17):2384. 10.3390/healthcare11172384
15. Barassi G, Di Simone E, Supplizi M, et al. Bio-Physic-Metric approach: integrated postural assessment in musculoskeletal dysfunctions. Journal of Biological Regulators and Homeostatic Agents. 2022; 36(1):129-135. 10.23812/21469L
16. Winter EM, Maughan RJ. Requirements for ethics approvals. J Sports Sci. 2009; 27(10):985. 10.1080/02640410903178344
17. Jones PW, Harding G, Berry P, Wiklund I, Chen WH, Kline Leidy N. Development and first validation of the COPD assessment test. Eur Respir J. 2009; 34:648–654. 10.1183/09031936.00102509
18. Houben-Wilke S, Janssen DJA, Franssen FME, Vanfleteren LEGW, Wouters EFM, Spruit MA. Contribution of in- dividual COPD assessment test (CAT) items to CAT total score and effects of pulmonary rehabilitation on CAT scores. Health and Quality of Life Outcomes. 2018; 16:1-8. 10.1186/s12955-018-1034-4
19. Freund O, Breslavsky A, Givoli-Vilensky R, et al. Assessment of a close respiratory follow-up schedule at 3 and 6 months after acute COVID-19 and its related investigations. Respir Med. 2023; 217:107367. 10.1016/j.rmed.2023.107367
20. Cheng SL Lin CH, Wang CC, et al. Comparison between COPD Assessment Test (CAT) and modified Medical Research Council (mMRC) dyspnea scores for evaluation of clinical symptoms, comorbidities and medical resources utilization in COPD patients. Journal of the Formosan Medical Association. 2019; 118(1):429-435. 10.1016/j.jfma.2018.06.018
21. Barassi G, Bellomo RG, Carmignano SM, Di Felice PA, Giannuzzo G, Leggieri M, D'Ettole S, Saggini R. Flexible software for the elimination of the markers used in the analysis of human posture through kinect® sensor. Archives of Physio-therapy & Global Researches. 2016; 20(1).
22. Matsumoto S. Evaluation of the Role of Balneo therapy in Rehabilitation Medicine. J Nippon Med Sch. 2018; 85(4):196- 203
23. Aversano A, Rossi FW, Cammarota F, De Paulis A, Izzo P, De Rosa M. Nitrodi thermal water downregulates protein S-nitrosylation in RKO cells. Int J Mol Med. 2020; 46(4):1359-1366. 10.3892/ijmm.2020.4676
24. Dessanges JF. A history of nebulization. J Aerosol Med. 2001; 14(1):65-71. 10.1089/08942680152007918
25. Sanders M. Inhalation therapy: an historical review. Prim Care Respir J. 2007; 16(2):71-81. 10.3132/pcrj.2007.00017.
26. Barassi G, Pellegrino R, Di Matteo C, et al. Bio-Physico-Metric Approach: Assessment and Treatment of Key Myofascial Trigger Points through an Adaptive Neuromodulation Device. Journal of Biological Regulators and Homeostatic Agents. 2023; 37(1):25-29. 10.23812/j.biol.regul.homeost.agents.20233701.3
27. Califano L, Salafia F, Mazzone S, D'Ambrosio G, Malafronte L, Vassallo A. A comparative randomized study on the efficacy of a systemic steroid therapy vs. a thermal therapy in otitis media with effusion in children. Minerva Pediatr. 2016; 68(4):241-249.
28. Maccari JG, Teixeira C, Gazzana MB, Savi A, Dexheimer-Neto FL, Knorst MM. Inhalation therapy in mechanical ventilation. J Bras Pneumol. 2015; 41(5):467-472. 10.1590/S1806-37132015000000035.
29. Tateo F, Ravaglioli A, Andreoli C, Bonina F, Coiro V, Degetto S, Giaretta A. The in-vitro percutaneous migration of chemical elements from a thermal mud for healing use. Appl. Clay Sci. 2009; 44:83–94. 10.1016/j.clay.2009.02.004
30. Becker BE. Aquatic therapy: scientific foundations and clinical rehabilitation applications. Pm&r. 2009; 1(9):859-872. 10.1016/j.pmrj.2009.05.017.

31. Johnsen S, Sattler SM, Miskowiak KW, et al. Descriptive analysis of long COVID sequelae identified in a multidisciplinary clinic serving hospitalised and non-hospitalised patients. ERJ Open Res. 2021; 7(3):00205-2021. 10.1183/23120541.00205-2021
32. Nalbandian A, Sehgal K, Gupta A, et al. Post-acute COVID-19 syndrome. Nat Med. 2021; 27(4):601-661. 10.1038/s41591-021-01283-z
33. World Health Organization (WHO). Global strategy on traditional medicine (EB152/18). Fifteenth meeting of World Health Executive Board, World Health Organization, Geneva, 6th February; 2023. Available: https://apps.who.int/gb/ebwha/pdf_files/EB152/B152(18)-en.pdf.
34. Donnelly JM, Fernández-de-las-Peñas C, Finnegan M, Freeman JL. Travell, Simons & Simons' Myofascial Pain and Dysfunction: the Trigger Point Manual. 3rd ed. Wolters Kluwer: Alphen aan den Rijn; 2018
35. Saggini R, Anastasi GP, Battilomo S, et al. Consensus paper on postural dysfunction: recommendations for prevention, diagnosis and therapy. J Biol Regul Homeost Agents. 2021; 35(2):441-456. 10.23812/20-743-A
36. Raj SR, Arnold AC, Barboi A, et al. Long-COVID postural tachycardia syndrome: an American Autonomic Society statement. Clin Auton Res. 2021; 31(3):365-368. 10.1007/s10286-021-00798-2
37. Rigo S, Urechie V, Diedrich A, Okamoto LE, Biaggioni I, Shibao CA. Impaired parasympathetic function in long- COVID postural orthostatic tachycardia syndrome - a case-control study. Bioelectron Med. 2023; 9(1):19. 10.1186/s42234-023-00121-6
38. Grohmann G, Booy R. An update on Long COVID. Microbiology Australia. 2024; 45(1): 18-21. 10.1071/MA24007
39. Knight R, Walker V, Ip S, et al. Association of COVID-19 with major arterial and venous thrombotic diseases: a population-wide cohort study of 48 million adults in England and Wales. Circulation. 2022; 146(12):892-906. 10.1161/CIRCULATIONAHA.122.060785
40. Conti P, Caraffa A, Gallenga CE, et al. IL-1 induces throboxane-A2 (TxA2) in COVID-19 causing inflammation and micro-thrombi: inhibitory effect of the IL-1 receptor antagonist (IL-1Ra). J Biol Regul Homeost Agents. 2020 34(5):1623-1627. 10.23812/20-34-4EDIT-65
41. Bellomo RG, Gallenga CE, Caraffa A, Tetè G, Ronconi G, Conti P. Anaphylaxis is a rare reaction in COVID-19 vaccination. J Biol Regul Homeost Agents. 2021; 35(3):839-842. 10.23812/BELLOMO_EDIT_3_21
42. Berentschot JC, Drexhage HA, Aynekulu Mersha DG, et al. Immunological profiling in long COVID: overall low grade inflammation and T-lymphocyte senescence and increased monocyte activation correlating with increasing fatigue severity. Frontiers in Immunology. 2023; 14:1254899. 10.3389/fimmu.2023.1254899
43. Scott NA, Pearmain L, Knight SB, et al. Monocyte migration profiles define disease severity in acute COVID-19 and unique features of long COVID. European Respiratory Journal. 2023; 61(5). 10.1183/13993003.02226-2022
44. Gallenga CE, Maritati M, Mura M, Di Virgilio F, Conti P, Contini C. Macrophage Activation in Follicular Conjunctivitis during the COVID-19 Pandemic. Microorganisms. 2023; 11(9):2198. 10.3390/microorganisms11092198
45. Barnish MS, Turner S. The value of pragmatic and observational studies in health care and public health. Pragmatic and observational research. 2017; 8:49-55. 10.2147/POR.S137701
46. Benson K, Hartz AJ. A comparison of observational studies and randomized, controlled trials. New England Journal of Medicine. 2000; 342(25):1878-1886. 10.1056/NEJM200006223422506
47. Black N. Why we need observational studies to evaluate the effectiveness of health care. Bmj. 1996; 312(7040):1215- 1218. 10.1136/bmj.312.7040.1215
48. Thurner C, Stengel A. Long-COVID syndrome: physical–mental interplay in the spotlight. Inflammopharmacology. 2023; 31(2):559-564. 10.1007/s10787-023-01174-4.
49. Brindisino F, Garzonio F, Di Giacomo G, Pellegrino R, Olds M, Ristori D. Depression, fear of re-injury and kinesiophobia resulted in worse pain, quality of life, function and level of return to sport in patients with shoulder instability: a systematic review. J Sports Med Phys Fitness. 2023; 63(4): 598-607. 10.23736/S0022-4707.22.14319-7

European Journal of Musculoskeletal Diseases
ISSN 2038-4106 print - ISSN 2975-044X online

Retrospective Observational Study

INTEGRATED APPROACH IN CHRONIC PAIN FROM MUSCULOSKELETAL STIFFNESS: MUSIC THERAPY AND VIBRO-ACOUSTIC PLATFORM

G. Barassi[1*], R. Pellegrino[2], G.L. Matera[1], L. Prosperi[1], A. Younes[1], V. Guglielmi[1], M. Cuozzo[1], C. Parone[3], A. Di Iorio[4] and M. Panunzio[5]

[1] Center for Physiotherapy, Rehabilitation and Re-Education (Ce.Fi.R.R.) venue "G. d'Annunzio" University of Chieti-Pescara, Chieti, Italy;
[2] Department of Scientific Research, Campus Ludes, Off-Campus Semmelweis University, Lugano, Switzerland;
[3] Professional Teaching, Course in Occupational Therapy, School of Medicine and Health Sciences, "G. d'Annunzio" University of Chieti-Pescara, Chieti;
[4] Antalgic Mini-Invasive and Rehab-Outpatients Unit, Department of Innovative Technologies in Medicine & Dentistry, "G. D'Annunzio" University of Chieti-Pescara, Chieti, Italy;
[5] Responsible Research Hospital, Campobasso, Italy.

**Correspondence to*:
Giovanni Barassi,
Center for Physiotherapy, Rehabilitation and Re-Education (Ce.Fi.R.R.),
"G. d'Annunzio" University of Chieti-Pescara,
66013, Chieti, Italy.
e-mail: coordftgb@unich.it

ABSTRACT

Music Therapy (MT) can be used in the presence of many pathologies. It has the ability to stimulate the organism both through the acoustic vibrations transmitted by the auditory system and through the mechanical vibrations picked up by the somatic mechanoreceptors. Therefore, we observed data relating to 20 patients (average age 69.6±10.8 years) suffering from painful musculoskeletal rigidity subjected to a treatment session consisting of the administration of 6 relaxing songs through a specific Vibroacoustic Therapy (VT) platform. Half of the patients (n=10) carried out the session with music + vibrations (Intervention, INT) while the other half (n=10) of the sample carried out the session with music only (Control, CONT). Patients were evaluated before and after the session using Digital Algometry (ALG) at the lumbar paravertebral level and evaluation of Heart Rate (HR) and Blood Oxygen Saturation (SpO2) with digital pulse-oximeter. At the end of the session, it was observed that the ALG value detected tended to rise in INT patients, with more mixed results for CONT. As regards the HR, INT highlighted a lower reduction in the value compared to the CONT. Regarding SpO2, INT showed a slight increase in the value, in contrast to the slight reduction highlighted in CONT. Therefore, it is possible to state that MT has modulation effects on pain and basic vital parameters both when administered in the form of music alone and when administered as a combination of music and contact vibration.

KEYWORDS: *muscle rigidity, chronic pain, music therapy, vibrations*

Received: 26 July 2024
Accepted: 16 September 2024

ISSN 2038-4106 print
ISSN 2975-044X online Copyright © by BIOLIFE 2024
This publication and/or article is for individual use only and may not be further reproduced without written permission from the copyright holder. Unauthorized reproduction may result in financial and other penalties. Disclosure: All authors report no conflicts of interest relevant to this article.

INTRODUCTION

Vibroacoustic Therapy (VT), as a branch of Music Therapy (MT), represents a relatively new method in the rehabilitation and occupational area since its foundations were laid in the second half of the 20th century. It uses low-frequency sound (generally in the range between 30 and 120 Hz) in the audible range to produce mechanical vibrations, unlike methods that use only infrasonic frequencies (below 20 Hz), which are inaudible to the human ear (1-3). These vibrations are then transmitted to the body of the person undergoing treatment by direct contact with a platform equipped with speakers. This system ensures that therapeutic music is not only perceived by the auditory system as a sound vibration but also as a tactile vibration by many somatic mechanoreceptors due to the direct contact with the transduction platform itself.

The distinctive feature of VT is the use of low-frequency vibrations in conjunction with listening to music, similar to Whole-Body Vibrations (WBVs), which are typically applied while standing on an oscillating platform that moves the individual and alters the gravitational forces acting on the body to produce a modification of muscle tone- tropism (4). Similar effects can be observed for Focused Mechano-Acoustic Vibrations (FMAVs) therapy, which applies localized vibrations at the muscular level produced by air pressure variations inside cups positioned on the patient's body and connected to a turbine (5).

In the field of MT, it is possible to differentiate low-frequency selective music from full-frequency music. Low-frequency music uses specific frequencies for vibroacoustic stimulation, such as that produced by Skille's equipment (6), while full-frequency music uses a single sound source and plays music using a wide range of frequencies, as is the case with the musical vibration platform by Chesky (7).

Regarding selective low-frequency stimulations, an important issue is related to the selection of suitable frequencies. Although Skille formulated a set of seven frequencies, this set is simply based on practical experiences and lacks theoretical support (6, 8). However, it has been shown that this therapeutic combination has positive effects on muscle tone and pain (6).

Music is a therapeutic means capable of determining a series of effects in a multitude of pathological contexts, ranging from the improvement of cardiovascular parameters (9) and the quality of sleep (10) to the reduction of muscle hypertonicity (11).

These therapeutic properties of music could be very useful in some pathologies, particularly in the presence of muscle hypertonicity and musculoskeletal stiffness associated with chronic widespread pain. On several occasions, music therapy has proven effective in reducing muscle tension and pain perceived by some types of patients (12-14), as has been achieved by vibratory treatments.

It is assumed that VT can determine its therapeutic effects through different mechanisms. First of all, vibratory stimulation is received in the body by specific mechanoreceptors, in particular the Pacinian Corpuscles, which have pain modulation properties and tactile/vibratory perception activity and are sensitive to a wide frequency range, between 60 and 600 Hz (15). Furthermore, the combination of music and tactile vibration as a therapeutic stimulus would seem to have a strong suppression effect on afferent and efferent neuronal pain activation, as well as an action on pain perception at the level of the Central Nervous System (15), presumably due to a phenomenon of synchronization of neuronal activity with the vibrational frequencies of the treatment.

Given the potential therapeutic properties of MT and VT, in this study, we wanted to observe how they could modulate pain and some basic vital parameters in patients suffering from widespread musculoskeletal stiffness associated with pain.

MATERIALS AND METHODS

This retrospective observational study was conducted in the period from May to October 2021 at Ce.Fi.R.R. (Center for Physiotherapy, Rehabilitation, and Re-education), located in the headquarters of the “G. d'Annunzio" University of Chieti-Pescara.

Data were collected from 20 patients aged between 51 and 82 years (mean 69.6±10.8 years) who had received a medical diagnosis of diffuse musculoskeletal stiffness associated with chronic musculoskeletal pain.

The rehabilitation protocol to which the patients were subjected is safe; it is accessible to all patients who do not highlight specific contraindications to the initial clinical evaluation necessary for all patients who access the facility where the study is carried out; furthermore, the protocol does not constitute an experimental practice, as it is the same therapeutic protocol used for all patients who do not present the aforementioned contraindications. The study was conducted in accordance with the ethical principles outlined in the Declaration of Helsinki. Written informed consent was obtained at enrolment from willing and able participants; alternatively, informed consent was obtained from caregivers. Because of all these considerations and the lack of incontrovertible national legislation regarding the need to submit retrospective

and/or non- pharmacological observational studies to an ethics committee, the normal ethics committee clearance was not required (16).

People with active cancer, pacemakers, and atrial fibrillation were excluded from the study. Furthermore, all subjects who were affected by deafness, cardiovascular disorders, recent stroke, convulsions, shock, and treatment with drugs that modify cardiac autonomic regulation were also excluded from the research.

Of the 20 patients observed, 10 underwent an MT session without vibrations (Control, CONT), and 10 underwent a VT session (Intervention, INT). Given the observational nature of the study, there was no randomization of patients; we simply proceeded with the data analysis once an equivalent number of patients who received an MT or VT prescription had been reached. The evaluation tools used before (T0) and after the therapeutic session (T1) were:

- pressure Algometer (ALG) (F-Meter, Storz Medical AG, Tägerwilen, Switzerland): it was used to detect the pressure- pain threshold of the patient for specific assessment points (17). The device was pointed locally and bilaterally at the level of the lumbar paraspinal muscles, approximately at the point between the L3 and L4 vertebrae. After that, the therapist applied progressive pressure with the tip of the device until the patient reported a pain sensation. The level of pain reached was then read on the display and marked as a pressure-pain threshold for that patient at that point, with each unit of pressure consisting of about 200g of applied weight. The algometer has proven useful for evaluating muscle tenderness in patients affected by painful chronic tone abnormalities, such as in the case of fibromyalgia and other myofascial syndromes (18, 19);
- digital Pulse-oximeter: (YK-81CEU, Braun GmbH, Kronberg, Germany). It is an indirect and non-invasive method that allows to measure oxygen saturation of the hemoglobin present in the arterial blood (SpO2) as well as additional data on other vital parameters of the patient, such as the heart rate (HR), the plethysmographic curve and the perfusion index. In particular, to monitor changes in vital parameters of observed patients after the treatment, SpO2 (%) and HR (Beats per minute, Bpm) data were collected (20). The evaluation of basic vital parameters, such as SpO2 and HR, are considered indicators of the state of psycho-emotional and, consequently, musculoskeletal relaxation in humans (21, 22) and have often been used in the field of VT for monitoring the effects of relaxation possibly induced by the treatment (23, 24).

The therapeutic session was carried out in both groups and observed using the Music Vibration Platform (MVP). This instrument, which was positioned in a specific acoustically isolated room within the premises of the study, is composed of an audio system, a hollow wooden platform (dimensions: 125x200x54 cm), a computerized system for processing the transmitted vibrations, and a vibrating membrane. The platform was explicitly handcrafted to meet the operational needs of the center where the study was carried out.

The MVP can modulate the emission of vibratory stimuli in terms of intensity through a feedback mechanism based on detecting the patient's weight and its distribution once lying on the platform itself. The precision of the setting is guaranteed by an automatic calibration carried out with sensors, which can be performed at each treatment session to compensate for differences in weight and general positioning between subjects lying on the platform.

The vibrating membrane comprises 3 components, which are located respectively under the back, under the thighs, and the legs of the patient. The membranes transmit contact vibrations determined by the low frequencies of the musical pieces played to the body of the patient. Instead, the auditory perception of the songs played is entrusted to a set of over-ear headphones. The vibrational system and the headphones are connected to the same musical source. They can be separated to work simultaneously (true VT), only with headphones (pure MT), or only with vibrations (almost WBVs).

Given that individual physiological responses to musical stimuli vary due to the unique physiological and psychological reactivity systems of each person, it was necessary to use a musical selection chosen by the experimenters, which did not have an influence on the emotionality of the patient (i.e., songs that are fundamentally recognized as relaxing but unknown to him) to obtain an unconditioned physiological response. The songs selected for the treatment sessions were the following both for CONT and INT:

1.“Nuvole Bianche” by Ludovico Einaudi (Duration: 6’05”, Peak Frequency: 103 Hz)
2. “People Help the People” by Birdy (Duration: 4’18”, Peak Frequency: 92 Hz)
3. “Caribbean Blue” by Enya (Duration: 3’57”, Peak Frequency: 110 Hz)
4. “Midnight” by Coldplay (Duration: 5’07”, Peak Frequency: 46 Hz)
5. “Weightless” by Marconi Union (Duration: 8’09”, Peak Frequency: 110 Hz)
6. “Remember Me” by Thomas Bergensen (Duration: 4’29”, Peak Frequency: 54 Hz)

The selected pieces were chosen based on their coherence with the definition of "relaxing or sedative music" generally accepted in literature, which defines it as music characterized by slow tempo, repetitive rhythm, gentle contours, and, eventually, strings (25, 26).

By starting playback of the audio sequence on the device, it is transmitted to the mixer, which sends the signal directly to the membranes in the Music Vibration Table and to the relative headphones.

To perform the treatment, the patient was made to lie down on the platform, in the center of it, in a supine and comfortable position. The patient was given 1-2 minutes of settling time on the platform and was then subjected to listening to the musical selection in the form of music + vibrations in the INT group and music only in the CONT group.

At the end of the session, the patient was asked to stand up calmly after 1 or 2 minutes from the end of the last song. The same therapist assigned to the role carried out all the accommodation procedures, treatment set-ups, and session monitoring.

Excel software (Microsoft, Redmond, Washington, U.S.A.) was used to analyze the data. The means of the observed values and the T-Test statistical significance were calculated for data obtained with the Algometer and the Pulse- oximeter. The corresponding p-value represents the possibility of observing a quantity different from the one observed; if the p-value is extremely small (≤0.05), the variation of the parameter under examination between T0 and T1 is assumed to be significant.

RESULTS

Pressure algometer (ALG)

In the INT group, the pain threshold (ALG) increased in the right hemisome by 5.8% in a non-statistically significant manner (from 15.4 ± 12.6 to 16.3 ± 13.2 points, p=0.722); in the left hemisome, it increased significantly by 26.4% (from 12.5 ± 10 to 15.8 ± 10.3 points, p=0.001).

In the CONT group, however, the ALG value decreased in the right hemisome by 13.8% in a non-statistically significant manner (from 9.4 ± 10.1 to 8.1 ± 7.7 points, p=0.519). In the left hemisome, however, the ALG value increased by 12.7% in a non-statistically significant manner (from 6.3 ± 4.7 to 7.1 ± 5.7 points, p=0.23).

Heart rate (HR)

In the INT group, the HR value decreased by 4.4% (from 76.4 ± 18.7 to 73 ± 13.2 Bpm) in a non-statistically significant manner (p=0.24). In the CONT group, the HR significantly decreased by 9.6% (from 77.9 ± 11.1 to 70.4 ± 13.4 Bpm, p=0.004).

Oxygen saturation (SpO2)

The SpO2 value in the INT group increased by 0.2% (from 96 ± 1.8 to 96.2 ± 4.6 percent) in a non-statistically significant manner (p=0.891). In the CONT group, SpO2 decreased by 0.1% (from 96.8 ± 0.9 to 96.7 ± 1.1 percent) in a non-statistically significant manner (p=0.853).

DISCUSSION

The present study demonstrates how both MT (CONT) and VT (INT) are able, through a single treatment session, to produce changes in pressure pain (ALG) and vital parameters (HR and SpO2) in patients with musculoskeletal stiffness and chronic pain. These effects, however, reach a different magnitude between the two types of neuro-sensory stimulations, and, in general, the effect of a single session produced significant variations only in 2 cases: in the raising of the pressure pain threshold of the left lumbar paravertebral point in INT patients and the decrease in HR in CONT patients.

The greater increase in ALG values in INT patients appears to be consistent with a summation effect of the analgesic properties of music and the vibrations produced by the appropriate treatment platform. A potential analgesic effect induced by music has already been described in the literature, especially if generally identifiable as relaxing (12), probably based on psycho-emotional factors connected to a possible involvement of the limbic system as a moderator of abnormal pain stimuli (12). Furthermore, therapeutic vibrations have also often been associated with analgesic effects; this phenomenon could have both a direct nature due to phenomena of perceptive overlap between pain and vibration (27) in accordance with the "gate control theory" (28) and an indirect nature due to the ability to modulate muscle tone: in fact, the increase of muscular tone over time tends to be associated with forms of chronic musculoskeletal pain (29).

Regarding basic vital parameters, a greater reduction in HR was observed in CONT compared to INT (10% vs 3%). Current literature would seem to suggest that low-frequency vibrations should induce parasympathetic adaptations capable of reducing HR in humans (30). However, in our case, CONT, not subjected to contact vibrations, showed a greater reduction in the HR value, albeit remaining within a clinical normal range. It could be hypothesized that since our

patients had a relatively high mean age (69.6±10.8 years), the sample observed could have presented an alteration in tactile and vibratory sensitivity due to aging factors (31,32).

Finally, regarding SpO2 values, a slight reduction in the value was observed in CONT, in contrast to a slight increase in the same in INT. This difference, even if clinically irrelevant, could be due to a potential improvement of the oxygenation of the blood circulation induced by the vibrations applied using a vibroacoustic platform in INT (33,34). The particularities of the results obtained from the observed sample could be traced back to the existence of a state of inflammaging (35). This condition includes a chronic onset of low-grade inflammation and a decline in metabolic function (36) in the whole organism (37). Inflammaging plays a key role in the pathogenesis of age-related diseases and is accompanied by a "2-fold-to-4-fold" increase in plasma levels of pro-inflammatory mediators in healthy elderly people compared to the healthy adult population.

Accepting the definition of pain as an unpleasant sensory and emotional experience associated with actual or potential tissue damage and described in terms of such damage, as defined by the International Association for the Study of Pain, and recognizing the difference between pain-symptom, danger signal for the organism, and pain-illness, that is non-finalistic and disengaged from the primary cause (38), this study aims to bring new results obtained from customized treatment based on rigorous patient data framed in a holistic rehabilitation approach. We also took into account the original experiences of Maffei and his School (39,40), using elastic and/or mechanical waves (acoustic and tactile stimulation) as an endogenous pharmacotherapy.

The possibility of finding and applying new therapeutic approaches that are minimally invasive, easy to carry out, and relatively cheap is particularly important in the context of pathologies connected to chronic musculoskeletal pain and muscle and joint stiffness, which in severe cases may lead to non-musculoskeletal symptoms such as depression and kinesiophobia (41) and, sometimes, may require interventions based on more invasive approach such as surgery or infiltrative therapy (42).

Since the present study is characterized by an observational design and was carried out for a limited number of sessions, it is necessary to point out how the small and non-homogeneous sample observed, in relation to the single treatment session evaluated, could have influenced the significance of the results. However, given the apparent consistency of what was observed with what is currently known in the literature, it is appropriate to underline that the present study represents a new step in the perspective of studying interesting rehabilitation techniques such as MT and VT in the context of chronic pain from musculoskeletal stiffness.

CONCLUSIONS

The study highlighted how both MT and VT administered with a Music Vibration Platform are able to induce, in the short term, positive, although not always significant, changes in the health status of patients suffering from chronic pain resulting from musculoskeletal stiffness. However, given the limitations of this research project, it would be important to conduct further studies on the subject, possibly in an RCT-type setting with a larger and more homogeneous sample and the presence of a control group and a follow-up, to better clarify the medium-long term effectiveness of the treatment methods observed.

Conflict of interest

The authors declare that they have no conflict of interest.

REFERENCES

1. Ahonen H. Low-frequency research—Client populations and common frequencies used—Literature review. Laurier Centre Music Ther. Res. Newsl. 2007; 4:1–5.
2. Hooper J. An introduction to vibroacoustic therapy and an examination of its place in music therapy practice. British Journal of Music Therapy. 2001; 15(2):69-77. https://doi.org/10.1177/135945750101500205
3. Punkanen M, Ala-Ruona E. Contemporary vibroacoustic therapy: Perspectives on clinical practice, research, and training. Music and Medicine. 2012; 4(3):128-135. https://doi.org/10.1177/1943862112445324
4. Saldıran TÇ, Atıcı E, Rezaei DA, Öztürk Ö, Uslu B, Özcan BA, Okudan B. The acute effects of different intensity whole-body vibration exposure on muscle tone and strength of the lower legs, and hamstring flexibility: A pilot study. Journal of Sport Rehabilitation. 2020; 30(2): 235-241. 10.1123/jsr.2019-0408.

5. Prosperi L, Barassi G, Panunzio M, et al. Bio-Physics approach to urinary incontinence disabilities. International Journal of Environmental Research and Public Health. 2022; 19(19):12612. 10.3390/ijerph191912612
6. Skille O. Manual of Vibroacoustics. ed. ISVA Publications. Levanger, 1986.
7. Chesky KS, Michel DE. The Music Vibration Table (MVT™): Developing a technology and conceptual model for pain relief. Music Therapy Perspectives. 1991; 9(1):32-38. https://doi.org/10.1093/mtp/9.1.32
8. Bartel LR, Chen R, Alain C, Ross B. Vibroacoustic stimulation and brain oscillation: from basic research to clinical application. Music and Medicine. 2017; 9(3):153-166.
9. Mir IA, Chowdhury M, Islam RM, Ling GY, Chowdhury AA, Hasan ZM., Higashi Y. Relaxing music reduces blood pressure and heart rate among pre-hypertensive young adults: A randomized control trial. The Journal of Clinical Hypertension. 2021; 23(2):317-322. 10.1111/jch.14126
10. Cordi MJ, Ackermann S, Rasch B. Effects of relaxing music on healthy sleep. Scientific reports. 2019: 9(1):9079.
11. Van Criekinge T, D'Août K, O'Brien J, Coutinho E. Music and hypertonia: can music listening help reduce muscle tension and improve movement quality? Music & Science. 2021; 4:20592043211015353.
12. Leão ER, da Silva MJP. The relationship between music and musculoskeletal chronic pain. Online Brazilian Journal of Nursing. 2005; 4(1):9-19. https://doi.org/10.17665/1676-4285.20054799
13. Cacnio MKB, Edquiban HA, Fontamillas TME, Medina FN, Santos FRR. The effectiveness of music therapy in the reduction of low back pain due to musculoskeletal disorders. Health Sciences Journal. 2013; 2(1):1.
14. Wei M. Music as an effective intervention to muscle tone. Paper presented at: 2021 International Conference on Biomedical Engineering, Healthcare and Disease Prevention (BEHDP 2021); 12 11-12, 2021, Xiamen, China.
15. Boyd-Brewer C, McCaffrey R. Vibroacoustic sound therapy improves pain management and more. Holistic Nursing Practice. 2004; 18(3):111-118.
16. Winter EM, Maughan RJ. Requirements for ethics approvals. J Sports Sci 2009; 27(10):985. 10.1080/02640410903178344
17. Kinser AM, Sands WA, Stone MH. Reliability and validity of a pressure algometer. The Journal of Strength & Conditioning Research. 2009; 23(1):312-314. 10.1519/jsc.0b013e31818f051c
18. Fischer AA. Algometry in the daily practice of pain management. Journal of Back and Musculoskeletal Rehabilitation. 1997; 8(2):151-163. 10.3233/BMR-1997-8209
19. de la Coba P, Montoro CI, Reyes del Paso GA, Galvez-Sanchez CM. Algometry for the assessment of central sensitisation to pain in fibromyalgia patients: a systematic review. Annals of medicine. 2022; 54(1):1403-1422. 10.1080/07853890.2022.2075560
20. Tremper KK. Pulse oximetry. Chest. 1989; 95(4):713-715. https://doi.org/10.1378/chest.95.4.713
21. France CR, France JL, Patterson SM. Blood pressure and cerebral oxygenation responses to skeletal muscle tension: a comparison of two physical maneuvers to prevent vasovagal reactions. Clinical physiology and functional imaging. 2006; 26(1):21-25. 10.1111/j.1475-097X.2005.00642.x
22. Davis J, Feldman RI, Traylor MK, Gray SM, Drake SM, Keller JL. Myofascial release induces declines in heart rate and changes to microvascular reactivity in young healthy adults. Journal of Bodywork and Movement Therapies. 2024; 38:254-262. 10.1016/j.jbmt.2024.01.006
23. Koike Y, Hoshitani M, Tabata Y, Seki K, Nishimura R, Kano Y. Effects of vibroacoustic therapy on elderly nursing home residents with depression. Journal of Physical therapy science. 2012; 24(3):291-294. 10.1589/jpts.27.2069
24. Skille O, Wigram T. The effect of music, vocalisation and vibration on brain and muscle tissue: studies in vibroacoustic therapy. In Art & Science of Music Therapy. T. Wigram, B. Saperston, R. West, ed. Routledge. London, 2013; pp. 23-57.
25. Knight WE, Rickard NS. Relaxing music prevents stress-induced increases in subjective anxiety, systolic blood pressure, and heart rate in healthy males and females. Journal of music therapy. 2001; 38(4):254-272. 10.1093/jmt/38.4.254
26. Korhan EA, Uyar M, Eyigör C, Yönt GH, Çelik S, Khorshıd L. The effects of music therapy on pain in patients with neuropathic pain. Pain Management Nursing. 2014; 15(1):306-314. 10.1016/j.pmn.2012.10.006
27. Hollins M, McDermott K, Harper D. (2014). How does vibration reduce pain? Perception. 2014; 43(1):70-84. https://doi.org/10.1068/p7637
28. Kuwahara H, Ogawa R. Using a vibration device to ease pain during facial needling and injection. Eplasty, 2016; 16.

29. Mense S, Masi AT. (2010). Increased muscle tone as a cause of muscle pain. Muscle pain: understanding the mechanisms. 2010; 207-249. https://doi.org/10.1007/978-3-540-85021-2_6
30. Wik I. (2021). Effects of low-frequency vibration relaxation treatment on heart rate variability. Dissertation. Tampere University; 2021.
31. Stuart M, Turman AB, Shaw J, Walsh N, Nguyen V. Effects of aging on vibration detection thresholds at various body regions. BMC geriatrics. 2003; 3:1-10. 10.1186/1471-2318-3-1
32. Shaffer SW, Harrison AL. (2007). Aging of the somatosensory system: a translational perspective. Physical therapy. 2007; 87(2):193-207. https://doi.org/10.2522/ptj.20060083
33. Aoyama A, Yamaoka-Tojo M, Obara S, et al. Acute Effects of Whole-Body Vibration Training on Endothelial Function and Cardiovascular Response in Elderly Patients with Cardiovascular Disease: a Single-Arm Pilot Study. International heart journal. 2019; 60(4):854-861. 10.1536/ihj.18-592
34. Games KE, Sefton JM, Wilson AE. Whole-body vibration and blood flow and muscle oxygenation: a meta-analysis. Journal of athletic training. 2015; 50(5):542-549. 10.4085/1062-6050-50.2.09
35. Kruglov V, Jang IH, Camell CD. Inflammaging and fatty acid oxidation in monocytes and macrophages. Immunometabolism. 2024; 6(1):e00038. 10.1097/IN9.0000000000000038
36. Franceschi C, Bonafè M, Valensin S, et al. Inflamm-aging: an evolutionary perspective on immunosenescence. Annals of the new York Academy of Sciences. 2000; 908(1):244-254. 10.1111/j.1749-6632.2000.tb06651.x
37. Gallenga CE, Parmeggiani F, Costagliola C, Sebastiani A, Gallenga PE. Inflammaging: should this term be suitable for age related macular degeneration too? Inflammation Research. 2014; 63:105-107. 10.1007/s00011-013-0684-2
38. Gallenga PE, Vecchiet L. Il dolore in oftalmologia. Quaderni SOI. Artemisia ed. Guidonia; 2004.
39. Maffei L. Environmental enrichment and neural plasticity. International Journal of Psychophysiology. 2012; 85(3):283–284. 10.1016/j.ijpsycho.2012.07.177
40. Sale A, Berardi N, Maffei L. Environment and Brain Plasticity: Towards an Endogenous Pharmacotherapy. Physiological Reviews. 2014; 94(1):189-234. 10.1152/physrev.00036.2012
41. Brindisino F, Garzonio F, Di Giacomo G, Pellegrino R, Olds M, Ristori D. Depression, fear of re-injury and kinesiophobia resulted in worse pain, quality of life, function and level of return to sport in patients with shoulder instability: a systematic review. J Sports Med Phys Fitness. 2023; 63(4): 598-607. 10.23736/S0022-4707.22.14319- 7
42. de Sire A, Lippi L, Mezian K, Calafiore D, Pellegrino R, Mascaro G, Cisari C, Invernizzi M. Ultrasound-guided platelet-rich-plasma injections for reducing sacroiliac joint pain: A paradigmatic case report and literature review. J Back Musculoskelet Rehabil. 2022; 35(5):977-982. 10.3233/BMR-210310

European Journal of Musculoskeletal Diseases
ISSN 2038-4106 print - ISSN 2975-044X online

Letter to the Editor

CLEIDOCRANIAL DYSPLASIA AND DENTAL IMPLANTS

C. Annicchiarico[1*], A. Annicchiarico[1], A. Coppola[2] and R. Padula[3]

[1] Independent Researcher, University of Bari, 70100 Bari, Italy;
[2] Private practice, Studio Armando Coppola, Corso Garibaldi 246, 80141 Naples, Italy;
[3] Clinical and experimental biology, University of Foggia, Foggia, Italy.

**Correspondence to*:
Ciro Annicchiarico,
Independent Researcher,
University of Bari,
70100 Bari, Italy.
e-mail: annichiarico.ciro63@gmail.com

KEYWORDS: *cleidocranial dysplasia, dental implant, RUNX2, osseointegration, teeth*

INTRODUCTION

Cleidocranial dysplasia (CCD) is a rare genetic disorder that primarily affects the generation of bones and teeth. CCD is caused by mutations in the RUNX2 gene, which is essential for bone and cartilage formation and tooth development (1). The disease can disrupt normal bone remodeling and repair mechanisms. This abnormal biological reaction not only alters bone formation, but also involves an immune reaction with inflammatory responses. CCD affects both skeletal and dental structures, with severe disruption of calcium metabolism. Various dysfunctions may occur such as supernumerary teeth and delayed formation of permanent teeth. In addition, the patient may have an underdeveloped upper jaw and a protruding lower jaw (prognathic). CCD may also present hypoplasia of the jaw bones with an impact on the placement of dental implants and delayed formation of permanent teeth complicates standard orthodontic or prosthetic treatments.

DISCUSSION

Implants require osseointegration, a process which can generate an *in-situ* immune reaction and acute inflammation that can progress to chronic inflammation. CCD is a rare genetic disorder caused by mutations in the RUNX2 gene. This gene is essential for bone and cartilage formation and the development of teeth, and CCD primarily affects the generation of bones and teeth. CCD patients with chronic inflammation or impaired wound healing have limited osseointegration between bone and the titanium surface of implants (2).

The RUNX2 genetic mutation can alter the activity of osteoclasts and osteoblasts, affecting the balance between bone formation and resorption (3). In CCD, the supernumerary teeth can be a vulnerable site for bacterial infections that affect the entire oral cavity; this increases the risk of infections surrounding dental implants (4). Moreover, the lack of bone in this disease can increase the inflammatory effect, with destruction of the tissues around the implant, inducing peri-implantitis.

The increased vulnerability to the inflammatory process that occurs in CCD influences the production of cytokines with alteration of the RANK-ligand (RANK-L)-Osteoprotegerin (OPG) axis. RANK-L is a protein of the tumor necrosis factor (TNF) family that is produced by osteoblasts after various stimuli, which can include that by cytokines, growth factors, and/or hormones. The RANK-L ligand is produced by stimulated osteoblasts and binds to its specific RANK

Received: 02 September, 2024
Accepted: 28 November, 2024

ISSN 2038-4106 print
ISSN 2975-044X online Copyright © by BIOLIFE 2024
This publication and/or article is for individual use only and may not be further reproduced without written permission from the copyright holder. Unauthorized reproduction may result in financial and other penalties. Disclosure: All authors report no conflicts of interest relevant to this article.

receptor expressed on osteoblasts and osteoclasts. This effect is necessary for the maturation and survival of osteoclasts that carry out the activity of bone resorption.

OPG is structurally similar to RANK and acts as a decoy receptor by binding RANK-L and blocking its biological activities. The life and activity of osteoclasts depends on the ratio between RANK-L and OPG. In fact, when there is an excess of RANK-L, bone resorption prevails. However, when OPG levels are higher than those of RANK-L, bone resorption is slowed down. Therefore, bone remodeling is characterized by a balance between resorption and neoformation of the mineralized bone matrix.

In CCD, inflammation and the abnormal immune response can alter the activation of nuclear factor-kappa B (NF-κB), with dysregulated production of cytokines and growth factors. Macrophages and T cells are amongst the immune cells involved in this inflammatory process, and their activity could delay healing after implant surgery and hinder the successful outcome of the implant. CCD requires surgical extraction of supernumerary teeth and orthodontic alignment, with grafts and bone volume augmentation in case of abnormal maxillary bone density. Implants may need customization depending on the bone alteration. The use of modified implants could be useful for improving osseointegration and reducing inflammation. The use of anti-inflammatories or immune response modulators could be useful to prevent implant rejection (5). Additionally, the role that RUNKX2 plays in the immune process needs to be further investigated. Using implants with biological coatings and antibiotic treatments could improve the outcome of implants in patients with CCD. Therapies aimed at RUNX2 dysregulation could give better results both at the inflammatory and immunological level.

CONCLUSIONS

Future studies will help to further elucidate the mechanisms that occur in CCD. These may improve the results that are achieved in dental implantology. A combined study involving orthodontics, surgery, and immune system and inflammatory inhibition may significantly improve the available therapy for patients affected by CCD.

Conflict of interest

The author declares that they have no conflict of interest.

REFERENCES

1. Jonason JH, Xiao G, Zhang M, Xing L, Chen D. Post-translational Regulation of Runx2 in Bone and Cartilage. *Journal of Dental Research*. 2009;88(8):693-703. doi:https://doi.org/10.1177/0022034509341629
2. Mastrangelo F, Gastaldi G, Vinci R, et al. Immediate Postextractive Implants With and Without Bone Graft. *Implant Dentistry*. 2018;27(6):638-645. doi:https://doi.org/10.1097/id.0000000000000816
3. Muzio LL, Stefano Tetè, Mastrangelo F, et al. A novel mutation of gene CBFA1/RUNX2 in cleidocranial dysplasia. *PubMed*. 2007;37(2):115-120.
4. Tetè S, Mastrangelo F, Traini T, et al. A Macro- and Nanostructure Evaluation of a Novel Dental Implant. *Implant Dentistry*. 2008;17(3):309-320. doi:https://doi.org/10.1097/id.0b013e318182d494
5. Sammartino G, Marenzi G, Tammaro L, et al. Anti-inflammatory drug incorporation into polymeric nano-hybrids for local controlled release. *PubMed*. 2006;18(3 Suppl):55-62.

European Journal of Musculoskeletal Diseases
ISSN 2038-4106 print - ISSN 2975-044X online

GINGIVA INFECTION AND INFLAMMATION CAN LEAD TO PERIODONTAL DISEASE AND AUTOIMMUNITY

A. Coppola[1], R. Padula[2], A. Annicchiarico[3] and C. Annicchiarico[3*]

[1] Private practice, Studio Armando Coppola, Corso Garibaldi 246, 80141 Naples, Italy;
[2] Clinical and experimental biology, University of Foggia, Foggia, Italy;
[3] Independent Researcher, University of Bari, 70100 Bari, Italy.

**Correspondence to*:
Ciro Annicchiarico,
Independent Researcher,
University of Bari,
70100 Bari, Italy.
e-mail: annichiarico.ciro63@gmail.com

KEYWORDS: *Autoimmunity, immune system, periodontal disease, porphyromonas gingivalis, inflammation*

INTRODUCTION

In autoimmunity, the immune system mistakenly targets the body's tissues and causes damage (1). Autoimmunity is a group of very common diseases which occur in response to the body's production of antibody-producing B lymphocytes and T lymphocytes against self-antigens or auto-antigens. With autoimmunity, the immune system does not recognize the body's self-antigens, such as proteins and nucleic acids, which develop autoantibodies. B cells participate in the disease by producing autoantibodies, while T cells intervene as autoreactive lymphocytes. Autoreactive T cells and autoantibodies can be present in individuals with no clinical disease state.

DISCUSSION

Autoimmunity and gum infection can occur in periodontal disease. In gingival infection and periodontitis, autoimmunity can play an exacerbating role in tissue destruction (2). In addition, dental implants can become infected with bacteria and infection can open the way for autoimmune diseases (3,4).

Porphyromonas gingivalis belongs to the phylum Bacteroidota and is a non-motile, rod-shaped, Gram-negative, anaerobic pathogenic bacterium. It is found in the oral cavity, as well as the upper gastrointestinal tract, respiratory tract, and colon, where it is implicated in periodontal disease. *P. gingivalis* participates in collagen degradation in periodontal disease, can infect gingival epithelial cells, and is resistant to antibiotics (5).

P. gingivalis invades gingival epithelial cells in large numbers, in which case both bacteria and epithelial cells survive for long periods. High levels of specific antibodies can be detected in patients harboring *P. gingivalis*. The bacterium produces antigens similar to those produced by host tissues, leading the immune system to attack both microbial and autologous antigens (6). Some bacterial proteins such as bacterial heat shock proteins (HSPs) can mimic human HSPs, triggering autoimmunity.

Microbial infection induces inflammation that exposes autologous proteins to immune cells, triggering an autoimmune reaction with activation of T and B lymphocytes that attack periodontal tissues. Autoantibodies can attack gingival collagen of connective tissue, causing inflammation and tissue dysfunction. The activation of CD4+ T-helper lymphocytes, Th1 and Th17, leads to a high secretion of inflammatory cytokines such as interleukin (IL)-1, TNF, IL-6 and IL-17, resulting in tissue destruction. The intervention of regulatory T cells (Tregs) cannot adequately suppress the immune

Received: 12 September, 2024
Accepted: 11 November, 2024

ISSN 2038-4106 print
ISSN 2975-044X online Copyright © by BIOLIFE 2024
This publication and/or article is for individual use only and may not be further reproduced without written permission from the copyright holder. Unauthorized reproduction may result in financial and other penalties. Disclosure: All authors report no conflicts of interest relevant to this article.

response or inflammation. Activated B cells also participate in the autoimmune reaction by producing autoantibodies, such as anti-citrullinated protein antibodies (ACPAs) that target the gingival connective tissue.

Gum infections are usually triggered by a biofilm of bacteria on teeth and gums. The infection causes a strong immune and inflammatory response with tissue damage. Certain bacteria, including *P. gingivalis*, release enzymes such as collagenases that damage connective tissue.

Lipopolysaccharides (LPS) from Gram-negative bacterial cell walls stimulate an innate immune response via Toll-like receptors (TLRs). Prolonged activation of the immune system by a persistent infection leads to overproduction of cytokines, such as IL-1β, IL-6, and TNF, which degrade bone and periodontal tissues. Neutrophils also participate in inflammation by being recruited to the site of infection and releasing reactive oxygen species (ROS) and proteolytic enzymes. TLRs on immune cells recognize bacterial LPS, activating the NF-κB pathway to produce pro-inflammatory cytokines. CD4+ cells, particularly Th17, secrete IL-17, which recruits neutrophils and increases inflammation. Activation of osteoclasts via receptor activator of nuclear factor κ B (RANK) receptor signaling with RANK-L ligand, leads to alveolar bone resorption.

Bacteria produce enzymes such as citrulline that can act on proteins to generate new antigens that trigger autoimmunity. Protein citrullination can be increased by peptidylarginine produced by *P. gingivalis*, with increased levels of new antibodies. Immune tolerance can be impaired by chronic microbial infections, an effect that causes susceptibility to autoimmune reactions. During the infection process of the gingiva, ROS can be released that can damage both proteins and DNA of the host, with the formation of new antigens that can trigger autoimmunity. Bacterial infection causes inflammation with production of pro-inflammatory cytokines such as IL-1, TNF, IL-6, and IL-17, which can be followed by the generation of anti-inflammatory cytokines such as IL-10 and TGF-β (7). Bacterial products are recognized by TLR2 and TLR4 that activate the inflammatory process, and tissue damage is mediated by enzymes that degrade the extracellular matrix. Bone resorption is regulated by the RANK-RANK-L- osteoprotegerin (OPG) pathway, an effect that favors the activity of osteoclasts. Individuals with cleidocranial dysplasia (CCD) might develop secondary complications (e.g., chronic infections or inflammatory responses) that could mimic or contribute to autoimmune-like conditions, though these are not inherently part of CCD (8).

CONCLUSIONS

Inhibition of inflammatory cytokines can reduce inflammation, even that which occurs in autoimmunity. Reducing infection with antibiotics, with the restoration of the balance of immunity, can also be helpful. Experimental therapeutic effects involving stimulation of Tregs and suppression of inflammatory cytokines are still under investigation. The multifactorial reactions involving autoimmunity and infections of gingival tissue are very complex and require further studies.

Conflict of interest

The authors declare that they have no conflict of interest.

REFERENCES

1. Massironi S, Chiara Viganò, Palermo A, et al. Inflammation and malnutrition in inflammatory bowel disease. *The lancet Gastroenterology & hepatology*. 2023;8(6):579-590. doi:https://doi.org/10.1016/s2468-1253(23)00011-0
2. Kebschull M, Demmer RT, Papapanou PN. "Gum Bug, Leave My Heart Alone!"—Epidemiologic and Mechanistic Evidence Linking Periodontal Infections and Atherosclerosis. *Journal of Dental Research*. 2010;89(9):879-902. doi:https://doi.org/10.1177/0022034510375281
3. Mastrangelo F, Gastaldi G, Vinci R, et al. Immediate Postextractive Implants With and Without Bone Graft. *Implant Dentistry*. 2018;27(6):638-645. doi:https://doi.org/10.1097/id.0000000000000816
4. Tetè S, Mastrangelo F, Traini T, et al. A Macro- and Nanostructure Evaluation of a Novel Dental Implant. *Implant Dentistry*. 2008;17(3):309-320. doi:https://doi.org/10.1097/id.0b013e318182d494
5. Li Y, Guo R, Oduro PK, et al. The Relationship Between Porphyromonas Gingivalis and Rheumatoid Arthritis: A Meta-Analysis. *Frontiers in Cellular and Infection Microbiology*. 2022;12. doi:https://doi.org/10.3389/fcimb.2022.956417

6. Lin J, Huang D, Xu H, Zhan F, Tan X. Macrophages: A communication network linking Porphyromonas gingivalis infection and associated systemic diseases. *Frontiers in Immunology*. 2022;13. doi:https://doi.org/10.3389/fimmu.2022.952040
7. Sammartino G, Marenzi G, Tammaro L, et al. Anti-inflammatory drug incorporation into polymeric nano-hybrids for local controlled release. *International Journal of Immunopathology and Pharmacology*. 2006;18(3 Suppl):55-62.
8. Muzio LL, Stefano Tetè, Mastrangelo F, et al. A novel mutation of gene CBFA1/RUNX2 in cleidocranial dysplasia. *Annals of clinical and laboratory science*. 2007;37(2):115-120.

European Journal of Musculoskeletal Diseases
ISSN 2038-4106 print - ISSN 2975-044X online

Article

ANTI-INFLAMMATORY DRUG-LOADED POLYMERIC NANO-HYBRIDS HAVE SIGNIFICANT POTENTIAL IN THE FIELD OF DENTISTRY

A. Coppola[1*], R. Padula[2], A. Annicchiarico[3] and C. Annicchiarico[3]

[1] Private practice, Studio Armando Coppola, Corso Garibaldi 246, 80141 Naples, Italy;
[2] Clinical and experimental biology, University of Foggia, Foggia, Italy;
[3] Independent Researcher, University of Bari, 70100 Bari, Italy.

**Correspondence to*:
Armando Coppola,
Private practice, Studio Armando Coppola,
Corso Garibaldi 246,
80141 Naples, Italy.
e-mail: armandocoppola70@gmail.com

ABSTRACT

The role of anti-inflammatory drugs and polymer nano-hybrids in dentistry has attracted much interest. Nonsteroidal anti-inflammatory drugs (NSAIDs) are used in dentistry especially in pain management and gingival inflammation. These drugs have demonstrated their efficacy with acceptable and non-serious side effects. In addition, NSAIDs regulate the immune system and do not inhibit it, as occurs with steroid drugs. In dentistry, the combination of NSAIDs with polymer nano-hybrid molecules represents a new effective therapeutic treatment. Polymer nanohybrids are nanoscale materials composed of polymers and other compounds, and allow localized and sustained release of anti-inflammatory drugs, and increased retention in oral sites, with reduced toxicity. They modulate the immune system by targeting immune cells and other potentially inflammatory cells that release cytokines. Nanohybrids exert antimicrobial activity against bacterial biofilms. The ombination of NSAIDs with nanohybrid polymers improves therapeutic response in periodontal disease.

KEYWORDS: *Anti-inflammatory drugs, dentistry, polymeric nano-hybrid, immune response, inflammation*

INTRODUCTION

The mechanisms and pathways of anti-inflammatory drugs and polymer nano-hybrids in dentistry are very interesting (1). Nonsteroidal anti-inflammatory drugs (NSAIDs) are drugs applied in the management of acute pain in many conditions, including dentistry (2). They have long been used and are well known for both their efficacy and toxic effects. They usually exert a therapeutic effect of relief from inflammation and pain.

In otolaryngology, anti-inflammatory drugs in combination with polymeric nano-hybrids could offer promising advances for the treatment of inflammation and pain. They modulate the immune response and are very useful in the treatment of pulpitis, periodontal disease and peri-implantitis, all diseases where chronic inflammation plays a crucial role (3). In inflammatory reactions, mitogen-activated protein kinase (MAPK) and Toll-like receptor (TLR) signaling are implicated, which are important for the recognition of microbes and for the activation of the immune system. The NLRP3 inflammasome system is also activated in response to pathogens or cellular damage (4). These reactions induce the

Received: 01 November, 2024
Accepted: 09 December, 2024

ISSN 2038-4106 print
ISSN 2975-044X online Copyright © by BIOLIFE 2024
This publication and/or article is for individual use only and may not be further reproduced without written permission from the copyright holder. Unauthorized reproduction may result in financial and other penalties. Disclosure: All authors report no conflicts of interest relevant to this article.

production of pro-inflammatory cytokines such as interleukin (IL)-1, tumor necrosis factor (TNF), and IL-6, and also stimulate the production of chemokines (5). In inflammation, the polarization of M1 (pro-inflammatory) and M2 (anti-inflammatory) macrophages occurs. In addition to macrophages, T cells also participate in balancing the activities of pro-inflammatory Th17 cells and anti-inflammatory Treg cells.

DISCUSSION

In dentistry, NSAIDs inhibit cyclooxygenase-2 (COX-2), preventing the downstream formation of prostaglandins (PGs) that play a key role in inflammatory and painful diseases. Differently, steroid drugs are potent anti-inflammatory drugs that act on the blockade of phospholipase A2 and suppress both PGs and leukotrienes. These, as they inhibit protein synthesis, have an inhibitory action on the synthesis of inflammatory cytokines such as IL-1, TNF, and IL-6. Steroidal anti-inflammatory drugs and NSAIDs are used to manage periodontitis, and to reduce soft tissue inflammation. They help control postoperative inflammation after dental procedures. In addition, anti-inflammatory drugs are used in adjunctive therapy for implant dentistry to mitigate inflammatory responses (6).

Polymeric Nanohybrids in Dentistry

Acrylic teeth are made using polymethyl methacrylate (PMMA) due to its biocompatibility, ease of processing, low cost, stability and acceptable aesthetics. Polymer nanohybrids are nanoscale materials composed of polymers and additional components such as ceramics, metals, or bioactive agents. They are characterized by controlled drug release, multifunctionality, bioadhesion, and biocompatibility. Polymer nanohybrids allow for localized and sustained release of anti-inflammatory drugs, increased retention at oral sites, reduced toxicity, and potential for simultaneous administration of multiple therapeutic agents (7). Nanohybrids deliver drugs directly into inflamed tissues, reducing drug dispersion to other tissues in the body. They modulate the immune system by targeting immune cells such as T and B lymphocytes, macrophages, and other potentially inflammatory cells that release cytokines. Nanohybrids exert antimicrobial activity by combating bacterial biofilms that increase inflammation levels. In addition, chitosan-based polymer nanohybrids promote wound healing and are bioadhesive, and poly (lactic-co-glycolic acid) provides controlled drug release. Hydrogel-based systems improve water retention and drug stability. Immune and inflammatory pathways in dentistry are involved through the activation of NF-kB with production of pro-inflammatory cytokines. It is pertinent to think that combination of anti-inflammatory drugs with bone regenerative factors can improve periodontal therapy.

Nano-hybrids are utilized as both drug carriers and tissue engineering platforms. The use of polymeric nanoparticles can facilitate RNA-based gene therapy that targets specific inflammatory genes, such as cytokines (8). In the future, it may also be possible to customize nano-hybrid formulations based on individual patient profiles to achieve optimal efficacy.

CONCLUSIONS

The use of anti-inflammatory drugs encapsulated in polymeric nano-hybrids represents a new therapeutic weapon against inflammation (periodontitis) in the field of dentistry. This new method acts with precision on inflammatory molecules such as cytokines and chemokines, proteins that regulate the immune system. The synergy between anti-inflammatory drugs and polymeric nano-hybrids minimizes side effects and is an important weapon in the field of dentistry.

Conflict of interest

The authors declare that they have no conflict of interest.

REFERENCES

1. Tsuru K, Shirosaki Y, Hayakawa S, Osaka A. Sol–Gel-Derived Silicate Nano-Hybrids for Biomedical Applications. *Biological and Pharmaceutical Bulletin*. 2013;36(11):1683-1687. doi:https://doi.org/10.1248/bpb.b13-00526
2. Hargreaves K, Abbott PV. Drugs for pain management in dentistry. *Australian Dental Journal*. 2005;50(s2):S14-S22. doi:https://doi.org/10.1111/j.1834-7819.2005.tb00378.x
3. Tetè S, Mastrangelo F, Traini T, et al. A Macro- and Nanostructure Evaluation of a Novel Dental Implant. *Implant Dentistry*. 2008;17(3):309-320. doi:https://doi.org/10.1097/id.0b013e318182d494

4. Isola G, Polizzi A, Santonocito S, Alibrandi A, Williams RC. Periodontitis activates the NLRP3 inflammasome in serum and saliva. *Journal of Periodontology*. 2021;93(1):135-145. doi:https://doi.org/10.1002/jper.21-0049
5. Anogianaki A, Castellani ML, Madhappan B, et al. RANTES (CCL5) potentiates calcium ionophore in the production of LTB4 in rat adherent macrophages from granuloma induced by KMnO4: Inhibiton by NDGA. *Pharmacological Research*. 2007;57(1):49-55. doi:https://doi.org/10.1016/j.phrs.2007.11.002
6. Mastrangelo F, Gastaldi G, Vinci R, et al. Immediate Postextractive Implants With and Without Bone Graft. *Implant Dentistry*. 2018;27(6):638-645. doi:https://doi.org/10.1097/id.0000000000000816
7. Sammartino G, Marenzi G, Tammaro L, et al. Anti-inflammatory drug incorporation into polymeric nano-hybrids for local controlled release. *PubMed*. 2006;18(3 Suppl):55-62.
8. Muzio LL, Tetè S, Mastrangelo F, et al. A novel mutation of gene CBFA1/RUNX2 in cleidocranial dysplasia. *PubMed*. 2007;37(2):115-120.

European Journal of Musculoskeletal Diseases
ISSN 2038-4106 print - ISSN 2975-044X online

Article

BONE GRAFTING STIMULATES PRECURSOR CELLS TO DIFFERENTIATE AND PROMOTE REGENERATION

A. Coppola[1*], R. Padula[2], A. Annicchiarico[3] and C. Annicchiarico[3]

[1] Private practice, Studio Armando Coppola, Corso Garibaldi 246, 80141 Naples, Italy;
[2] Clinical and experimental biology, University of Foggia, Foggia, Italy;
[3] Independent Researcher, University of Bari, 70100 Bari, Italy.

**Correspondence to*:
Armando Coppola,
Private practice, Studio Armando Coppola,
Corso Garibaldi 246,
80141 Naples, Italy.
e-mail: armandocoppola70@gmail.com

ABSTRACT

Transplant rejection occurs when the host's immune system attacks the transplanted organ. However, the transplanted organ can also reject the recipient host. In this case, the reaction is called "graft versus host" (GVH). There are three types of transplant rejection: acute, hyperacute, and chronic. In chronic rejection, activation of the immune system leads to fibrosis of the blood vessels of the transplanted organ and loss of the organ. Bone marrow transplantation is a very useful and life-saving procedure, but it requires careful planning and ongoing monitoring to manage the risks. To reduce the risk of rejection, the donor must have human leukocyte antigen (HLA) that matches with the recipient, and the recipient must be treated with immunosuppressants. Bone graft materials attract and stimulate precursor cells from surrounding tissues and the bloodstream. These materials act as a physical scaffold to participate in the growth and formation of new bone by providing a surface for attachment and causing osteoblasts to proliferate, which is an important process in implantology and periodontal therapies. Osteoblasts play a crucial role in bone grafting and regeneration, and successful implant osseointegration is highly dependent on osteoblasts depositing new bone matrix around the implant surface. The wnt/β-catenin pathway promotes biological effects on osteoblasts and enhances bone formation and regeneration. Bone morphogenetic proteins (BMPs) 2 and 7 are strong inducers of osteoblast differentiation from mesenchymal stem cells and runt-related transcription factor 2 (RUNX2) is a good regulator of osteoblast differentiation. In periodontitis, an altered level of cytokines occurs, leading to inflammatory phenomena involving osteoblasts. Here, we discuss bone grafting in dentistry and the problems related to rejection, periodontal tissue regeneration, and the role of osteoblasts.

KEYWORDS: *Bone graft, transplant, rejection, bone marrow, immunity, dentistry*

INTRODUCTION

Transplant rejection occurs when a transplant recipient's immune system attacks the new organ, recognizing it as foreign (1). The mechanism of attack is similar to that which occurs when a microorganism enters the human body. Rejection is classified as acute, hyperacute, or chronic. Acute rejection occurs in a short time (minutes) and is due to an immune reaction that occurs between lymphocytes and the foreign antigen shown by the transplanted organ (2).

The transplanted organ can also be responsible for rejection, when it carries out a reaction towards the recipient (host), which is called graft versus host (GVH). In this case, the donor cells fail to engraft properly in the recipient's body. Rejection is more common in allogeneic transplants because of different immune compatibility. Hyperacute rejection

Received: 25 September, 2024
Accepted: 10 December, 2024

ISSN 2038-4106 print
ISSN 2975-044X online Copyright © by BIOLIFE 2024
This publication and/or article is for individual use only and may not be further reproduced without written permission from the copyright holder. Unauthorized reproduction may result in financial and other penalties. Disclosure: All authors report no conflicts of interest relevant to this article.

usually occurs five to ten days after surgery and, if not treated with immunosuppressants, the transplanted organ is rejected (3). Chronic rejection can occur long after the transplant and presents persistent activation of the immune system, fibrosis of the blood vessels of the transplanted organ, and loss of the organ (4). The use of immunosuppressants can not only prolong the rejection process but can also lead to the success of the transplant (5).

Transplantation can be performed not only with organs, but also with bone marrow stem cells. This is a complex medical procedure used to treat a variety of diseases, including leukemia and lymphoma, aplastic anemia, and some genetic or immune system diseases (6). These therapeutic treatments are crucial, but they often have complications, including rejection of the bone marrow (7). Bone marrow transplantation is a life-saving procedure for many conditions, but it requires careful planning and ongoing monitoring to manage risks. Causes of rejection include a human leukocyte antigen (HLA) mismatch between donor and recipient, which increases the risk of rejection (8). Pre-existing antibodies in the recipient or insufficient immunosuppression can also lead to rejection.

DISCUSSION

In dentistry, bone graft materials recruit precursor cells from surrounding tissues and the bloodstream (9). The graft material acts as a physical scaffold and participates in the growth and formation of new bone by providing a surface for osteoblasts to attach and proliferate. The precursor cells of the bone-forming osteoblasts are stimulated by certain graft materials and growth factors, causing osteogenesis (10). "Fresh" viable osteoblasts, which are present in autografts, contribute directly to the formation of new bone.

To make a satisfactory graft occur, an appropriate choice of graft is needed. There are various types of grafts such as autograft directly from the patient, or allograft from the donor (11). In the first case, the cells are alive and natural growth factors are activated, which offers excellent results. In the second case, treatments are used to maintain osteoconductive and, in some cases, osteoinductive properties. There is also a third type of graft, the xenograft, with osteoconductive material from other species. In this case, there is a high probability of rejection (12).

Synthetic grafts such as bioceramics are widely used today and are combined with active biological material to obtain a good osteoinductive effect (13). To obtain a satisfactory result, it is necessary to use biological growth factors. Transforming growth factor-beta (TGF-β) and vascular endothelial growth factor (VEGF) are crucial for the differentiation and formation of new vessels (angiogenesis) (14). In addition, the use of some cytokines that regulate signaling are important for the activity of precursor cells and osteoblasts.

Osteoblasts

In dentistry, bone regeneration is governed by osteoblasts, which are important in implantology and periodontal therapies (15). Osteoblasts are precursor cells in bone formation and their activity is essential for maintaining healthy bone structure and function (16). In dentistry, osteoblasts play a fundamental role in bone grafting and regeneration, which are methods for implant placement and reconstructive surgery (17). The success of implant osseointegration depends greatly on osteoblasts that deposit new bone matrix around the implant surface (18).

In periodontal disease, there is a loss of bone regeneration that requires the activation and proliferation of osteoblasts. Osteoblasts are also important in orthodontics where tooth movement involves a balance between bone resorption by osteoclasts and bone formation managed by osteoblasts (19). Osteoblast differentiation and activity is due to the wnt/β-catenin pathway that promotes biological effects on osteoblasts, such as increased bone formation and regeneration (20).

Bone Morphogenetic Protein (BMP) 2 and 7 are strong inducers of osteoblast differentiation from mesenchymal stem cells (21). BMP2 is a protein present in the human body that promotes the growth of new bone. BMP-2 has been studied for several years for its ability to repair bone, almost completely eliminating the need for bone grafts from other parts of the body. This protein has been approved by the FDA and is used in bone grafting. BMP-7 is a member of the TGF-β family, which is widely expressed during fetal life. It plays an important role in stimulating bone synthesis and can be used for therapeutic purposes (22). Its active ingredient is called heptotermin alpha, a copy of BMP-7, and has the ability to induce bone production in recent fractures (23).

A good regulator of osteoblast differentiation is runt-related transcription factor 2 (RUNX2) (24). It is important for mesenchymal stem cells in the differentiation of osteoblasts. Osteoblasts secrete type I collagen, which forms the organic framework of bone (25). Osteocalcin and alkaline phosphatase are proteins involved in matrix maturation and mineralization (26). Additionally, in orthodontics, osteoblasts respond to mechanical insults via integrin-mediated pathways, promoting bone remodeling (27). Chronic inflammatory phenomena often occur in periodontitis and can compromise the function of osteoblasts by altering the levels of TNF, IL-1β and IL-6 cytokines and by acting on the interaction between osteoblasts and the implant (28,29). Other cytokines such as VEGF and TGF-β play a role in angiogenesis and bone formation at implant sites (30).

CONCLUSIONS

Bone grafting is characterized by its ability to increase both bone volume and bone density. In addition, it improves the stability of dental implants and the regeneration of periodontal tissues. These reactions are due to the body's natural ability to regenerate bone through the stimulation and differentiation of precursor cells. Today, bone grafting is a valuable and indispensable tool in dentistry.

Conflict of interest

The authors declare that they have no conflict of interest.

REFERENCES

1. Buser D, Urban I, Monje A, Kunrath MF, Dahlin C. Guided bone regeneration in implant dentistry: Basic principle, progress over 35 years, and recent research activities. *Periodontology 2000*. 2023;93(1):9-25. doi:https://doi.org/10.1111/prd.12539
2. Klos D, Orság J, Loveček M, et al. Emergency surgical treatment of complicated acute pancreatitis after kidney transplantation with acute rejection: Case report and literature review. *Annals of Medicine & Surgery*. 2016;8:14-17. doi:https://doi.org/10.1016/j.amsu.2016.04.022
3. Lu T, Yang B, Wang R, Qin C. Xenotransplantation: Current Status in Preclinical Research. *Frontiers in Immunology*. 2020;10. doi:https://doi.org/10.3389/fimmu.2019.03060
4. Kitamura K, Buchholz BM, Abu-Elmagd K, Kalff JC, Schäfer N, von Websky MW. Chronic rejection after intestinal transplantation: A systematic review of experimental models. *Transplantation Reviews*. 2019;33(3):173-181. doi:https://doi.org/10.1016/j.trre.2019.04.001
5. Clavien PA, Muller X, de Oliveira ML, Dutkowski P, Sanchez-Fueyo A. Can immunosuppression be stopped after liver transplantation? *The Lancet Gastroenterology & Hepatology*. 2017;2(7):531-537. doi:https://doi.org/10.1016/s2468-1253(16)30208-4
6. Muzio LL, Stefano Tetè, Mastrangelo F, et al. A novel mutation of gene CBFA1/RUNX2 in cleidocranial dysplasia. *PubMed*. 2007;37(2):115-120.
7. Simkin PA. Marrow fat may distribute the energy of impact loading throughout subchondral bone. *Rheumatology*. 2017;57(3):414-418. doi:https://doi.org/10.1093/rheumatology/kex274
8. Patterson J, Prentice H, Brenner MK, et al. Graft rejection following HLA matched T-lymphocyte depleted bone marrow transplantation. *British Journal of Haematology*. 2008;63(2):221-230. doi:https://doi.org/10.1111/j.1365-2141.1986.tb05544.x
9. Ho-Shui-Ling A, Bolander J, Rustom LE, Johnson AW, Luyten FP, Picart C. Bone regeneration strategies: Engineered scaffolds, bioactive molecules and stem cells current stage and future perspectives. *Biomaterials*. 2018;180:143-162. doi:https://doi.org/10.1016/j.biomaterials.2018.07.017
10. Hosseini FS, Nair LS, C.T. Laurencin. Inductive Materials for Regenerative Engineering. *Journal of Dental Research*. 2021;100(10):1011-1019. doi:https://doi.org/10.1177/00220345211010436
11. Fillingham Y, Jacobs J. Bone grafts and their substitutes. *The Bone & Joint Journal*. 2016;98-B(1_Supple_A):6-9. doi:https://doi.org/10.1302/0301-620x.98b.36350
12. Khan SN, Cammisa FP, Sandhu HS, Diwan AD, Girardi FP, Lane JM. The Biology of Bone Grafting. *Journal of the American Academy of Orthopaedic Surgeons*. 2005;13(1):77-86. doi:https://doi.org/10.5435/00124635-200501000-00010
13. Kankilic B, Köse S, Korkusuz P, Timuçin M, Korkusuz F. Mesenchymal Stem Cells and Nano-Bioceramics for Bone Regeneration. *Current Stem Cell Research & Therapy*. 2016;11(6):487-493. doi:https://doi.org/10.2174/1574888x10666150202150518
14. Shi Y, Yu P, Zeng D, et al. Suppression of vascular endothelial growth factor abrogates the immunosuppressive capability of murine gastric cancer cells and elicits antitumor immunity. *The FEBS Journal*. 2014;281(17):3882-3893. doi:https://doi.org/10.1111/febs.12923
15. Tetè S, Mastrangelo F, Traini T, et al. A Macro- and Nanostructure Evaluation of a Novel Dental Implant. *Implant Dentistry*. 2008;17(3):309-320. doi:https://doi.org/10.1097/id.0b013e318182d494

16. Mizoguchi T, Ono N. The diverse origin of bone-forming osteoblasts. *Journal of Bone and Mineral Research: The Official Journal of the American Society for Bone and Mineral Research*. 2021;36(8):1432-1447. doi:https://doi.org/10.1002/jbmr.4410
17. Mastrangelo F, Gastaldi G, Vinci R, et al. Immediate Postextractive Implants With and Without Bone Graft. *Implant Dentistry*. 2018;27(6):638-645. doi:https://doi.org/10.1097/id.0000000000000816
18. Vandamme K, Naert I, Jozef Vander Sloten, Puers R, Duyck J. Effect of Implant Surface Roughness and Loading on Peri-Implant Bone Formation. *Journal of Periodontology*. 2008;79(1):150-157. doi:https://doi.org/10.1902/jop.2008.060413
19. Li Y, Zhan Q, Bao M, Yi J, Li Y. Biomechanical and biological responses of periodontium in orthodontic tooth movement: up-date in a new decade. *International Journal of Oral Science*. 2021;13(1). doi:https://doi.org/10.1038/s41368-021-00125-5
20. Shen G, Ren H, Shang Q, et al. Foxf1 knockdown promotes BMSC osteogenesis in part by activating the Wnt/β-catenin signalling pathway and prevents ovariectomy-induced bone loss. *EBioMedicine*. 2020;52:102626-102626. doi:https://doi.org/10.1016/j.ebiom.2020.102626
21. Sánchez-Duffhues G, Hiepen C, Knaus P, ten Dijke P. Bone morphogenetic protein signaling in bone homeostasis. *Bone*. 2015;80:43-59. doi:https://doi.org/10.1016/j.bone.2015.05.025
22. Cho K, Kim NH, Seo SH, et al. A micellized bone morphogenetic protein-7 prodrug ameliorates liver fibrosis by suppressing transforming growth factor-β signaling. *PubMed*. 2022;12(2):763-778.
23. Patel AD. Bone morphogenetic proteins in orthopaedic trauma: recent clinical findings with human bone morphogenetic protein-2 (rhBMP-2). *Current Medical Research and Opinion*. 2006;22(sup1):S1-S5. doi:https://doi.org/10.1185/030079906x80567
24. Ren C, Xu Y, Liu H, et al. Effects of runt-related transcription factor 2 (*RUNX2*) on the autophagy of rapamycin-treated osteoblasts. *Bioengineered*. 2022;13(3):5262-5276. doi:https://doi.org/10.1080/21655979.2022.2037881
25. Lu Y, Kamel-El Sayed SA, Wang K, et al. Live Imaging of Type I Collagen Assembly Dynamics in Osteoblasts Stably Expressing GFP and mCherry-Tagged Collagen Constructs. *Journal of Bone and Mineral Research: The Official Journal of the American Society for Bone and Mineral Research*. 2018;33(6):1166-1182. doi:https://doi.org/10.1002/jbmr.3409
26. Diemar SS, Møllehave LT, Quardon N, et al. Effects of age and sex on osteocalcin and bone-specific alkaline phosphatase—reference intervals and confounders for two bone formation markers. *Archives of Osteoporosis*. 2020;15(1). doi:https://doi.org/10.1007/s11657-020-00715-6
27. Li J, Zhao Z, Wang J, Chen G, Yang J, Luo S. The role of extracellular matrix, integrins, and cytoskeleton in mechanotransduction of centrifugal loading. *Molecular and Cellular Biochemistry*. 2007;309(1-2):41-48. doi:https://doi.org/10.1007/s11010-007-9641-0
28. Sammartino G, Marenzi G, Tammaro L, et al. Anti-inflammatory drug incorporation into polymeric nano-hybrids for local controlled release. *PubMed*. 2006;18(3 Suppl):55-62.
29. David JP, Schett G. TNF and Bone. *Current Directions in Autoimmunity*. 2010;11:135-144. doi:https://doi.org/10.1159/000289202
30. Kostiv RE, N. Yu. Matveeva, Kalinichenko SG. Localization of VEGF, TGF-β1, BMP-2, and Apoptosis Factors in Hypertrophic Nonunion of Human Tubular Bones. *Bulletin of Experimental Biology and Medicine*. 2022;173(1):160-168. doi:https://doi.org/10.1007/s10517-022-05513-3

European Journal of Musculoskeletal Diseases
ISSN 2038-4106 print - ISSN 2975-044X online

Prospective Comparative Study

PROSPECTIVE COMPARATIVE STUDY OF CSR IMPLANTS PROSTHESIZED WITH CONOMETRIC TECHNIQUE: ANALOG VS DIGITAL TECHNIQUE

F. Ferrini[1,2*], F. Mazzoleni[1,2], M. Barbini[1,2], C. Coppo[1,2], F. Cattoni[1,2] and E.F. Gherlone[1,2]

[1] Dental School, Vita-Salute San Raffaele University, Milan, Italy;
[2] Department of Dentistry, IRCCS San Raffaele Hospital and Dental School, Vita-Salute San Raffaele University, Milan, Italy.

**Correspondence to*:
Francesco Ferrini,
Dental School IRCCS San Raffale,
Vita-Salute San Raffaele University,
20132 Milan, Italy.
e-mail: ferrini.francesco@hsr.it

ABSTRACT

The growing interest in digital technologies has affected, in recent years, many areas of various fields of work, and dentistry is one of them; in fact, implantology and modern prosthetics are increasingly turning to digital technology. Both the traditional and digital impressions are operator dependent, so it is necessary that each prosthodontist, or rather any dentist, knows how to best capture the anatomical/mechanical details, in the case of implants, of each patient treated. Failure to do so would mean sending into production an artifact that already has underlying defects inherent in the impression taken poorly by the dentist or cast incorrectly by the dental technician. The purpose of this study is to compare analog and digital work-flow, in the design of the surgical and prosthetic procedures using CSR implants (CSR Implant System, Sweden&Martina, Due Carrare, Padua, Italy) associated with conometric technique. The innovative part of the CSR implants (CSR Implant System, Sweden&Martina, Due Carrare, Padua, Italy) lies in the DAT connection: a double internal conical contact interface between the abutment and the implant and between the screw and the abutment. In fact, the tapered technique that we find in the DAT connection just mentioned allows to obtain an implant-supported fixed prosthesis without the use of cement or screws fixation between abutment and prosthesis which, at the same time, is easily removable by the clinician, while still being a fixed prosthesis. The aim of this study is to evaluate the stability of implant prostheses rehabilitation, comparing the traditional technique (control group) with the digital technique (test group).

KEYWORDS: *digital impression, digital workflow, implant-prosthodontic restoration, intraoral scanner, full archrehabilitation, digital dentistry*

INTRODUCTION

Nowadays in the digital age, the reading precision and accuracy of the scanners is becoming increasingly reliable and accurate, resulting in a precise and reliable fit of prosthetic artifact on abutments (1-7).

According to a recent study conducted by Peter Gehrke et al. in 2021 (8,9,10), it is inferred that the use of a cone-in-cone interface, analyzed by SEM analysis, avoids the creation of a micro gap at the cone-in-cone junction itself allowing a clinically and statistically optimal seal to avoid bacterial infiltration (Fig.1).

Received: 13 September, 2024
Accepted: 10 December, 2024

ISSN 2038-4106 print
ISSN 2975-044X online Copyright © by BIOLIFE 2024
This publication and/or article is for individual use only and may not be further reproduced without written permission from the copyright holder. Unauthorized reproduction may result in financial and other penalties. Disclosure: All authors report no conflicts of interest relevant to this article.

Fig. 1. *Cone-in-cone interface.*

According to various studies by Degidi M. et al. (11,12) the use of the conometric connection allows a fixation of the crown on the abutment without the use of screws and cement; this feature allows a lower percentage of bacterial infiltrate and a better accuracy of positioning, subsequently confirmed by endoral radiography. Moreover, the method of conometric prosthesis allows easier access in case of problematic situations, this is achievable by disassembling the crown using a dedicated clamp and repositioned with a fixation tool that exerts an axial force on the crown itself.

MATERIALS AND METHODS

50 patients were enrolled in the study, 25 digital cases (DIG group) and 25 traditional cases (AN group). All the patients in the sample were treated at the Operating Unit of Dentistry and Dental Prosthetics of San Raffaele Hospital in Milan, Italy.

Every recruited patient underwent placement of an osseointegrated implant, and subsequently prosthesized either with a conometric technique using digital work-flow (DIG Group) or traditional one (AN GROUP) (Fig.2,3).

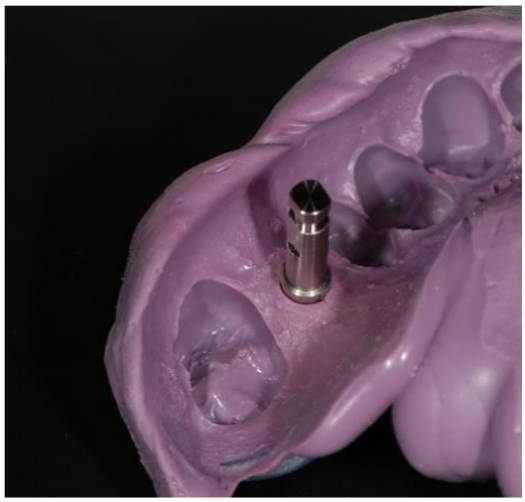

Fig. 2. *Analogical impression.*

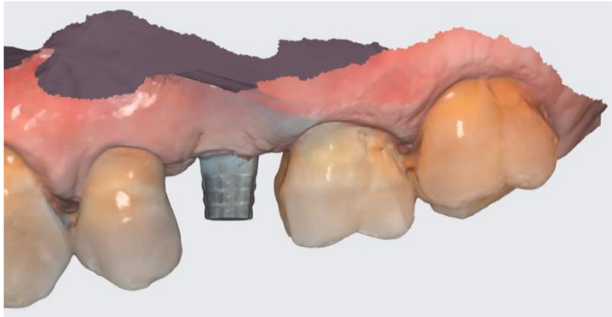

Fig. 3. *Digital impression.*

Once they receive the scan (whether it is in .stl or analog format), the dental technician proceeds to design and fabricate the shelled prosthetic construct within which he will then, using a direct method, cement the conometry coping using dual composite self-adhesive cement. Once the coping is cemented inside the prosthetic framework directly in the oral cavity, it is finished in the laboratory and the conometry is reactivated (Fig.4-9).

Fig. 4. *Perimplant tissues.*

Fig. 5. *Vestibular view of the abutment.*

Fig. 6. *Occlusal view of the abutment with the cap in position.*

Fig. 7. *Vestibular view of the abutment with the cap in position.*

Fig. 8. *Crown in position over the cap.*

Fig. 9. *Final result.*

A sample size of 25 subjects in each group (DIG and AN, total of 50 patients) allows a test power of 1 - # = 0.95 and 1 - # = 0.79 for independent and paired comparisons, respectively, corresponding to a significance level of 0.05 and a Cohen's Effect Size d = 0.8 referring to the duration of prosthesis in relation to the loss or non-loss of the prosthetic artifact. Given a drop-out probability, estimated from previous clinical experience, of 0.15, the total initial number of patients to be recruited was 60 subjects (30+30).

Aesthetic assessment by a "blinded" clinician and patient satisfaction were measured during follow-up performed on the day of the placement of the tapered crown on CSR implant, at 3 (T1), 6 (T2) and 12 (T3) months after completion of the prosthetic phase.

The following assessments were performed:

1. Keratinized mucosal height (KM): measured from the mucogingival junction to the coronal margin of the free gengiva;
2. Disto Vestibular Probing Depth (PD-DL): the distance between the gingival margin and the bottom of the pocket on the disto-vestibular side;
3. Disto Lingual Probing Depth (PD-DL): the distance between the gingival margin and the bottom of the pocket on the disto-lingual side;
4. Radiographic bone loss around the implant, measured by monitoring changes in marginal bone level through

radiographs; a healthy implant should have less than 0.2mm of bone loss during the first year;

5. Patient satisfaction: measured by a satisfaction questionnaire.

STATISTICS ANALYSIS

Prosthesis longevity will be analyzed using a Cox proportional hazards model. Considering an overall probability of failure of ! =0.20 (estimated from clinical experience) and a significance level " = 0.05, the expected sample size (# = 25 + 25) will allow a test power 1 - $ = 0.85 corresponding to an ln %% = 1.9.

A prosthesis is considered failed if it does not meet one or more of the reliability criteria that a dental prosthesis necessarily has: stability, function, aesthetics. A prosthesis, therefore, can be considered failed (0) or not failed (X).

RESULTS

All patients included in this study completed surgical-prosthetic treatment by participating in all follow-ups required by this study; specifically, 14 male and 17 female patients were included for a total of 54 implants. At the time of implant placement, patients ranged in age from 25 to 70 years (50.5 ± 13.9).

During the predetermined follow-up period, there were 2 failed implants that were replaced after a period of bone regeneration and a prosthetic survival rate of 100%.

Values for each parameter were assessed by the same operator and with the same techniques to avoid errors in measurements.

Keratinized mucosal height

In the AN group, mean KM values were 2.90 mm; 3 mm; 3.27 mm respectively in a follow-up of 3, 6 and 12 months. In the DIG group, mean KM values were 2.51 mm; 3 mm; 3 mm respectively in a follow-up of 3, 6 and 12 months. Descriptive statistical analysis regarding mean KM values is shown in the table below (Fig.10).

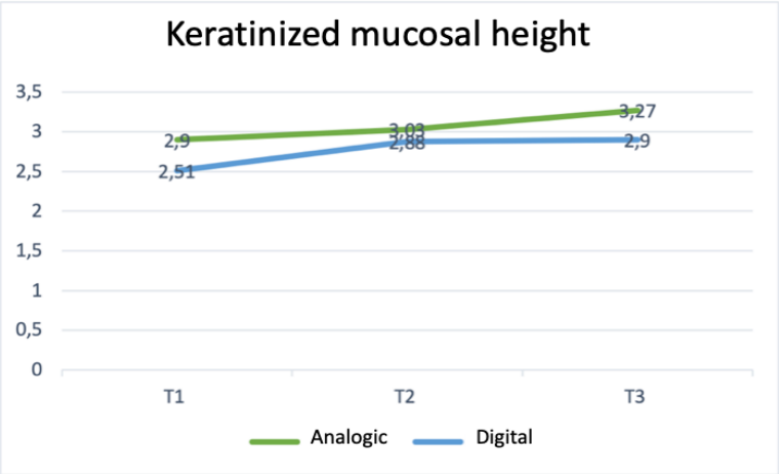

Fig. 10. *Keratinized mucosal height.*

Disto-vestibular Probing Depth

In the AN group, the mean PD DV values were 2.43mm; 1.95mm ;1.81mm respectively in a follow-up of 3, 6 and 12 months. In the DIG group, the mean PD DV values were 2.14 mm; 1.88mm ;1.7 mm in a follow-up of 3, 6 and 12 months, respectively. The descriptive statistical analysis regarding the mean PD DV values is shown in table below.

Disto Lingual Probing Depth (PD-DL)

In the AN group, the mean values of PD DL were 1.68 mm; 1.50 mm ;1.59 mm respectively in a follow-up of 3, 6 and 12 months. In the DIG group, the mean values of PD DL were 1.684 mm; 1.69 mm ;1.76 mm respectively in a follow-up of 3, 6 and 12 months. (Fig.11, Table I)

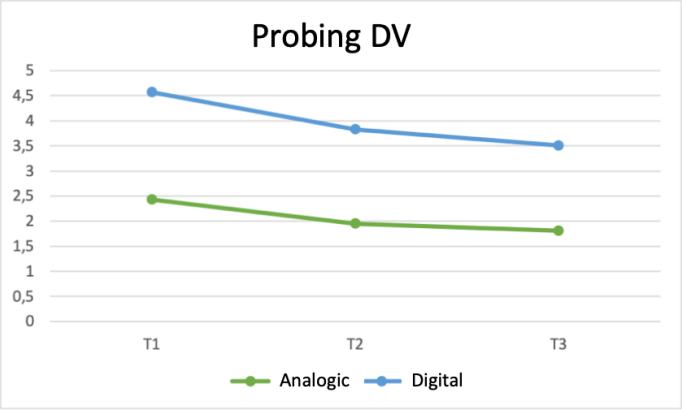

Fig. 11. *Probing DV.*

Table I. *Probing DV during T1; T2; T3.*

PD DV	GROUP	MEAN (mm)	STAND DEV
T1	AN	2,43 mm	0,54
	DIG	2,14 mm	0,59
T2	AN	1,95 mm	0,50
	DIG	1,88 mm	0,55
T3	AN	1,81 mm	0,47
	DIG	1,7 mm	0,45

The descriptive statistical analysis regarding the mean PD DV values is shown in table below (Table II, Fig.12).

Table II. *Probing DL during T1; T2; T3.*

PD DL	GROUP	MEAN (mm)	STAND DEV
T1	AN	1,68 mm	0,33
	DIG	1,684 mm	0,59
T2	AN	1,50 mm	0,28
	DIG	1,69 mm	0,51
T3	AN	1,59 mm	0,22
	DIG	1,76 mm	0,75

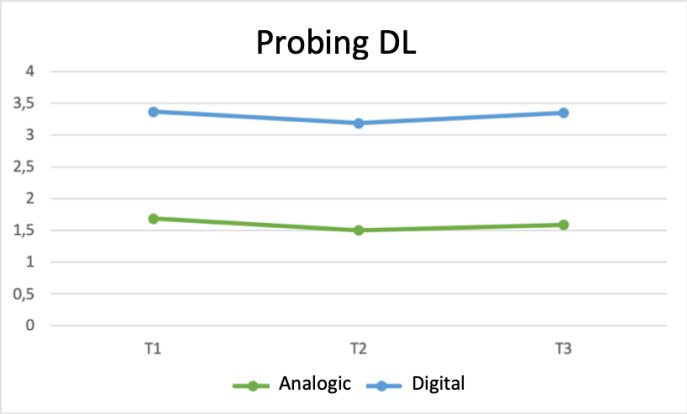

Fig. 12. *Probing DL.*

Evaluation of Radiographic Parameters

In the AN group, the mean marginal bone loss values were 1.50 mm; 1.64 mm; 1.72 mm in a follow-up of 3, 6 and 12 months, respectively. In the DIG group, the mean marginal bone loss values were 1.56 mm; 1.78 mm; 1.8 mm at a follow-up of 3, 6 and 12 months, respectively. Descriptive statistical analysis regarding the mean bone loss values is shown in the table below (Table III, Fig.13).

Table III. *Loss of bone in T1; T2; T3.*

LOSS OF BONE	GROUP	MEAN (mm)	STAND DEV
T1	AN	1,50 mm	0,54
	DIG	1,56 mm	0,55
T2	AN	1,64 mm	0,534
	DIG	1,78 mm	0,532
T3	AN	1,72 mm	0,56
	DIG	1,80 mm	0,53

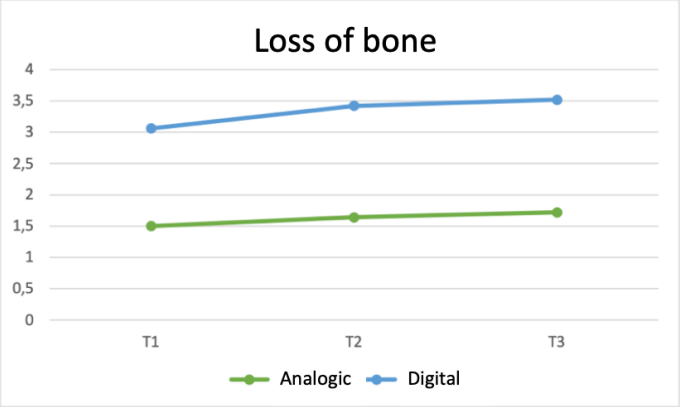

Fig. 13. *Loss of bone.*

Patient Satisfaction

The VAS scale score regarding patient satisfaction (digital vs. analog flow) is summarized in Table IV.

During impression taking, the digital group reported greater comfort with:

- Mean VAS value of 91±11.60 for the AN group and 98.61±2.72 for the DIG group.
- Gag reflex almost absent in the DIG group with mean values of 99.81±0.25 (vs. 85.73±6.57 for the AN group.
- Greater comfort for the DIG group during acquisition with mean value of 99.87±0.34, compared to the AN group in which we have as mean score 86.13±7.01.

- Overall, however, the two groups did not differ, from a clinical point of view, in terms of the patient's willingness to hypothetically undergo the procedure again (mean value AN group 97. 06 ± 10. 30 and DIG group 97.06±10.27).

On the other hand, regarding satisfaction in terms of cosmetic and functional outcome, for both AN and DIG groups, they were both above 95 score (Table IV).

Table IV. *Patient Satisfaction.*

QUESTION	GROUP	MEAN + SD
1	AN	95,13±3,37
	DIG	97,00±2,22
2	AN	93,53±7,83
	DIG	96,5±2,60
3	AN	98,4±2,69
	DIG	98,5±2,83
4	AN	86,13±7,01
	DIG	99,87±0,34
5	AN	85,73±6,57
	DIG	99,93±0,25
6	AN	76,86±13,73
	DIG	99,81±0,40
7	AN	85,66±17,54
	DIG	97,12±2,15
8	AN	98,66±5,16
	DIG	98,75±5,00
9	AN	97,06±10,30
	DIG	97,06±10,27
10	AN	97,00±10,30
	DIG	99,31±2,49

DISCUSSION

Implant-prosthetic rehabilitations are playing an increasingly prominent role within the dental field both because of the patient's increasing desire to obtain fixed rehabilitation and because of the implementation of new techniques and technologies.

Traditional methods, whether in surgical or prosthetic, remain the reference procedures to evaluate efficacy and accuracy of new technologies and new workflows.

The best way to rehabilitate an edentulous area through implant- prosthetic treatment, whenever feasible, is also influenced by the superior survival rate compared to removable alternatives. This consideration was also confirmed by a 2021 study by Kurosaki et al. (13,14). This study demonstrated that 6 years after prosthetic rehabilitation, there was a survival rate of 94.7 percent for fixed implant- supported prosthetic rehabilitation, 77.4 percent for fixed prostheses and 33.3 percent for removable partial dentures. According to the results obtained in this study, 2 implant failures were recorded out of 54 implants placed.

Regarding implant failure, however, no significant differences were found between the two groups with a p value of 0.9979 at t1 and 0.9988 at time t2 with mean bone loss values of 1.5±0.54 for AN group and 1.56±0.55 for DIG group at time t1 and 1.64±0.534 for AN group and 1.78±0.532 for DIG group at t2, respectively.

Prosthetic rehabilitations, whether on implants or natural elements, must be meticulously planned and executed in order to achieve good prosthetic support that succeeds in adequately unloading the masticatory forces; for these purposes, certainly the digital technologies have been a major help. Indeed, with the introduction of digital technologies, great precision can be achieved in both implant and prosthetic placement.

Regarding the surgical phase through digital methods, the operator can plan implant placement through software that allows to simulate the size and position of the implant through the patient's CBCT, and also to mark reference anatomical points in order to avoid damage, and to make the procedure more predictable and reliable.

During the prosthetic phase, digital technology has taken an even more preponderant role. New technologies can be used in every phase of treatment such as planning, impression taking, design and follow-up.

During planning, digital technologies can be used for diagnosis, results preview and decision making. Then, moving on to impression taking, through intraoral scanners which allows to transfer or store information through ".stl" files; this guarantees clear communication between clinician and dental technician (15-17). Coming to the use of digital devices in design phase, it's possible to rely on dedicated software to design and produce a costumed prosthesis that fit perfectly, esthetically and functionally. Finally, intraoral scanners (I.O.S.) can also be used in follow-ups, where it can be seen if there are any changes that may affect both the soft tissues and the fit of the prosthetic artifacts (15-17).

However, regardless of the traditional or technological methods used, they must be accompanied by good professional and home oral hygiene with the dedicated aids recommended by the practitioner (18).

A study by Muhlemann et al. in 2018 (19) shows that when analyzing the advantages that are obtained through digital technologies for implant-supported rehabilitations, it's possible to evaluate better efficiency when designing prostheses through CAD/CAM methodologies compared to conventional workflow. Regarding the results obtained during this study, there were 2 prosthetic failures in the AN group due to disconnection of the conometric rehabilitation. This result, however, doesn't lead to a significant difference between the two groups evaluated, similarly to implant failure, with p values of 0.9989 at T1 and 0.9979 at T2.

According to a study by Oh T-J et al. in 2005, it was seen that commercially available implant systems recognized as medical devices have an implant-abutment connection accuracy of 1 to 10 µm. Taking into consideration that the average size of the most common bacteria colonizing the oral cavity is 0.3-5 µm it is predictable a fast and easy colonization of the implant connection surface.

According to a 2016 study by E.F. Gherlone and P. Capparè, 80 implants divided into 8 groups based on connection and implant type were considered; it was seen that the cone connection had a lower contamination rate than the other 7 types of implants (3). Specifically, bacteria being closely correlated with the presence of bleeding and plaque, we showed that 35.19% of patients had bleeding and the remaining 64.81% had no bleeding. Similarly, the presence of plaque was shown for 33.34% and the absence of plaque for the remaining 66.66%.

The presence of plaque and bleeding, and thus inflammation of the peri-implant soft tissues, also negatively affects the formation of new keratinized tissue around the implant itself. The bacteria colonization of the implant surface leads to the activation of chemotactic stimuli that brings to the recruitment of inflammatory cells and thus peri-implant inflammation that, if unchecked, leads to subsequent bone loss or even implant failure (20,21). In this study, the height of keratinized tissue (KM) was also evaluated, resulting in no statistically significant difference in the mean of KM at varying impression type (P=0.70) nor at varying time (p=0.19), nor that there is a different outcome comparing the impression method in different times, T1, T2 and T3(interaction, p=0.55).

Clinical and radiographic results in T3 show no significant differences between an analog and digital workflow in conometric implant prosthetic rehabilitations on CSR implants.

CONCLUSIONS

The results of this prospective observational study with one year of follow-up and 54 implants placed showed that there are no statistically significant differences between an analog and a digital workflow in conometric prosthetic rehabilitations on CSR implants.

This type of implant has been demonstrated in the literature to be superior to traditional connections in terms of bacterial sealing and micromovements at the implant-abutment interface. Objective clinical and statistical evaluation demonstrated excellent survival in both implant and prosthetic phases. In addition, data acquired through a patient satisfaction questionnaire showed a preference for the digital protocol in terms of both comfort and timing.

In conclusion, the protocol of this prospective observational study will continue with further clinical studies to confirm the results obtained.

Funding

No external funding has been received to carry out the research.

Conflict of interest

The authors declare that they have no conflict of interest.

REFERENCES

1. Masri R, Discoll CSI. Odontoiatria digitale; 2017 EDRA (Italy) Masson ISBN/EAN: 9788821442001 p.50.
2. Punj A, Bompolaki D, Garaicoa J. Dental Impression Materials and Techniques. *Dent Clin North Am*. 2017;61(4):779-796. doi:10.1016/j.cden.2017.06.004
3. Giannetti L, Spinas E, Murri Dello Diago A, Consolo U, Generali L. Implant conometric connection through innovative prosthetic abutment: biological, clinical, surgical, and prosthetic aspects. *J Biol Regul Homeost Agents*. 2019;33(1):287-290.
4. Bressan E, Lops D, Tomasi C, Ricci S, Stocchero M, Carniel EL. Experimental and computational investigation of Morse taper conometric system reliability for the definition of fixed connections between dental implants and prostheses. *Proc Inst Mech Eng H*. 2014;228(7):674-81. doi: 10.1177/0954411914545556.
5. Mangano C, Mangano FG, Muscas M, Figliuzzi M. Studio prospettico multicentrico su 2707 impianti a connessione conometrica. Implantologie. 2017.
6. Gherlone EF, Capparé P, Pasciuta R, Grusovin MG, Mancini N, Burioni R. Evaluation of resistance against bacterial microleakage of a new conical implant-abutment connection versus conventional connections: an in vitro study. *New Microbiol*. 2016;39(1):49-56.
7. Degidi M, Nardi D, Sighinolfi G, Degidi D, Piattelli A. The Conometric Concept: A Two-Year Follow-Up of Fixed Partial CEREC Restorations Supported By Cone-In-Cone Abutments. *J Prosthodont*. 2019;28(2):e780-e787. doi:10.1111/jopr.12962
8. Gehrke SA, Dedavid BA, de Oliveira Fernandes GV. A new design of a multifunctional abutment to morse taper implant connection: Experimental mechanical analysis. *J Mech Behav Biomed Mater*. 2021;116:104347. doi:10.1016/j.jmbbm.2021.104347
9. Gehrke P, Hartjen P, Smeets R, et al. Marginal Adaptation and Microbial Leakage at Conometric Prosthetic Connections for Implant-Supported Single Crowns: An In Vitro Investigation. *Int J Mol Sci*. 2021;22(2):881. doi:10.3390/ijms22020881
10. Gehrke P, Burg S, Peters U, et al. Bacterial translocation and microgap formation at a novel conical indexed implant abutment system for single crowns. *Clin Oral Investig*. 2022;26(2):1375-1389. doi:10.1007/s00784-021-04112-2
11. Degidi M, Nardi D, Sighinolfi G, Degidi D, Piattelli A. The Conometric Concept: Definitive Rehabilitation of a Single Posterior Implant Using a Friction Retention Abutment. A 1-year Follow-up Report. *Int J Prosthodont*. 2023;36(1):104–112. doi:10.11607/ijp.7369
12. Degidi D, Nardi D, Degidi M. The Conometric Concept- Immediate Definitive Full Arch Rehabilitation of the Edentulous Maxilla Supported by Cone-in-cone Abutments and Guided Implants- a Preliminary Report. *Clinical oral implants research*. 2018;29(S17):363–363.
13. Kurosaki Y, Kimura-Ono A, Mino T, et al. Six-year follow-up assessment of prosthesis survival and oral health-related quality of life in individuals with partial edentulism treated with three types of prosthodontic rehabilitation. *J Prosthodont Res*. 2021;65(3):332-339. doi:10.2186/jpr.JPR_D_20_00095
14. Albiero AM, Benato R, Momic S, Degidi M. Guided-welded approach planning using a computer-aided designed prosthetic shell for immediately loaded complete-arch rehabilitations supported by conometric abutments. *J Prosthet Dent*. 2019;122(6):510-515. doi:10.1016/j.prosdent.2018.12.002

15. Albiero AM, Benato R, Momic S, Degidi M. Implementation of computer-guided implant planning using digital scanning technology for restorations supported by conical abutments: A dental technique. *J Prosthet Dent*. 2018;119(5):720-726. doi:10.1016/j.prosdent.2017.07.015
16. Bressan E, Venezze AC, Magaz VR, Lops D, Ghensi P. Fixed Conometric Retention with CAD/CAM Conic Coupling Abutments and Prefabricated Syncone Caps: A Case Series. *Int J Periodontics Restorative Dent*. 2018;38(2):277-280. doi:10.11607/prd.3161
17. Mühlemann S, Kraus RD, Hämmerle CHF, Thoma DS. Is the use of digital technologies for the fabrication of implant-supported reconstructions more efficient and/or more effective than conventional techniques: A systematic review. *Clin Oral Implants Res*. 2018;29 Suppl 18:184-195. doi:10.1111/clr.13300
18. Caricasulo R, Malchiodi L, Ghensi P, Fantozzi G, Cucchi A. The influence of implant-abutment connection to peri-implant bone loss: A systematic review and meta-analysis. *Clin Implant Dent Relat Res*. 2018;20(4):653-664. doi:10.1111/cid.12620
19. Bressan E, Lops D. Conometric retention for complete fixed prosthesis supported by four implants: 2-years prospective study. *Clin Oral Implants Res*. 2014;25(5):546-552. doi:10.1111/clr.12121

European Journal of Musculoskeletal Diseases
ISSN 2038-4106 print - ISSN 2975-044X online

Retrospective Observational Study

NEEDLE-FREE INFILTRATION OF KEY MYOFASCIAL TRIGGER POINTS IN THE TREATMENT OF POSTURAL DYSFUNCTION ASSOCIATED WITH CHRONIC MYOFASCIAL PAIN SYNDROME

G. Barassi[1*], M. Panunzio[2], L. Prosperi[1], G.L. Matera[1], V. Guglielmi[1], C. Marinucci[1], S. Cristiani[1], G. Ianieri[1], P. Galasso[1] and P.E. Gallenga[1]

[1] Center for Physiotherapy, Rehabilitation and Reeducation (Ce.Fi.R.R.), "G. d'Annunzio" University of Chieti-Pescara, Chieti, Italy;
[2] Responsible Research Hospital, Campobasso, Italy.

**Correspondence to*:
Giovanni Barassi,
Center for Physiotherapy, Rehabilitation and Reeducation (Ce.Fi.R.R.),
"G. d'Annunzio" University of Chieti-Pescara,
66013 Chieti, Italy.
e-mail: coordftgb@unich.it

ABSTRACT

Myofascial Pain Syndrome (MPS) is a pathology characterized by pain and biomechanical-postural alterations in the presence of myofascial trigger points (MTrPs). Among the treatment techniques for MPS, MTrPs infiltrations with dry needling or with the injection of pharmacological substances is often used, which however, can present criticalities in terms of safety and tolerability. However, recent technological developments allow to obtain deeply focused active ingredient delivery effects through dedicated electromedical devices. This pilot retrospective analytical observational study aims to evaluate the efficacy of a cycle of 5 sessions of needle-free infiltration (N-Fi) with the delivery of a gel based on hyaluronic acid, ozone and vitamin C in reducing pain, measured with the Numeric Pain Rating Scale (NPRS), and postural dysfunction, measured with the computerized calculation of the Postural Biometric Index (PBI). Data from 30 patients (mean age 56±13 years) affected by MPS were considered. At the end of the study, a significant reduction in the NPRS score (-41.9%) and PBI (-31.1%) values was observed. Therefore, our observations confirm that MPS patients treated with N-Fi show a significant improvement in pain and biomechanical-postural dysfunction associated with their pathology. Further in-depth studies on the topic are recommended to confirm the preliminary results of our research.

KEYWORDS: *Rehabilitation, physical therapy, trigger point, myofascial pain syndrome, injection*

INTRODUCTION

Myofascial pain syndrome (MPS) is a pathology characterized by alterations in the morphology and functionality of the muscular and fascial tissue of one or more areas of the human body; these qualities determine the appearance of pain and reduced musculoskeletal function, often accompanied by anxious and depressive states (1,2). It is estimated that the prevalence of MPS can reach rates of 85% (3), with a fair amount of variability between sexes and between the types of pathological population considered (3,4).

The main detectable alteration that occurs in the myofascial tissue of subjects affected by MPS is the establishment of myofascial trigger points (MTrPs), which are typically described as hyperirritable spots in the skeletal muscle that are

Received: 22 October, 2024
Accepted: 17 December, 2024

ISSN 2038-4106 print
ISSN 2975-044X online Copyright © by BIOLIFE 2024
This publication and/or article is for individual use only and may not be further reproduced without written permission from the copyright holder. Unauthorized reproduction may result in financial and other penalties. Disclosure: All authors report no conflicts of interest relevant to this article.

associated with hypersensitive palpable nodules in a taut muscular band. The spot is painful on manual compression and can give rise to characteristic referred pain, referred tenderness, motor dysfunction, and autonomic phenomena (5). At the diagnostic level, a MTrP is usually identified when at least two of the three typical features recur during the evaluation: the presence of a taut band in the muscle, the presence of a hypersensitive spot, and a referred pain pattern evoked by stimulation of the point examined (6). It follows that the diagnosis of MPS in the presence of MTrPs is predominantly clinical, by virtue of the good reliability of palpatory evaluation in this pathological context (7); however, even instrumental examination with imaging techniques such as ultrasound or with impedenziometric assessment devices would seem to have its relevance in the observation of this complex and insidious syndrome (8,9).

Given the complexity of MPS, numerous therapeutic solutions have been proposed over time, with efficacy that is often unclear and debated (3). The management of MPS can in fact be based on treatments that range from less invasive manual, physiotherapy-instrumental and physical exercise methods, to more severe approaches such as pharmacological and infiltrative treatments (3,10,11).

The infiltrative therapy of MTrPs represents one of the most frequently applied techniques in the clinical field for the management of MPS (12). In most cases, these techniques are based on the infiltration of substances such as anesthetics, corticosteroids, NSAIDs and Botulinum into the MTrP (13,14). In other cases, the stimulation technique is based on the use of so-called dry needling (15). Despite their mixed efficacy, these techniques are not free from side effects and risks of various kinds such as infections, potential lesions caused to non-muscular tissues, systemic allergic reactions to the absorption of the injected substances, cellulite and inflammation phenomena at the injection site, pneumothorax in the torso and inapplicability of the technique in the presence of trypanophobia (14,16,17). Hence, it could be useful in the clinical field to investigate new methods of chemical stimulation of MTrPs through delivery techniques mediated by physical means such as electricity, sound waves and light, as occurs, for example, in the case of iontophoresis and phonophoresis (18,19).

Therefore, given the previously exposed considerations, we aimed to conduct an observational pilot study on the efficacy in the treatment of MPS of a needle-free infiltration (N-Fi) therapy, applied through a device that integrates athermic diathermy (AD) and low-level laser therapy (LLLT) for the delivery of a compound based on hyaluronic acid, ozone and vitamin C.

MATERIALS AND METHODS

This research is a pilot retrospective analytical observational study carried out at the Center for Physiotherapy, Rehabilitation and Re-Education (Ce.Fi.R.R.), a venue of the “Gabriele d’Annunzio” University of Chieti-Pescara (Chieti, Italy), from January to September 2023.

All the procedures applied comply with the national safety regulations regarding health services. The protocol is accessible to anyone who does not highlight specific contraindications during the initial clinical evaluation necessary for all patients who access the study venue. The protocol is not an experimental application, since it uses the same procedures applied at the study facility for all patients who do not present the above-mentioned contraindications. This study was conducted in accordance with the ethical principles of the Declaration of Helsinki. Written informed consent was obtained at enrolment from participants who were willing and able. Furthermore, the Ce.Fi.R.R., as the institution in charge for performing the study, owns the ISO 9001:2015 certification for the realization of "Clinical observational studies in the rehabilitation field" (Certificate from the Italian Accreditation Body "Accredia" n. IT15/0304). Due to these considerations and the lack of incontrovertible national legislation regarding the need for the submission of retrospective and/or non-pharmacological observational studies to an ethics committee (20), normal ethics committee clearance was not required (21).

Data were collected from 30 patients (9 males and 21 females, Caucasian ethnicity, mean age 56±13 years) confluent in the study site, affected by MPS, who underwent N-Fi treatments.

Physiatrists in charge of the initial clinical evaluation of each patient diagnosed the presence of chronic MPS associated with MTrPs, with the presence of frequent muscle pain associated with the presence of knotty and painful muscle areas upon palpation for at least 6 months (22).

Inclusion criteria were an age between 30 and 80 years and the diagnosis of chronic MPS.

Exclusion criteria were all the typical contraindications for treatment with electrotherapies (cancer, pregnancy, electronic implants, epilepsy, infections, tuberculosis, serious vascular and cardiac diseases), eventual severe neurological impairments and primary or secondary sensory alterations.

At the initial clinical evaluation (T0, before the treatments were performed) and at the final clinical reevaluation (T1, after the treatments were performed), the observed patients were assessed using the following methods:

(a) *The Numeric Pain Rating Scale (NPRS):* it is one of the most widespread tools in clinical practice for assessing the pain subjectively perceived by patients. It is a derivate of the Visual-Analogue Scale (VAS) divided into ten levels, usually distributed equidistant on a 10 cm long strip, which correspond to the level of pain perceived by the patient at the time of the evaluation, where 0 is the total absence of pain and 10 is the maximum level of pain imaginable and/or ever experienced by the patient (23). This scale is reliable, effective and easy to apply even in the presence of dysfunctions of the musculoskeletal system such as MPS (23). In the present study, patients were asked to express a value from 0 to 10 corresponding to the maximum level of pain perceived at the muscular levels which resulted the most insidious points for them.

(b) *Postural Biometric Index (PBI):* this is an index calculated by the software of the Milletrix 3.0 platform (Diasu Health Technologies, Rome, Italy) on the basis of a stabilometric evaluation carried out using the same device (24). This index takes into account the parameters of Center of Pressure, Symmetry of Bipodalic Load, Symmetry of Retro-Forefoot Load, Angle of Centers of Pressure, Podalic Angle, Location of Maximum Pressure Point, Symmetry of Support Surface and Center of Gravity Deviation - Center of Pressure (24). These parameters are then calculated to obtain an index that quantifies the patient's postural state, which can often be altered in the presence of MPS (24). The PBI value is considered healthy from 0 to 10 and dysfunctional if >10.

Patients in the studied population underwent a total of 5 treatment sessions, performed every 48 hours, of N-Fi therapy applied through a device called Sinapsi 2.0 (Winform Medical Engineering S.r.l., San Donà di Piave, Italy). The N-Fi handpiece combines a multi-wavelength LLLT emission (450nm, 650nm, 1064nm) with an endogenous stimulating athermal radiofrequency designed to deliver specific phytocompounds and integrative substances for joints and the musculotendinous system. Through the N-Fi system, the special compound called TriJALUX Gel (Winform Medical Engineering S.r.l., San Donà di Piave, Italy), based on a combination of 5% triple molecular weight hyaluronic acid, 10% ozone, and 2% vitamin C, is conveyed deep into the treated area.

In the observed patients, the N-Fi was performed on multiple body areas in which palpable MTrPs were located. Following the principles of the Bio-Physico-Metric approach (25,26), the presence of MTrPs was checked by the therapist before each treatment session, through a palpatory examination of the patient's body aimed at identifying the most painful and irradiating MTrPs, also defined as key MTrPs. When a potential key MTrP was manually detected, the therapist performed a functional evaluation of the range of motion of the location area; if the range of motion of the suspect area appeared to be reduced in comparison to the contralateral one, the palpated MTrP was considered in need of treatment. The N-Fi was applied on each of the identified key MTrPs for the time necessary for a quantity equal to 1ml of TriJALUX Gel to be absorbed into the area (on average 5 minutes for each spot).

Once all the data consistent with the observation criteria of the study have been catalogued, statistical analysis was carried out on collected data using the Wilcoxon Signed Rank test for dependent samples, performed through the Statistics Kingdom online calculator (https://www.statskingdom.com, Melbourne, Australia).

RESULTS

At the end of the study (T1), a significant reduction in the NPRS score value was observed ($p < 0.001$) which went from 6.2 ± 1.1 to 3.6 ± 1.1, for an overall reduction of 41.9% (Fig.1).

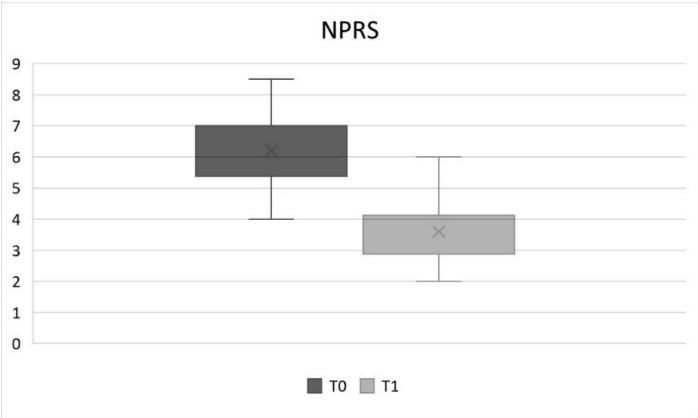

Fig. 1. *Change in NPRS values between T0 and T1.*

Similarly, at time T1, a significant reduction in the PBI value was observed ($p < 0.001$) which went from 15.5 ± 4.4 to 10.7 ± 1.9, for an overall reduction of 31.1% (Fig.2).

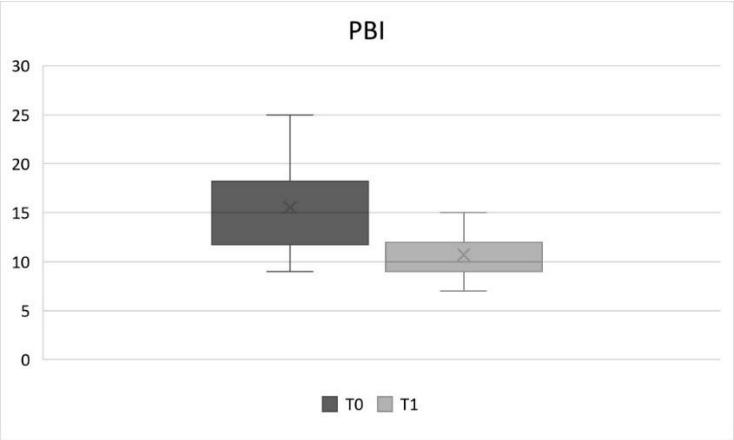

Fig. 2. *Change in PBI values between T0 and T1.*

DISCUSSION

The observation of the data collected highlights how, in patients with MPS subjected to treatment with N-Fi of key MTrPs, there is a significant reduction in NPRS pain values and postural dysfunction measured through the PBI.

We have previously reported that the chemical-physical stimulation of MTrPs through physical and infiltrative therapies appears to be one of the typical management strategies of MPS (3,10-15). The N-Fi treatment strategy adopted for the patients observed in this study conceptually falls into the same therapeutic category reported above. The chemical compound vehiculated through the N-Fi technique is in fact composed of a combination of substances whose role has already been analyzed in literature in the context of MPS and the management of MTrPs.

Several studies have highlighted a very important influence of hyaluronic acid in the genesis and perpetuation of MPS and MTrPs (27,28). It is believed that a variation in the densification of the hyaluronic acid present in the muscle fascia can in fact determine a worsening of the mechanical sliding of the tissues involved in MPS, producing phenomena of functional limitation and pain (27,28). In fact, one of the most interesting options in the management of MTrPs and MPS is represented by the use of hyaluronidase (alone or in addition to other substances) through localized infiltration in the painful areas (29,30), with the aim of dissolving any connective thickening from degeneration of hyaluronic acid *in situ*. In our case, the delivery of chemically stable and non-pathologically altered hyaluronic acid to the MTrPs sites could have contributed to restoring optimal viscosity of the soft tissues of the dysfunctional areas.

Furthermore, the use of ozone (alone or in combination with other molecules, such as oxygen or corticosteroids) would also appear to possess excellent healing properties when applied directly to the muscles, probably due to its anti-inflammatory properties and its ability to control tissue oxidation (31,32).

Similarly, vitamin C also appears to possess important healing properties, especially of an antioxidant nature, even for myofascial tissues, especially in the presence of pathologies such as pain and functional limitation as in the case of MPS (33-35).

We can therefore consider that the metabolic and mechanical rebalancing properties attributable to TriJALUX Gel delivered with N-Fi in the MTrPs site may have contributed, in the observed patients, to improve the monitored symptoms. In fact, the pathogenesis of MPS appears to be extremely complex, involving aspects of a mechanical nature connected to the thickening of the fascial components of the areas involved (36,37), as well as chemical-metabolic aspects due to oxidative and inflammatory phenomena of the affected tissues (38,39). From the point of view of pain, the improvement of the NPRS score, which went from a medium-light pain equal to 6.2 points to an almost absent pain equal to 3.6 points, can be attributed to the anti-inflammatory, antioxidant and elasticizing activity of the delivered product. Similarly, the same modulation properties of the chemical-physical quality of the treated soft tissues due to the vehiculation of the TriJALUX Gel through the N-Fi device may have induced an improvement of the PBI score, which went from a totally dysfunctional value of 15.5 points to one close to the normal cutoff equal to 10.7 points, probably by virtue of better mechanical resilience of the stimulated areas.

Despite the results obtained are positive and encouraging, it is necessary to specify some weaknesses of the present study. First of all, the sample might be relatively small in comparison to the general spreading of MPS. Moreover, in relation to the sample characteristics, it must be highlighted a certain variability in the age of the patients enrolled (ranging

from 30 to 71 years from the youngest to the oldest patients observed) and in the sex distribution, which was not evenly spread between males and females. Additionally, it must be considered that the study, due to its observational nature, was carried out without a control group (either no-treatment or sham) and in the absence of follow-up. To overcome these weaknesses, it would be useful to conduct new in-depth studies on the topic, which should take into consideration a randomized and controlled experimental setting with follow-up, perhaps also integrating more specific evaluation methods dedicated to the histochemical analysis of the treated areas to observe their response to the administration of TriJALUX Gel through N-Fi.

Despite the critical issues mentioned, overall, the results of this study are positive and encouraging, supporting the idea that treatment with TriJALUX Gel delivered with the N-Fi system at the level of MTrPs is able to effectively reduce pain and biomechanical-postural dysfunction in patients affected by MPS. Finally, it should be emphasized that the observed treatment, together with the intrinsic characteristics of speed and ease of application, has shown a very high tolerability; in fact, no local or systemic side effects were reported during the entire data collection process, consistently with the safe and non-invasive nature of the observed treatment.

CONCLUSIONS

The treatment of MPS through the delivery of TriJALUX Gel with the N-Fi system to the MTrPs is effective in reducing pain and improving the dysfunctional biomechanical-postural setting characteristic of the pathology. Since the method is easy to apply and reproducible in the absence of all the side effects potentially related to the classic infiltrative stimulation with needle of the MTrPs, our observations lay the foundations for investigating deeper a method that would allow to expand the group of subjects affected by MPS who could receive a valid treatment for their condition.

Conflict of interest

The authors declare that they have no conflict of interest.

REFERENCES

1. Lu Y, Cheng J, Fan B, et al. ICD-11 Chinese compilation of chronic pain classification. *Zhongguo Tengtong Yixue Zazhi*. 2018;24:801–805.
2. Cao QW, Peng BG, Wang L, et al. Expert consensus on the diagnosis and treatment of myofascial pain syndrome. *World journal of clinical cases*. 2021;9(9):2077-2089.
3. Galasso A, Urits I, An D, et al. A comprehensive review of the treatment and management of myofascial pain syndrome. *Current pain and headache reports*. 2020;24:1-11.
4. Fleckenstein J, Zaps D, Rüger LJ, et al. Discrepancy between prevalence and perceived effectiveness of treatment methods in myofascial pain syndrome: results of a cross-sectional, nationwide survey. *BMC Musculoskeletal Disorders*. *BioMed Central*. 2010;11:1-9.
5. Simons DG, Travel JG, Simons LS. Myofascial Pain and Dysfunction: The Trigger Point Manual (Vol. 1) The Upper Half of Body, 2nd edition. Baltimore: Lippincott Williams & Wilkins; 1999.
6. Fernández-de-Las-Peñas C, Dommerholt J. International consensus on diagnostic criteria and clinical considerations of myofascial trigger points: a Delphi study. *Pain medicine*. 2018;19(1):142-150.
7. Barbero M, Schneebeli A, Koetsier E, Maino P. Myofascial pain syndrome and trigger points: evaluation and treatment in patients with musculoskeletal pain. *Current opinion in supportive and palliative care*. 2019;13(3):270-276.
8. Mazza DF, Boutin RD, Chaudhari AJ. Assessment of myofascial trigger points via imaging: a systematic review. *American journal of physical medicine & rehabilitation*. 2021;100(10):1003-1014.
9. Barassi G, Pellegrino R, Di Matteo C, et al. Bio-Physico-Metric Approach: Assessment and Treatment of Key Myofascial Trigger Points through an Adaptive Neuromodulation Device. *Journal of Biological Regulators and Homeostatic Agents*. 2023;37(1):25-29.
10. Urits I, Charipova K, Gress K, Schaaf AL, et al. Treatment and management of myofascial pain syndrome. *Best Practice & Research Clinical Anaesthesiology*. 2020;34(3):427-448.

11. He P, Fu W, Shao H, et al. The effect of therapeutic physical modalities on pain, function, and quality of life in patients with myofascial pain syndrome: a systematic review. *BMC Musculoskeletal Disorders*. 2023;24(1):376.
12. Walker JW, Shah BJ. Trigger point injections: a systematic, narrative review of the current literature. *SN Comprehensive Clinical Medicine*. 2020;2(6):746-752.
13. Appasamy M, Lam C, Alm J, Chadwick AL. Trigger point injections. *Physical medicine and rehabilitation clinics of North America*. 2022;33(2):307.
14. Bodine N. An overview of myofascial pain syndrome with a focus on trigger point injection. *The Nurse Practitioner*. 2023;48(11):18-25.
15. Fernández-de-Las-Peñas C, Nijs J. Trigger point dry needling for the treatment of myofascial pain syndrome: current perspectives within a pain neuroscience paradigm. *Journal of pain research*. 2019;1899-1911.
16. Cheng J, Abdi S. Complications of joint, tendon, and muscle injections. *Techniques in Regional Anesthesia and Pain Management*. 2007;11(3):141-147.
17. Reurink G, Goudswaard GJ, Moen MH, Weir A, Verhaar JA, Tol JL. Myotoxicity of injections for acute muscle injuries: a systematic review. *Sports Medicine*. 2014;44:943-956.
18. Dixit N, Bali V, Baboota S, Ahuja A, Ali J. Iontophoresis-an approach for controlled drug delivery: a review. *Current drug delivery*. 2007;4(1):1-10.
19. Machet L, Boucaud A. Phonophoresis: efficiency, mechanisms and skin tolerance. *International journal of pharmaceutics.* 2002;243(1-2):1-15.
20. De Sanctis V, Soliman AT, Daar S, Tzoulis P, Fiscina B, Kattamis C. Retrospective observational studies: Lights and shadows for medical writers. *Acta Bio Medica Atenei Parm*. 2022;93:e2022319.
21. Winter EM, Maughan RJ. Requirements for ethics approvals. *Journal of Sports Sciences*. 2009;27:985.
22. Tantanatip A, Chang KV. Myofascial Pain Syndrome. In StatPearls. StatPearls Publishing. Treasure Island (FL), 2023.
23. Cheatham SW, Kolber MJ, Mokha M, Hanney WJ. Concurrent validity of pain scales in individuals with myofascial pain and fibromyalgia. *Journal of Bodywork and Movement Therapies*. 2018;22(2):355-360.
24. Barassi G, Di Simone E, Galasso P, et al. Posture and health: are the biomechanical postural evaluation and the postural evaluation questionnaire comparable to and predictive of the digitized biometrics examination? *International Journal of Environmental Research and Public Health*. 2021;18(7):3507.
25. Barassi G, Di Simone E, Supplizi M, et al. Bio-Physico-Metric approach: Integrated postural assessment in musculoskeletal dysfunctions. *Journal of Biological Regulators and Homeostatic Agents*. 2022; 36(1):129-135.
26. Barassi G, Pellegrino R, Di Matteo C, et al. Bio-Physico-Metric Approach: Assessment and Treatment of Key Myofascial Trigger Points through an Adaptive Neuromodulation Device. *Journal of Biological Regulators and Homeostatic Agents*. 2023;37(1):25-29.
27. Stecco C, Stern R, Porzionato A, et al. Hyaluronan within fascia in the etiology of myofascial pain. *Surgical and radiologic anatomy*. 2011;33:891-896.
28. Ganjaei KG, Ray JW, Waite B, Burnham KJ. The fascial system in musculoskeletal function and myofascial pain. *Current Physical Medicine and Rehabilitation Reports*. 2020;8:364-372.
29. Ghasemi M, Mosaffa F, Hoseini B, Behnaz F. Comparison of the effect of bicarbonate, hyaluronidase, and lidocaine injection on myofascial pain syndrome. *Anesthesiology and Pain Medicine*. 2020;10(3).
30. Choi JW, Lee CJ, Lee SM, Shin BS, Jun B, Sim WS. Effect of hyaluronidase addition to lidocaine for trigger point injection in myofascial pain syndrome. *Pain Practice*. 2016;16(8):1019-1026.
31. Hidalgo-Tallón FJ, Torres-Morera LM, Baeza-Noci J, Carrillo-Izquierdo MD, Pinto-Bonilla R. Updated review on ozone therapy in pain medicine. *Frontiers in Physiology*. 2022;13: 840623.
32. Eldemrdash A, Tairy T, Sabry L, Aelmulla A, Kamel M, Yousry E. Efficacy of Medical Ozone for Treatment of Chronic Musculoskeletal Pain with Abnormal Mitochondrial Redox State: Prospective Randomized Clinical Trial. *Pain Physician*. 2024;27(4):E371.

33. Koca İ, Tutoglu A, Boyacı A, et al. An evaluation of oxidative stress and antioxidant capacity in patients with myofascial pain syndrome. *Modern rheumatology*. 2014;24(6):992-996.
34. Lalchhuanawma A. Finding the possible link between physical activities, dietary nutrients and health on myofascial pain syndrome. *Current Medicine Research and Practice*. 2021;11(4):176-180.
35. Grazio S, Balen D. Complementary and alternative treatment of musculoskeletal pain. *Acta Clinica Croatica*. 2011;50(4):513-530.
36. Qureshi NA, Alsubaie HA, Ali GI. Myofascial pain syndrome: a concise update on clinical, diagnostic and integrative and alternative therapeutic perspectives. *International Neuropsychiatric Disease Journal*. 2019;13(1):1-14.
37. Stecco A, Gesi M, Stecco C, et al. Fascial components of the myofascial pain syndrome. *Current pain and headache reports*. 2013;17:1-10.
38. Jafri MS. Mechanisms of myofascial pain. *International scholarly research notices*. 2014;2014(1):523924.
39. Duarte FC, West DW, Linde LD, Hassan S, Kumbhare DA. Re-examining myofascial pain syndrome: Toward biomarker development and mechanism-based diagnostic criteria. *Current rheumatology reports*. 2021;23:1-10.

European Journal of Musculoskeletal Diseases
ISSN 2038-4106 print - ISSN 2975-044X online

Review

UNDERSTANDING GLUTEAL TENDINOPATHY: DIAGNOSIS AND TREATMENT. A NARRATIVE REVIEW

D. Tarantino[1], R. Pellegrino[2,3*], A. Di Iorio[4], R. Mottola[5], R. Saggini[6], C. Ruosi[7] and R. Aicale[8]

[1] Department of Public Health, University of Naples Federico II, Naples, Italy;
[2] Department of Medicine, LUM University, 70010 Casamassima, Italy;
[3] Santa Chiara Institute, Lecce, 73100, Italy;
[4] Department of Innovative Technologies in Medicine & Dentistry, University "G. d'Annunzio", Chieti-Pescara, 66100, Italy;
[5] Department of Public Health, University of Naples Federico II, 80131 Naples, Italy;
[6] Faculty of Psychology, ECampus University, Novedrate, Italy;
[7] Department of Public Health, University of Naples Federico II, Naples, Italy;
[8] Department of Orthopaedic and Trauma Surgery, Casa di Cura di Bernardini, 74121 Taranto, Italy.

**Corresponding author:*
Raffaello Pellegrino, MD
Department of Medicine,
LUM University,
70010 Casamassima, Italy.
e-mail: r.pellegrino@lum.it

ABSTRACT

Gluteal tendinopathy, a prevalent cause of lateral hip pain, primarily affects the tendons of the gluteus medius (GMed) and minimus (GMin). This condition is commonly seen in middle-aged women and athletes, often resulting from repetitive stress, overuse, or biomechanical abnormalities. Diagnosing gluteal tendinopathy requires a comprehensive approach including patient history, physical examination, and imaging modalities such as ultrasound (US) or magnetic resonance imaging (MRI), which are essential for confirming tendon pathology and ruling out other hip pathologies. Management strategies focus on conservative treatments as the first line of intervention. These include patient education, activity modification, drugs, and structured physiotherapy programs emphasizing load management and progressive strengthening exercises. Adjunct therapies like extracorporeal shockwave therapy (ESWT) and corticosteroid (CS) injections can be considered in persistent cases. Surgical intervention is reserved for refractory cases where conservative treatments fail. This review aims to consolidate current diagnostic criteria, highlight effective management protocols, and discuss emerging treatments for gluteal tendinopathy to optimize patient outcomes.

KEYWORDS: *tendinopathy, gluteal tendinopathy, gluteal tendinitis, gluteal tendinosis, gluteal bursitis, hip tendinopathy, greater trochanteric pain*

INTRODUCTION

Tendon disorders encompass tears and chronic diseases, representing a very common musculoskeletal issue (1). The term "tendinopathy" includes all the situations in which there are chronic clinical conditions characterized by pain,

Received: 26 October 2024
Accepted: 16 December 2024

ISSN 2038-4106 print
ISSN 2975-044X online Copyright © by BIOLIFE 2024
This publication and/or article is for individual use only and may not be further reproduced without written permission from the copyright holder. Unauthorized reproduction may result in financial and other penalties. Disclosure: All authors report no conflicts of interest relevant to this article.

swelling and functional limitations of tendons and nearby structures (1–7). Both intrinsic and extrinsic factors play a key role in the pathogenesis of tendinopathy; age, gender and gender are the most prominent non-modifiable factors, while excessive and/or improper loading, disuse, drugs and smoking habit are the most influent modifiable factors (6,8-12). Although the term "tendinitis" is often associated with the concept of tendinopathy, in recent years it has been shown that the inflammatory process only affects the initial stages of the disease, while degenerative and apoptotic phenomena prevail afterwards because of long-lasting overuse condition related to work and/or sports (7,13-15). Tendinopathy can be viewed as a failure of the cell matrix to adapt to a variety of stresses as a result of an imbalance between matrix degeneration and synthesis (16-18).

Gluteal tendinopathy (GT), widely regarded as the primary condition underlying greater trochanteric pain syndrome (GTPS), and often associated with trochanteric bursitis (19-22), is the most prevalent lower limb tendinopathies (up to 24% of middle-aged women) (23-25). The condition predominantly arises within individuals in their fifth and sixth decade of life, affecting both active and sedentary individuals (26), with an annual incidence of 1.8 per 1000 individuals (27), and a global prevalence of 20.2% (28). It affects individuals with an age range of 15–87 years and an average age of 54 to 63 years (17). Women are typically more affected when compared to men (21,23,28).

Although GTPS is a complex condition of uncertain etiology, contemporary thought supports degenerative changes about the gluteus medius (GMed) and minimus (GMin) tendon insertions; inflammation within the greater trochanteric, subgluteus medius, and/or subgluteus minimus bursae; and proximal iliotibial band pathology being primary contributors to the condition (29,30).

It is reasonable to assume that the pathomechanics underlying the development of GT are similar to those proposed for other insertional tendinopathies: relatively increased (overload) (31,32) or decreased (stress/load shielding) (33,34) tensile load applied longitudinally along the tendon, excessive transverse load applied across the tendon (compression, mostly at or near the bony insertion) (33,35), and most often a combination of these factors (36). The combination of tensile and compressive overload appears to be particularly damaging (37). Matrix degradation associated with any of these adverse loading scenarios can reduce the tensile load-bearing capacity of the tendon and predispose it to tearing at relatively lower tensile load (33).

Patients with GTPS experience pain originating in the structures of the lateral hip (22) that can manifests itself chronically, intermittently or continuously, and may radiate to the distal thigh (38-40) (Fig.1).

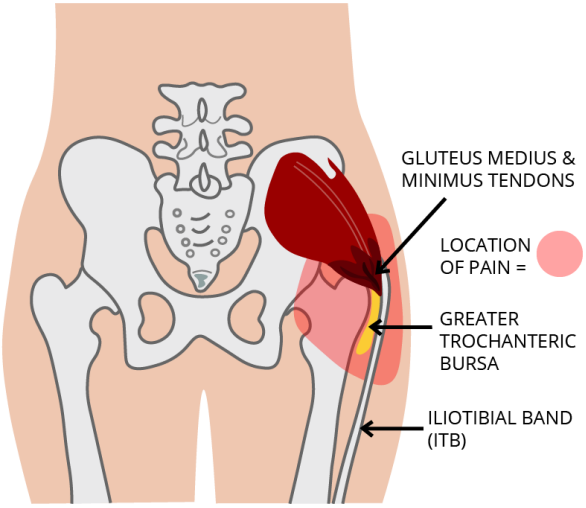

Fig. 1. *Pain location in gluteal tendinopathy. Retrieved from:* https://www.upsidehealth.com.au/blog/pain-profile-gluteal-tendinopathy

Pain and tenderness on palpation of the greater trochanter are regarded as the main diagnostic criteria for gluteal tendinopathy (29,40), while the use of imaging techniques such as ultrasound (US) and magnetic resonance imaging (MRI) is usually reserved for those cases in which severe conditions such as partial or full-thickness tears are suspected (41,42) (Fig.2).

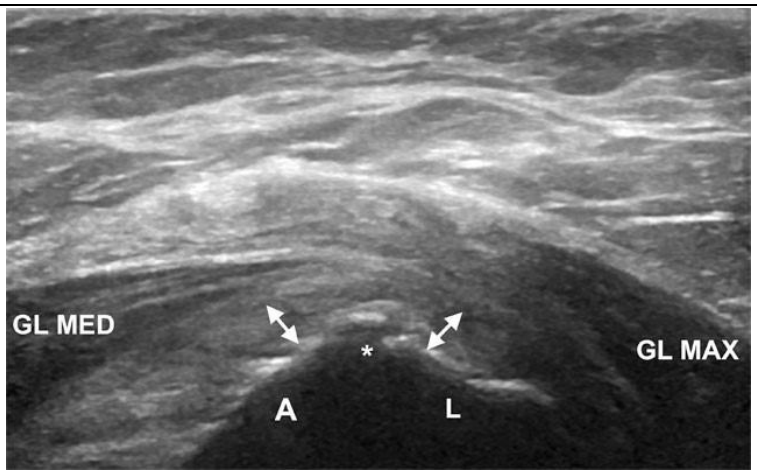

Fig. 2. *Transverse image over the greater trochanter showing the bony apex (asterisk) between the GMin tendon (double arrow) insertion onto the anterior facet* ***(A)*** *and the GMed tendon (double arrow) insertion onto the lateral facet* ***(L)****. Retrieved from: Yeap PM, Robinson P. Ultrasound Diagnostic and Therapeutic Injections of the Hip and Groin. J Belg Soc Radiol. 2017 Dec 16;101(Suppl 2):6.*

Gluteal tendinopathy/GTPS can substantially affect a patient's quality of life (22,26,39). Sleep disturbances are a common symptom because direct pressure on the lateral hip while lying on one's side can cause substantial discomfort (43,44). Moreover, the pain commonly experienced with weight-bearing activities, such as walking and stair climbing, can result in reduction of overall physical activity levels, placing patients at risk for the development of general disability and potentially affecting employment status (39,45).

Current literature suggests that excessive compression and high tensile loads within tendons (46), excessive hip adduction, and poor muscle and bone quality with increased age can exacerbate abnormal hip biomechanics (26). Furthermore, a temporal relationship between gluteal tendinopathy and the development of femoroacetabular osteoarthritis has also been postulated (47). As the average life expectancy continues to rise, there has been growing clinical recognition of gluteal tendinopathy and expanding interest in treatment options and their scientific support (26).

Several treatments have been described for managing gluteal tendinopathy/GTPS, including topical or systemic analgesics (38), physical therapy (PT) and exercise programs (29,45,48), extracorporeal shockwave therapy (ESWT) (49-52), and injections (autologous tenocyte, corticosteroids [CS], and platelet-rich plasma [PRP]) (45,48,53,54). Surgical management is typically reserved for intractable cases or individuals with imaging findings consistent with substantial partial-thickness or full-thickness tears of the gluteal tendons (26).

The aim of this narrative review is to give readers a comprehensive overview of the diagnosis and management of GT.

METHODS

All the procedures related to this review were organized and reported after performing a search in the main scientific electronic databases (PubMed, Scopus, and Web of Science) to identify the available scientific articles about the diagnosis and management of GT, with no restrictions of time. Only articles written in English were included. Two independent reviewers (R.A. and R.P.) extracted and evaluated the data. The included articles reported on the diagnosis and treatment of GT.

The authors also evaluated the reference lists of the included articles but eventually found no extra articles to be included.

For the purposes of our review, we used several combinations of the following keywords: gluteal tendinopathy, gluteal tendinopathy diagnosis, gluteal tendinopathy management, gluteal tendinopathy treatment, etc., in combination or using Boolean operators, such as “gluteal” AND “tendinopathy” AND (“management” OR “treatment”).

All kinds of articles, such as systematic reviews and meta-analyses, randomized clinical trials (RCTs), prospective, retrospective, and case-series studies were included to give readers the most comprehensive overview about GT’s diagnosis and management.

DISCUSSION

Diagnosis

The differential diagnosis of lateral hip pain may be challenging because of the possibility of referral from sources other than the local soft tissues of the greater trochanter—most commonly, the lumbar spine and hip joint (38,55,56). The patient interview provides important clues for the differential diagnosis and directs the subsequent physical examination. Imaging may be required where the diagnosis is unclear, and the patient fails to progress (38).

The most useful features in differentiating GT are the area of pain, behavior of symptoms and absence of other features that are more indicative of hip osteoarthritis or lumbar-related pain (57).

GT is characterized by pain and tenderness over the greater trochanter, sometimes extending down the lateral thigh and upper leg. The onset of pain is frequently insidious, tends to worsen over time and is sometimes associated with changes in training load or physical activity, though it can occur acutely after a strong contraction of the abductor musculature, such as that occurring during a slip or fall or a forceful sporting action, such as a sidestep (38,58,59). Pain is often worse at night, with those affected having difficulty sleeping on their side (20).

The impact of this condition can be debilitating, as it typically disturbs sleep and causes functional difficulties associated with pain on single-leg loading (stair-climbing, walking, dressing) (44,58,59).

Pain on palpation (direct compression) of the soft tissues overlying the greater trochanter is generally regarded as the most important sign in the diagnosis of GT. There is a consensus that this represents a cardinal sign for the diagnosis of lateral hip tendinous or bursal pathology (44,56,60-63). An absence of tenderness on palpation of the greater trochanter should raise suspicion that the source of the pain may be different and would warrant a search for an alternative diagnosis (38).

Several clinical diagnostic tests are available for the diagnosis of GT: however, a recent meta-analysis of the diagnostic accuracy of clinical hip tests found only three studies of GT of adequate quality (44,60,61) and reported that the tests generally possessed weak diagnostic properties (64).

The three studies, considered of adequate quality, included the single-leg stance test and resisted medial and lateral rotation and abduction (40,60,61). These studies all had imaging evidence of local pathology at the greater trochanter as the reference test, with a predominance of findings indicating GT. The flexion/abduction/external rotation (FABER) and Ober tests were evaluated in addition to the above tests (36,38). These diagnostic tests generally impart either a tensile or compressive load (or a combination of both) across the gluteal tendons. The most useful diagnostic properties were reported by Lequesne et al. (61), who tested resisted hip internal rotation at 90° hip flexion and maximal external rotation (Fig.3).

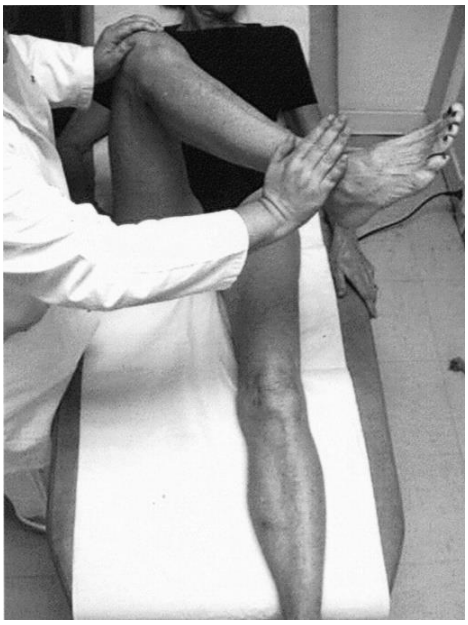

Figure 3. *Resisted external derotation test. The hip is flexed 90°, and the patient is asked to return the leg to the axis of the table against resistance. The test result is positive when the usual pain is reproduced. Retrieved from: Lequesne M, Mathieu P, Vuillemin-Bodaghi V, Bard H, Djian P. Gluteal tendinopathy in refractory greater trochanter pain syndrome: diagnostic value of two clinical tests. Arthritis Rheum. 2008 Feb 15;59(2):241-6.*

Radiography, MRI, US, and scintigraphic imaging have all been reported in the literature as helpful adjuncts in clarifying the diagnosis of GT (36).

Early imaging may be required following acute trauma and/or a marked loss of function (38). Imaging of the hip and lumbar spine may also assist if the differential diagnosis is unclear. Caution is required, as tendon and lumbar pathology often coexist and occur frequently in the asymptomatic population (19,65). To be relevant, diagnosis should not rely solely on imaging studies but should correlate with clinical features (36,38).

US and MRI are the predominant investigations for lateral hip pain. US is usually offered first, because of cost and availability (38). US is less sensitive than MRI for detection of minor changes in tendon structure, as a consequence of limitations in the resolution of greyscale imaging (66).

US has been reported to have a high sensitivity of 79% to 100% and a positive predictive value of 95% to 100% for gluteal tendon tears but requires a skilled practitioner (42,67). MRI has been shown to be an accurate means of diagnosing gluteal tendon tears, with a reported sensitivity of 73% and specificity of 95% for the presence of tears (68).

Distention of the bursa is readily evident on ultrasound (56), and ultrasound is superior to MRI with respect to imaging calcifications within the tendon (69) (Fig.4).

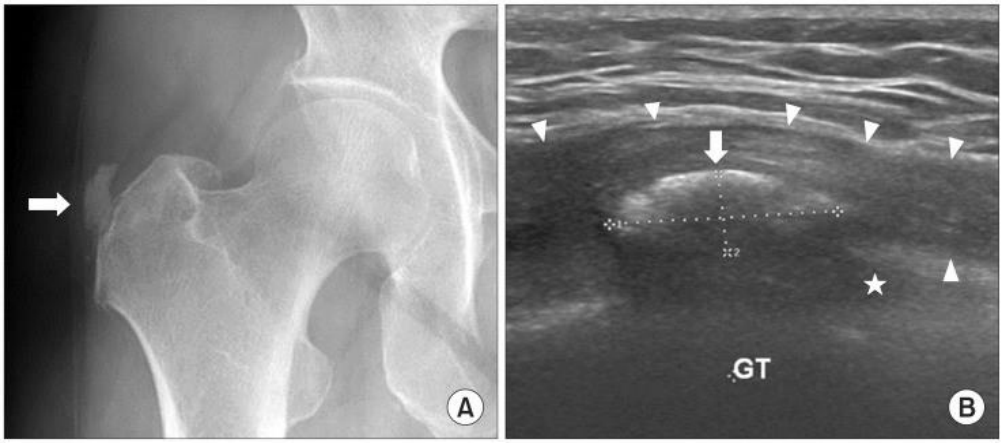

Fig. 4. ***(A)*** *An anteroposterior radiograph of the right hip showing an amorphous calcification (white arrow) adjacent to the greater trochanter.* ***(B)*** *Ultrasonography of the right hip showing a solid calcific nodule (white arrow) at 2.0 cm×0.7 cm in size adjacent to the insertion site of the gluteus medius tendon (asterisk) between the greater trochanter (GT) and the iliotibial band (arrowheads). Retrieved from: Jo H, Kim G, Baek S, Park HW. Calcific Tendinopathy of the Gluteus Medius Mimicking Lumbar Radicular Pain Successfully Treated With Barbotage: A Case Report. Ann Rehabil Med. 2016 Apr;40(2):368-72.*

Treatment

The best management of GT is still under debate, since the proposed treatments lack strong evidence-based support.

A recent review could not draw definitive conclusions, because of limited availability of studies of adequate quality (70). Many of the proposed treatment modalities are yet to be tested in randomized clinical trials. Management techniques include exercise and strategies to manage tendon load, ESWT, CS and PRP injections, and surgical interventions.

Physical therapy is usually advocated as a first-line therapy given the well reported outcomes in the treatment of lower limb tendinopathies (71-74). In the context of GT, physical therapy is aimed at reducing compression on the greater trochanter and to control provocative tensile load. The most useful exercises include isometric, low-velocity, high-tensile load, strengthening exercises (36) (Fig.5).

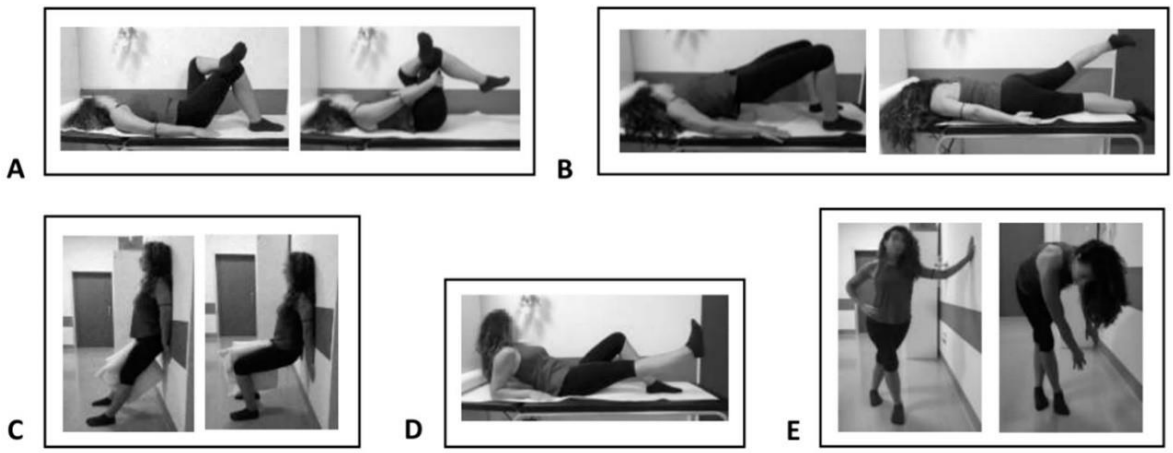

Fig. 5. *Eccentric therapeutic exercise: Piriformis muscle stretching (**A**); gluteal muscle stretching (**B**); wall squat with a ball (**C**); leg lift (**D**); and iliotibial band stretching (**E**). Retrieved from: Notarnicola A, Ladisa I, Lanzilotta P, Bizzoca D, Covelli I, Bianchi FP, Maccagnano G, Farì G, Moretti B. Shock Waves and Therapeutic Exercise in Greater Trochanteric Pain Syndrome: A Prospective Randomized Clinical Trial with Cross-Over. J Pers Med. 2023 Jun 10;13(6):976.*

Especially regarding GT, a recent systematic review and meta-analysis by Patricio Cordeiro et al. (29) showed that exercise therapy is superior to minimal intervention (sham exercise or wait-and-see) for function/symptom severity in patients with GT in the short- and long-term. However, this difference was not observed between these interventions for short- and long-term quality of life.

Similarly, the effect of physical therapy was no different from CS injections for pain intensity in the short- and long-term, however, exercise showed a higher treatment success rate when compared to CS infiltration both in the short- and long-term in individuals with GT. However, the authors found low or very low certainty of evidence for these comparisons.

ESWT was reported as effective in reducing lateral hip pain from grades 1 to 3 GT according to the classification of tendinopathy made by Bhabra et al. (75) and revised by Ladurner et al. (76) (Fig.6).

Fig. 6. *The patient is positioned on the side and the treatment probe is placed on the trochanteric area. Retrieved from: Notarnicola A, Ladisa I, Lanzilotta P, Bizzoca D, Covelli I, Bianchi FP, Maccagnano G, Farì G, Moretti B. Shock Waves and Therapeutic Exercise in Greater Trochanteric Pain Syndrome: A Prospective Randomized Clinical Trial with Cross-Over. J Pers Med. 2023 Jun 10;13(6):976.*

In the study by Carlisi et al. (49), pain was significantly lower in both short- and- mid-term using focused ESWT, also achieving better pain reduction compared with therapeutic ultrasound at short- and mid-term follow-up. However, no significant benefit in functional scores between the groups was detected.

Seo et al. (50) assessed the tendon abnormality and outcome for patients with GT documented by MRI. In their study, the use of low-energy ESWT led to a significant decrease of pain at immediate and long-term follow-up. Success rates, measured with Roles-Maudsley score, also were 83.3% and 55.6% at immediate and long-term follow-up, respectively.

The authors then suggested that low-energy ESWT can be an effective treatment for pain relief in chronic GT. However, its long-term effect appears to decrease with time.

Although SWT might be effective for management of GT, high-quality trials are required to test its efficacy, and cost and availability may also limit its clinical applicability (38).

Furthermore, no standard protocol for ESWT in GT has been established yet according to the current available literature.

Injections represent another option for the treatment of GT (Fig.7).

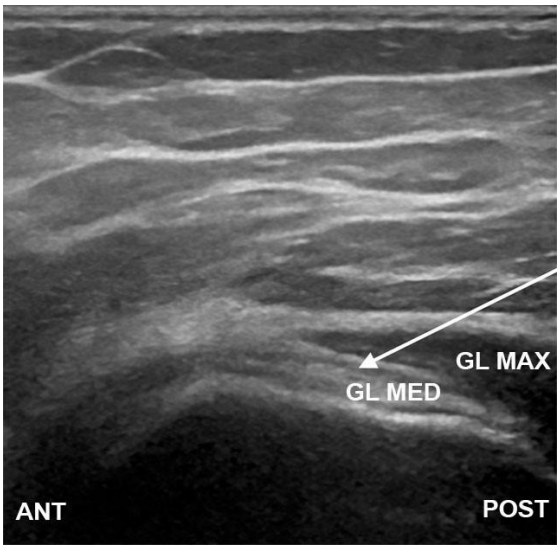

Fig. 7. *Transverse plane over the greater trochanter. The needle is advanced into the tissue plane between the gluteal maximus-iliotibial band and GMed tendon from a posterior approach (arrow). Retrieved from: Yeap PM, Robinson P. Ultrasound Diagnostic and Therapeutic Injections of the Hip and Groin. J Belg Soc Radiol. 2017 Dec 16;101(Suppl 2):6.*

CS injection provides a substantial early reduction in pain for those with GMed tendinopathy, with a 72–75 % positive response at 4 weeks (77,78). As patients and their medical practitioners aim to achieve early pain relief, it is not surprising that CS injections are commonly recommended (63,77,79). However, CS injection does not completely alleviate the pain (average pain reduction 55 % (77), and medium- and longer-term responses are much lower than its initial effects. Positive responses drop to 41–55 % at 3–4 months (40,63,80), and after 12 months, Brinks et al. (40) showed no difference in outcomes between subjects receiving CS injection and those receiving usual care (analgesics as required). This pattern of poorer outcomes in the longer term, with high rates of recurrence, has been shown for other insertional tendinopathies (38). Furthermore, the way CS injections work for treatment of tendinopathy, and the safety, particularly of repeated use, remain unclear, given the absence of substantial signs of inflammation in tendinopathies and the tenotoxicity revealed in several studies (81,82).

Two studies performed by Fitzpatrick et al. (83,84) compared the outcomes of a single leukocyte-rich PRP (LR-PRP) injection to those of a single CS. The Authors reported favorable 2-year outcomes of a single LR-PRP injection for patients with grades 1, 2, and 3 tendinopathy. While an equal effect size for LR-PRP and CS was seen up to the 6-week follow-up, the outcomes were significantly higher in the LR-PRP group at 12 weeks and thereafter from baseline. An ongoing benefit was observed over a period of 2 years. Instead, the effect of a single CS declined at 24 weeks.

Lee et al. (85) reported favorable results for a single PRP injection with concomitant needle tenotomy of the gluteal tendons. Statistically significant and clinically important (greater than the minimal clinically important difference) improvements in the evaluated scores were shown over a mean follow-up time of 19.7 months.

Jacobson et al. (86) found that a PRP injection or sonography-guided tendon fenestration led to an alleviation of pain in patients with grades 1 and 2 tendinopathy, with no statistical difference between the two treatment methods. However, the short follow-up of only 2 weeks does not sufficiently support its use.

A retrospective cohort analysis conducted by the same group (87) concluded that 54% of patients treated using tendon fenestration for grade 2 or 3 tendinopathy of the GMed or GMin tendon reported marked improvement of their symptoms.

The treatment effect of a single PRP injection plus tendon fenestration as reported by Lee et al. (85) was not superior to the effect of a single PRP injection alone shown by Fitzpatrick et al. (84).

A promising intervention was performed by Bucher et al. (88) who investigated the effect of autologous tenocyte injections on clinical outcomes in patients with grade 1, 2, or 3 GT. The authors showed significant improvements in the considered scores at 12 months from baseline, and clinical outcomes were sustained to 24 months.

For those with GT who have failed conservative treatment, surgical intervention is considered (38). The evidence for outcomes of surgical repair of gluteal tendon tears is limited to case reports, which provide only weak evidence. Patients who have failed conservative rehabilitation, had significant abductor muscle weakness and had a muscle tear identified on MRI are generally reported to do well in the 1- to 2-year follow-up period following surgery.

Gluteal tendon repairs can now be performed endoscopically (89-91), which is less invasive and is associated with reduced post-operative infection, scarring and pain, and more accelerated rehabilitation (89). Endoscopic techniques, however, require greater surgical skills and are generally unsuitable for larger tears or tendon detachments where there is retraction of the muscle and greater visualization is required (91). Endoscopic repairs have returned good to excellent results in the limited case series available (90,91), but no randomized clinical trials have compared outcomes of open and endoscopic techniques.

Endoscopic gluteal tendon repair was reported by Thaunat et al. (92) and Hartigan et al. (93) and both achieved significant improvements in pain and function. The follow-up time was 32 and 38 months, respectively. The reported failure rate of repair was 4.5%. Complication rates varied. Makridis et al. (94) reported a surgical failure rate of 16%, while Walsh et al. (91) reported a rate of 19%.

Good results for open repair of partial- and full-thickness tears were also found by Fearon et al. (67), Walsh et al. (91) and Davies et al. (95), who reported overall high satisfaction after open repair, with postoperative improvements maintained over 5 years.

Open tendon repair using synthetic augmentation was proposed for high-grade partial- and full-thickness tears by Ebert et al. (96) The Authors reported good clinical and functional outcomes and meaningful improvements in PROM scores (96% patient satisfaction) at 12 months. The retear rate was 2.7%, and the overall complication rate was 6.3% (revision surgery in 1.8%). Bucher et al. (97) and Huxtable et al. (98) achieved excellent results using the same technique.

Surgical interventions performed either as an open or an arthroscopic procedure have also been adopted for patients without gluteal tears, with the main aim being to remove the trochanteric bursa (especially in case of recalcitrant bursitis) and usually release the iliotibial band (ITB). All studies (case series) have reported good to excellent short- to medium-term outcomes.

CONCLUSIONS

GT is a degenerative condition in both sedentary and athletic adults, particularly females aged over 40 years. GT has major implications on patients' quality of life. Overall, 10% to 40% of patients with GT have unsuccessful nonoperative treatment (91).

As the treatment method of choice may change with deterioration of the tendon, early diagnosis of the stage of the disease and the initiation of a stage-adjusted treatment are fundamental (76).

The evidence for the best management is poor, and the underlying mechanisms of the condition are only beginning to be understood. Compression and stress shielding of the deep fibers of the gluteal tendons in hip adduction are likely to be central to the development of tendon degeneration (38).

Nonoperative measures should be applied to treat low-grade GT. According to the available scientific evidence, a single LR-PRP injection seems to be a reasonable option. ESWT shows promising results. Exercise therapy improves patient satisfaction; anyway, specific treatment protocols for ESWT and physical therapy are lacking. CS show good short-term outcomes, while the long-term effect is inferior to results obtained using PRP (76).

Endoscopic or open bursectomy with or without ITB release is a valuable option in low-grade tendinopathy refractory to nonoperative treatment. The reported complication rates for these soft tissue interventions are low. Surgical interventions showed favorable outcomes for the treatment of partial- and full-thickness tears (76).

High-quality trials are required to test the short- and long-term efficacy and safety of current and emerging methods of management. Clarification of underlying mechanisms may guide development of more robust management strategies (38).

Conflict of interest
The authors declare that they have no conflicts of interest regarding this study.

Funding
No external funding has been received to carry out the research.

REFERENCES

1. Aicale R, Tarantino D, Maffulli N. Basic Science of Tendons. In: Gobbi A, Espregueira-Mendes J, Lane JG, Karahan M. Bio-orthopaedics: A New Approach [Internet]. Berlin, Heidelberg: *Springer;* 2017. p. 249–73.
2. Aicale R, Tarantino D, Maffulli N. Overuse injuries in sport: a comprehensive overview. *J Orthop Surg*. 2018;13(1):309.
3. Tarantino D, Palermi S, Sirico F, Corrado B. Achilles Tendon Rupture: Mechanisms of Injury, Principles of Rehabilitation and Return to Play. *J Funct Morphol Kinesiol*. 2020;5(4):95.
4. Tarantino D, Palermi S, Sirico F, Balato G, D'Addona A, Corrado B. Achilles tendon pathologies: How to choose the best treatment. 2020; *Journal of Human Sport and Exercise*. 2020;15(Proc4):S1300-S1321.
5. Tarantino D, Aicale R, Maffulli N. Achilles Tendinopathy. In: Evidence-Based Orthopedics [Internet]. John Wiley & Sons, Ltd; 2021. p. 849–52.
6. Loiacono C, Palermi S, Massa B, et al. Tendinopathy: Pathophysiology, Therapeutic Options, and Role of Nutraceutics. A Narrative Literature Review. *Medicina (Mex)*. 2019;55(8):447.
7. Aicale R, Tarantino D, Maffulli N. Non-insertional Achilles Tendinopathy: State of the Art. In: Canata GL, d'Hooghe P, Hunt KJ, Kerkhoffs GMMJ, Longo UG. Sports Injuries of the Foot and Ankle: A Focus on Advanced Surgical Techniques [Internet]. Berlin, Heidelberg: *Springer*; 2019. p. 359–67.
8. Bisaccia DR, Aicale R, Tarantino D, Peretti GM, Maffulli N. Biological and chemical changes in fluoroquinolone-associated tendinopathies: a systematic review. *Br Med Bull*. 2019;130(1):39–49.
9. Tarantino D, Mottola R, Resta G, et al. Achilles Tendinopathy Pathogenesis and Management: A Narrative Review. *Int J Environ Res Public Health*. 2023;20(17):6681.
10. de Sire A, Lippi L, Mezian K, et al. Ultrasound-guided platelet-rich-plasma injections for reducing sacroiliac joint pain: A paradigmatic case report and literature review. *J Back Musculoskelet Rehabil*. 2022;35(5):977–82.
11. Pellegrino R, Di Iorio A, Filoni S, et al. Radial or Focal Extracorporeal Shock Wave Therapy in Lateral Elbow Tendinopathy: A Real-Life Retrospective Study. *Int J Environ Res Public Health*. 2023;20(5):4371.
12. Maffulli N, Aicale R, Tarantino D. Tendinopathy of the Achilles Tendon. In: Allegra F, Cortese F, Lijoi F. Ankle Joint Arthroscopy: A Step-by-Step Guide [Internet]. Cham: *Springer International Publishing*; 2020. p. 227–37.
13. Maffulli N, Wong J, Almekinders LC. Types and epidemiology of tendinopathy. *Clin Sports Med*. 2003;22(4):675–92.
14. Maffulli N, Aicale R, Tarantino D. Autograft Reconstruction for Chronic Achilles Tendon Disorders. *Tech Foot Ankle Surg*. 2017;16(3):117.
15. Pellegrino R, Brindisino F, Barassi G, et al. Combined ultrasound guided peritendinous hyaluronic acid (500-730 Kda) injection with extracorporeal shock waves therapy vs. extracorporeal shock waves therapy-only in the treatment of shoulder pain due to rotator cuff tendinopathy. A randomized clinical trial. *J Sports Med Phys Fitness*. 2022;62(9):1211–8.
16. Riley GP, Curry V, DeGroot J, et al. Matrix metalloproteinase activities and their relationship with collagen remodelling in tendon pathology. *Matrix Biol J Int Soc Matrix Biol*. 2002;21(2):185–95.
17. Leadbetter WB. Cell-matrix response in tendon injury. *Clin Sports Med*. 1992;11(3):533–78.
18. Pellegrino R, Paolucci T, Brindisino F, et al. Effectiveness of High-Intensity Laser Therapy Plus Ultrasound-Guided Peritendinous Hyaluronic Acid Compared to Therapeutic Exercise for Patients with Lateral Elbow Tendinopathy. *J Clin Med*. 2022;11(19):5492.
19. Blankenbaker DG, Ullrick SR, Davis KW, De Smet AA, Haaland B, Fine JP. Correlation of MRI findings with clinical findings of trochanteric pain syndrome. *Skeletal Radiol*. 2008;37(10):903–9.
20. Connell DA, Bass C, Sykes CAJ, Young D, Edwards E. Sonographic evaluation of gluteus medius and minimus tendinopathy. *Eur Radiol*. 2003;13(6):1339–47.
21. Long SS, Surrey DE, Nazarian LN. Sonography of greater trochanteric pain syndrome and the rarity of primary bursitis. *AJR Am J Roentgenol*. 2013;201(5):1083–6.
22. Fearon AM, Grimaldi A, Mellor R, et al. ICON 2020-International Scientific Tendinopathy Symposium Consensus: the development of a core outcome set for gluteal tendinopathy. *Br J Sports Med*. 2024;58(5):245–54.
23. Segal NA, Felson DT, Torner JC, et al. Greater trochanteric pain syndrome: epidemiology and associated factors. *Arch Phys Med Rehabil*. 2007;88(8):988–92.

24. Williams BS, Cohen SP. Greater trochanteric pain syndrome: a review of anatomy, diagnosis and treatment. *Anesth Analg*. 2009;108(5):1662–70.
25. Albers IS, Zwerver J, Diercks RL, Dekker JH, Van den Akker-Scheek I. Incidence and prevalence of lower extremity tendinopathy in a Dutch general practice population: a cross sectional study. *BMC Musculoskelet Disord*. 2016;17:16.
26. Dancy ME, Alexander AS, Clark CJ, et al. Gluteal Tendinopathy: Critical Analysis Review of Current Nonoperative Treatments. *JBJS Rev*. 2023;11(10).
27. Lievense A, Bierma-Zeinstra S, Schouten B, Bohnen A, Verhaar J, Koes B. Prognosis of trochanteric pain in primary care. *Br J Gen Pract J R Coll Gen Pract*. 2005;55(512):199–204.
28. Tortolani PJ, Carbone JJ, Quartararo LG. Greater trochanteric pain syndrome in patients referred to orthopedic spine specialists. *Spine J Off J North Am Spine Soc*. 2002;2(4):251–4.
29. Patricio Cordeiro TT, Rocha EAB, Scattone Silva R. Effects of exercise-based interventions on gluteal tendinopathy. Systematic review with meta-analysis. *Sci Rep*. 2024;14(1):3343.
30. Reid D. The management of greater trochanteric pain syndrome: A systematic literature review. *J Orthop*. 2016;13(1):15–28.
31. Cook JL, Purdam CR. Is tendon pathology a continuum? A pathology model to explain the clinical presentation of load-induced tendinopathy. *Br J Sports Med*. 2009;43(6):409–16.
32. Scott A, Cook JL, Hart DA, Walker DC, Duronio V, Khan KM. Tenocyte responses to mechanical loading in vivo: A role for local insulin-like growth factor 1 signaling in early tendinosis in rats. *Arthritis Rheum*. 2007;56(3):871–81.
33. Almekinders LC, Weinhold PS, Maffulli N. Compression etiology in tendinopathy. *Clin Sports Med*. 2003;22(4):703–10.
34. Orchard J, Cook J, Halpin N. Stress-shielding as a cause of insertional tendinopathy: the operative technique of limited adductor tenotomy supports this theory. *J Sci Med Sport*. 2004;7(4):424–8.
35. Cook JL, Purdam C. Is compressive load a factor in the development of tendinopathy? *Br J Sports Med*. 2012;46(3):163–8.
36. Grimaldi A, Fearon A. Gluteal Tendinopathy: Integrating Pathomechanics and Clinical Features in Its Management. *J Orthop Sports Phys Ther*. 2015;45(11):910–22.
37. Soslowsky LJ, Thomopoulos S, Esmail A, et al. Rotator Cuff Tendinosis in an Animal Model: Role of Extrinsic and Overuse Factors. *Ann Biomed Eng*. 2002;30(8):1057–63.
38. Grimaldi A, Mellor R, Hodges P, Bennell K, Wajswelner H, Vicenzino B. Gluteal Tendinopathy: A Review of Mechanisms, Assessment and Management. *Sports Med*. 2015;45(8):1107–19.
39. Fearon AM, Cook JL, Scarvell JM, Neeman T, Cormick W, Smith PN. Greater trochanteric pain syndrome negatively affects work, physical activity and quality of life: a case control study. *J Arthroplasty*. 2014;29(2):383–6.
40. Brinks A, van Rijn RM, Willemsen SP, et al. Corticosteroid injections for greater trochanteric pain syndrome: a randomized controlled trial in primary care. *Ann Fam Med*. 2011;9(3):226–34.
41. Docking SI, Cook J, Chen S, et al. Identification and differentiation of gluteus medius tendon pathology using ultrasound and magnetic resonance imaging. *Musculoskelet Sci Pract*. 2019;41:1–5.
42. Westacott DJ, Minns JI, Foguet P. The diagnostic accuracy of magnetic resonance imaging and ultrasonography in gluteal tendon tears--a systematic review. *Hip Int J Clin Exp Res Hip Pathol Ther*. 2011;21(6):637–45.
43. Lachiewicz PF. Abductor tendon tears of the hip: evaluation and management. *J Am Acad Orthop Surg*. 2011;19(7):385–91.
44. Woodley SJ, Nicholson HD, Livingstone V, et al. Lateral hip pain: findings from magnetic resonance imaging and clinical examination. *J Orthop Sports Phys Ther*. 2008;38(6):313–28.
45. Mellor R, Bennell K, Grimaldi A, et al. Education plus exercise versus corticosteroid injection use versus a wait and see approach on global outcome and pain from gluteal tendinopathy: prospective, single blinded, randomised clinical trial. *BMJ*. 2018;361:k1662.
46. Cook JL, Purdam C. Is compressive load a factor in the development of tendinopathy? *Br J Sports Med*. 2012;46(3):163–8.
47. Bicket L, Cooke J, Knott I, Fearon A. The natural history of greater trochanteric pain syndrome: an 11-year follow-up study. *BMC Musculoskelet Disord*. 2021;22(1):1048.

48. Wilson R, Abbott JH, Mellor R, Grimaldi A, Bennell K, Vicenzino B. Education plus exercise for persistent gluteal tendinopathy improves quality of life and is cost-effective compared with corticosteroid injection and wait and see: economic evaluation of a randomised trial. *J Physiother*. 2023;69(1):35–41.
49. Carlisi E, Cecini M, Di Natali G, Manzoni F, Tinelli C, Lisi C. Focused extracorporeal shock wave therapy for greater trochanteric pain syndrome with gluteal tendinopathy: a randomized controlled trial. *Clin Rehabil*. 2019;33(4):670–80.
50. Seo KH, Lee JY, Yoon K, et al. Long-term outcome of low-energy extracorporeal shockwave therapy on gluteal tendinopathy documented by magnetic resonance imaging. *PloS One*. 2018;13(7):e0197460.
51. Notarnicola A, Ladisa I, Lanzilotta P, et al. Shock Waves and Therapeutic Exercise in Greater Trochanteric Pain Syndrome: A Prospective Randomized Clinical Trial with Cross-Over. *J Pers Med*. 2023;13(6):976.
52. Furia JP, Rompe JD, Maffulli N. Low-energy extracorporeal shock wave therapy as a treatment for greater trochanteric pain syndrome. *Am J Sports Med*. 2009;37(9):1806–13.
53. Chang KV, Wu WT, Özçakar L. Second-Order Peer Reviews of Clinically Relevant Articles for the Physiatrist: Is Platelet-Rich Plasma Injection More Effective Than Corticosteroid for Treatment of Gluteal Tendinopathy? *Am J Phys Med Rehabil*. 2020;99(7):660–2.
54. Vicenzino B. The Effectiveness of Platelet-Rich Plasma Injections in Gluteal Tendinopathy: Letter to the Editor. *Am J Sports Med*. 2018;46(8):NP32–3.
55. Collée G, Dijkmans BA, Vandenbroucke JP, Cats A. Greater trochanteric pain syndrome (trochanteric bursitis) in low back pain. *Scand J Rheumatol*. 1991;20(4):262–6.
56. Fearon AM, Scarvell JM, Neeman T, Cook JL, Cormick W, Smith PN. Greater trochanteric pain syndrome: defining the clinical syndrome. *Br J Sports Med*. 2013;47(10):649–53.
57. Buckland AJ, Miyamoto R, Patel RD, Slover J, Razi AE. Differentiating Hip Pathology From Lumbar Spine Pathology: Key Points of Evaluation and Management. *J Am Acad Orthop Surg*. 2017;25(2):e23–34.
58. Lequesne M. From periarthritis to hip rotator cuff tears. Trochanteric tendinobursitis. *Joint Bone Spine*. 2006;73(4):344–8.
59. Strauss EJ, Nho SJ, Kelly BT. Greater trochanteric pain syndrome. *Sports Med Arthrosc Rev*. 2010;18(2):113–9.
60. Bird PA, Oakley SP, Shnier R, Kirkham BW. Prospective evaluation of magnetic resonance imaging and physical examination findings in patients with greater trochanteric pain syndrome. *Arthritis Rheum*. 2001;44(9):2138–45.
61. Lequesne M, Mathieu P, Vuillemin-Bodaghi V, Bard H, Djian P. Gluteal tendinopathy in refractory greater trochanter pain syndrome: diagnostic value of two clinical tests. *Arthritis Rheum*. 2008;59(2):241–6.
62. Gordon EJ. Trochanteric bursitis and tendinitis. *Clin Orthop*. 1961;20:193–202.
63. Rompe JD, Segal NA, Cacchio A, Furia JP, Morral A, Maffulli N. Home training, local corticosteroid injection, or radial shock wave therapy for greater trochanter pain syndrome. *Am J Sports Med*. 2009;37(10):1981–90.
64. Reiman MP, Goode AP, Hegedus EJ, Cook CE, Wright AA. Diagnostic accuracy of clinical tests of the hip: a systematic review with meta-analysis. *Br J Sports Med*. 2013;47(14):893–902.
65. Jensen MC, Brant-Zawadzki MN, Obuchowski N, Modic MT, Malkasian D, Ross JS. Magnetic resonance imaging of the lumbar spine in people without back pain. *N Engl J Med*. 1994;331(2):69–73.
66. Docking SI, Daffy J, van Schie HTM, Cook JL. Tendon structure changes after maximal exercise in the Thoroughbred horse: use of ultrasound tissue characterisation to detect in vivo tendon response. *Vet J Lond Engl*. 2012;194(3):338–42.
67. Fearon AM, Scarvell JM, Cook JL, Smith PN. Does ultrasound correlate with surgical or histologic findings in greater trochanteric pain syndrome? A pilot study. *Clin Orthop*. 2010;468(7):1838–44.
68. Cvitanic O, Henzie G, Skezas N, Lyons J, Minter J. MRI diagnosis of tears of the hip abductor tendons (gluteus medius and gluteus minimus). *AJR Am J Roentgenol*. 2004;182(1):137–43.
69. Kong A, Van der Vliet A, Zadow S. MRI and US of gluteal tendinopathy in greater trochanteric pain syndrome. *Eur Radiol*. 2007;17(7):1772–83.
70. Del Buono A, Papalia R, Khanduja V, Denaro V, Maffulli N. Management of the greater trochanteric pain syndrome: a systematic review. *Br Med Bull*. 2012;102:115–31.

71. Everhart JS, Cole D, Sojka JH, et al. Treatment Options for Patellar Tendinopathy: A Systematic Review. *Arthrosc J Arthrosc Relat Surg Off Publ Arthrosc Assoc N Am Int Arthrosc Assoc*. 2017;33(4):861–72.
72. Cullinane FL, Boocock MG, Trevelyan FC. Is eccentric exercise an effective treatment for lateral epicondylitis? A systematic review. *Clin Rehabil*. 2014;28(1):3–19.
73. Murphy M, Travers M, Gibson W, et al. Rate of Improvement of Pain and Function in Mid-Portion Achilles Tendinopathy with Loading Protocols: A Systematic Review and Longitudinal Meta-Analysis. *Sports Med Auckl NZ*. 2018;48(8):1875–91.
74. Wilson F, Walshe M, O'Dwyer T, Bennett K, Mockler D, Bleakley C. Exercise, orthoses and splinting for treating Achilles tendinopathy: a systematic review with meta-analysis. *Br J Sports Med*. 2018;52(24):1564–74.
75. Bhabra G, Wang A, Ebert JR, Edwards P, Zheng M, Zheng MH. Lateral Elbow Tendinopathy. *Orthop J Sports Med*. 2016;4(11):2325967116670635.
76. Ladurner A, Fitzpatrick J, O'Donnell JM. Treatment of Gluteal Tendinopathy: A Systematic Review and Stage-Adjusted Treatment Recommendation. *Orthop J Sports Med* [Internet]. 2021;9(7).
77. Labrosse JM, Cardinal É, Leduc BE, et al. Effectiveness of Ultrasound-Guided Corticosteroid Injection for the Treatment of Gluteus Medius Tendinopathy. *Am J Roentgenol*. 2010;194(1):202–6.
78. Sayegh F, Potoupnis M, Kapetanos G. Greater trochanter bursitis pain syndrome in females with chronic low back pain and sciatica. *Acta Orthop Belg*. 2004;70(5):423–8.
79. Stephens MB, Beutler AI, O'Connor FG. Musculoskeletal injections: a review of the evidence. *Am Fam Physician*. 2008;78(8):971–6.
80. Cohen SP, Strassels SA, Foster L, et al. Comparison of fluoroscopically guided and blind corticosteroid injections for greater trochanteric pain syndrome: multicentre randomised controlled trial. *BMJ*. 2009;338:b1088.
81. Nuelle CW, Cook CR, Stoker AM, Cook JL, Sherman SL. *In vitro* toxicity of local anaesthetics and corticosteroids on supraspinatus tenocyte viability and metabolism. *J Orthop Transl*. 2017;8:20–4.
82. Puzzitiello RN, Patel BH, Forlenza EM, et al. Adverse Impact of Corticosteroids on Rotator Cuff Tendon Health and Repair: A Systematic Review of Basic Science Studies. *Arthrosc Sports Med Rehabil*. 2020;2(2):e161–9.
83. Fitzpatrick J, Bulsara MK, O'Donnell J, McCrory PR, Zheng MH. The Effectiveness of Platelet-Rich Plasma Injections in Gluteal Tendinopathy: A Randomized, Double-Blind Controlled Trial Comparing a Single Platelet-Rich Plasma Injection With a Single Corticosteroid Injection. *Am J Sports Med*. 2018;46(4):933–9.
84. Fitzpatrick J, Bulsara MK, O'Donnell J, Zheng MH. Leucocyte-Rich Platelet-Rich Plasma Treatment of Gluteus Medius and Minimus Tendinopathy: A Double-Blind Randomized Controlled Trial With 2-Year Follow-up. *Am J Sports Med*. 2019;47(5):1130–7.
85. Lee JJ, Harrison JR, Boachie-Adjei K, Vargas E, Moley PJ. Platelet-Rich Plasma Injections With Needle Tenotomy for Gluteus Medius Tendinopathy: A Registry Study With Prospective Follow-up. *Orthop J Sports Med*. 2016;4(11):2325967116671692.
86. Jacobson JA, Yablon CM, Henning PT, et al. Greater Trochanteric Pain Syndrome: Percutaneous Tendon Fenestration Versus Platelet-Rich Plasma Injection for Treatment of Gluteal Tendinosis. *J Ultrasound Med Off J Am Inst Ultrasound Med*. 2016;35(11):2413–20.
87. Jacobson JA, Rubin J, Yablon CM, Kim SM, Kalume-Brigido M, Parameswaran A. Ultrasound-Guided Fenestration of Tendons About the Hip and Pelvis: Clinical Outcomes. *J Ultrasound Med Off J Am Inst Ultrasound Med*. 2015;34(11):2029–35.
88. Bucher TA, Ebert JR, Smith A, et al. Autologous Tenocyte Injection for the Treatment of Chronic Recalcitrant Gluteal Tendinopathy: A Prospective Pilot Study. *Orthop J Sports Med*. 2017;5(2):2325967116688866.
89. Domb BG, Botser I, Giordano BD. Outcomes of endoscopic gluteus medius repair with minimum 2-year follow-up. *Am J Sports Med*. 2013;41(5):988–97.
90. Voos JE, Shindle MK, Pruett A, Asnis PD, Kelly BT. Endoscopic repair of gluteus medius tendon tears of the hip. *Am J Sports Med*. 2009;37(4):743–7.
91. Walsh MJ, Walton JR, Walsh NA. Surgical repair of the gluteal tendons: a report of 72 cases. *J Arthroplasty*. 2011;26(8):1514–9.
92. Thaunat M, Clowez G, Desseaux A, et al. Influence of Muscle Fatty Degeneration on Functional Outcomes After Endoscopic Gluteus Medius Repair. *Arthrosc J Arthrosc Relat Surg Off Publ Arthrosc Assoc N Am Int Arthrosc Assoc*. 2018;34(6):1816–24.

93. Hartigan DE, Perets I, Ho SW, Walsh JP, Yuen LC, Domb BG. Endoscopic Repair of Partial-Thickness Undersurface Tears of the Abductor Tendon: Clinical Outcomes With Minimum 2-Year Follow-up. *Arthrosc J Arthrosc Relat Surg Off Publ Arthrosc Assoc N Am Int Arthrosc Assoc*. 2018;34(4):1193–9.
94. Makridis KG, Lequesne M, Bard H, Djian P. Clinical and MRI results in 67 patients operated for gluteus medius and minimus tendon tears with a median follow-up of 4.6 years. *Orthop Traumatol Surg Res OTSR*. 2014;100(8):849–53.
95. Davies JF, Stiehl JB, Davies JA, Geiger PB. Surgical treatment of hip abductor tendon tears. *J Bone Joint Surg Am*. 2013;95(15):1420–5.
96. Ebert JR, Bucher TA, Mullan CJ, Janes GC. Clinical and functional outcomes after augmented hip abductor tendon repair. *Hip Int J Clin Exp Res Hip Pathol Ther*. 2018;28(1):74–83.
97. Bucher TA, Darcy P, Ebert JR, Smith A, Janes G. Gluteal tendon repair augmented with a synthetic ligament: surgical technique and a case series. *Hip Int J Clin Exp Res Hip Pathol Ther*. 2014;24(2):187–93.
98. Huxtable RE, Ackland TR, Janes GC, Ebert JR. Clinical outcomes and frontal plane two-dimensional biomechanics during the 30-second single leg stance test in patients before and after hip abductor tendon reconstructive surgery. *Clin Biomech Bristol Avon*. 2017;46:57–63.

European Journal of Musculoskeletal Diseases
ISSN 2038-4106 print - ISSN 2975-044X online

Review

COMPREHENSIVE REVIEW OF PES ANSERINUS SYNDROME: ETIOLOGY, DIAGNOSIS, AND MANAGEMENT

R. Aicale[1], R. Pellegrino[2,3*], D.I. Angelo[4], R. Mottola[5], R. Saggini[6], C. Ruosi[5] and D. Tarantino[7]

[1] Department of Orthopaedic and Trauma Surgery, Casa di Cura di Bernardini, Taranto, Italy;
[2] Department of Medicine, LUM University, Italy;
[3] Santa Chiara Institute, Lecce, Italy;
[4] Department of Innovative Technologies in Medicine & Dentistry, University "G. d'Annunzio" of Chieti-Pescara, Italy;
[5] Department of Public Health, University of Naples Federico II, Naples, Italy;
[6] Faculty of Psychology, eCampus University, Novedrate, Italy;
[7] Department of Orthopaedic Rehabilitation, Campolongo Hospital, 84025 Marina di Eboli, Salerno, Italy.

**Correspondence to*:
Raffaello Pellegrino, MD,
Department of Medicine,
LUM University, Italy.
e-mail: r.pellegrino@lum.it

ABSTRACT

Pes anserinus is an anatomical structure located on the medial aspect of the knee, where the tendons of the sartorius, gracilis, and semitendinosus muscles conjoin and insert onto the anteromedial surface of the proximal tibia, approximately 5 cm distally to the medial knee joint space. Pathological conditions associated with pes anserinus, most notably pes anserinus bursitis, are common sources of medial knee pain, particularly among athletes, individuals with osteoarthritis (OA), and obese patients. Since this peculiar structure is made by the insertion of three tendons, a true difference between bursitis and tendinopathy is hard to identify in the context of pes anserinus. Diagnosis of pes anserinus syndrome (PAS) is primarily clinical, supported by imaging techniques like ultrasound or magnetic resonance imaging to rule out other causes of medial knee pain. Treatment often involves conservative measures such as rest, cryotherapy, nonsteroidal anti-inflammatory drugs (NSAIDs), physical therapy, and injections. In refractory cases, surgical intervention may be considered. Understanding the anatomy and pathology of pes anserinus is essential for clinicians to accurately diagnose and manage conditions affecting this structure. Comprehensive knowledge of its clinical implications can lead to more effective treatment strategies and improved patient outcomes. This article provides a concise overview of the anatomical features, common pathologies, diagnostic approaches, and treatment modalities related to PAS, highlighting its significance in musculoskeletal health and disease.

KEYWORDS: *tendinopathy, pes anserinus, pes anserine; pes anserinus syndrome; anserine syndrome; pes anserinus tendinopathy; pes anserinus bursitis*

INTRODUCTION

Sartorius, gracilis and semitendinous tendons insertion forms a peculiar anatomical structure that refers to the natatory goose membrane, and is named commonly from latin, *pes anserinus* (PA), also known as the "goose's foot"(1,2). Tendons

Received: 20 September, 2024
Accepted: 18 December, 2024

ISSN 2038-4106 print
ISSN 2975-044X online Copyright © by BIOLIFE 2024
This publication and/or article is for individual use only and may not be further reproduced without written permission from the copyright holder. Unauthorized reproduction may result in financial and other penalties. Disclosure: All authors report no conflicts of interest relevant to this article.

of these muscles, originating from different parts of the pelvis and femur, extend into the crural fascia and attach approximately 5 cm distally to the knee joint space medial portion (3,4) (Fig.1).

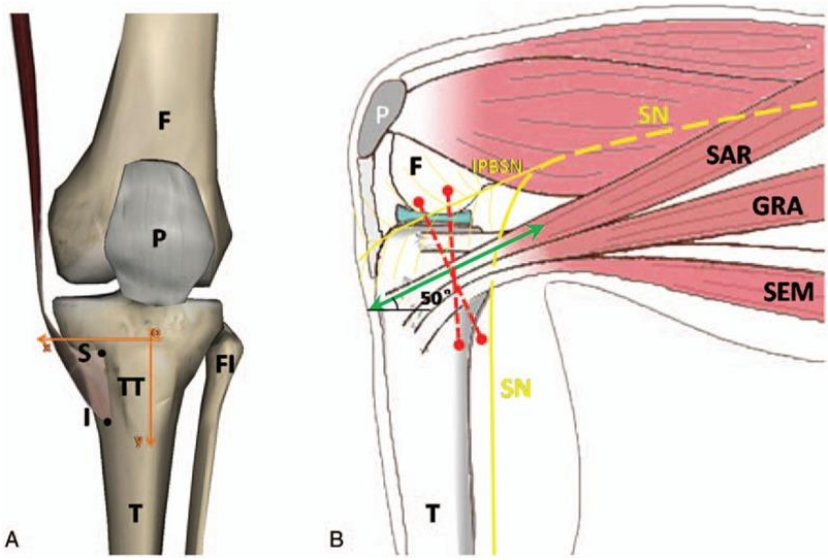

Fig. 1. *PA tendons and their insertion. Retrieved from: Zhong S, Wu B, Wang M, Wang X, Yan Q, Fan X, Hu Y, Han Y, Li Y. The anatomical and imaging study of pes anserinus and its clinical application. Medicine (Baltimore). 2018 Apr;97(15):e0352.*

The configuration resembles a goose's foot, giving the structure its distinctive name. These tendons and their muscles are knee flexors with a secondary action on the tibia internal rotation, protecting against rotation and valgus stress (5). Furthermore, PA is essential for various physical activities, from walking and running to complex athletic maneuvers. The integrity and functionality of the PA are paramount for maintaining knee health and preventing injury.

Pathological conditions affecting the PA, most notably pes anserinus bursitis (PAB), are common sources of medial knee pain. PAB involves inflammation of the bursa located between the PA tendons and the medial collateral ligament (6).

The first report mentioning this disease came from Moschcowitz in 1937, which reported knee pain almost exclusively in women (7).

The term “tendinopathy” instead includes all the situations in which there are chronic clinical conditions characterized by pain, swelling and functional limitations of tendons and nearby structures (8–12). Both intrinsic and extrinsic factors play a key role in the pathogenesis of tendinopathy; age, gender and gender are the most prominent non-modifiable factors, while excessive and/or improper loading, disuse, drugs and smoking habit are the most influent modifiable factors (8,9,13–17). Although the term "tendinitis" is often associated with the concept of tendinopathy, in recent years it has been shown that the inflammatory process only affects the initial stages of the disease, while degenerative and apoptotic phenomena prevail afterwards because of long-lasting overuse condition related to work and/or sports (10,18–23). Tendinopathy can be viewed as a failure of the cell matrix to adapt to a variety of stresses as a result of an imbalance between matrix degeneration and synthesis (19,24–28).

A true distinction between PAB and PA tendinopathy (PAT) is hard and the management proposed by the studies in the current literature is the same for both conditions. Moreover, the exact structures responsible of the symptoms related to pain in PA area is still under debate, and several articles report doubts regarding the validity of the identification of the PA disease as an inflammatory or degenerative condition of the bursa and/or tendon (29). For this reason, the term “pes anserinus syndrome” (PAS), instead of only PAB or PAT, seems to be more appropriate.

PAS seems to be more common in overweight females with knee OA who have a wider pelvis, resulting in greater knee angulation, which leads to more pressure in the insertion area of the PA (3,5,29,30). However, this condition is also frequent in athletes (such as long-distance runners) and in the elderly (31,32).

Pain in the PA area is usually the main symptom which can significantly impair daily activities and athletic performance. The diagnosis of PAS is mainly based on physical examination, looking for tenderness over the PA insertion site, or performing tests such as the pes anserinus stress test, which involves resisting knee flexion while the leg is externally rotated, to reproduce pain.

US can provide clinically useful information in the differentiation between intraarticular versus periarticular or extraarticular disorders and should be used as a first-line imaging modality as it may reveal bursal swelling, fluid accumulation, and thickening of the PA tendons (33,34) (Fig.2).

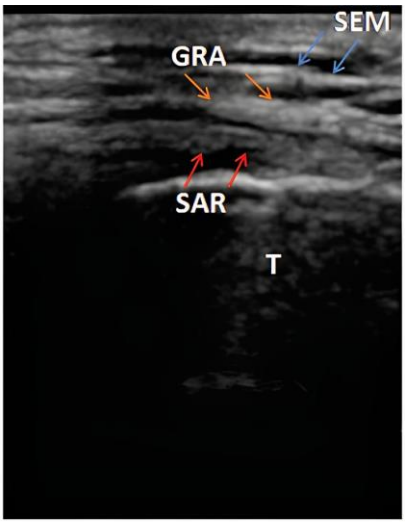

Fig. 2. *PA tendons revealed at the US examination. Retrieved from: Zhong S, Wu B, Wang M, Wang X, Yan Q, Fan X, Hu Y, Han Y, Li Y. The anatomical and imaging study of pes anserinus and its clinical application. Medicine (Baltimore). 2018 Apr;97(15):e0352.*

Authors suggest that structural changes, i.e. meniscal lesions commonly in OA, may play a role in pain generation in the medial aspect of the knee (33), so it is important to differentiate from other pathology that may mimic PAS through an accurate differential diagnosis.

Given the paucity of comprehensive information on PAS, the aim of the present review is to report the actual evidence on this pathology especially regarding risk factors, diagnosis, and treatment, highlighting the limits in the understanding on the underlying process and the involved structures.

METHODS

A comprehensive search of scientific databases, including PubMed, Scopus, and Web of Science, was performed by two independent authors (R.A. and D.T.) to collect relevant articles on the topic. All kinds of articles in English language were included, with no limitation of time. Two independent reviewers (R.P. and R.M.) extracted and evaluated the data. The included articles reported on the risk factors, diagnosis and treatment of PAS. The authors also evaluated the reference lists of the included articles but eventually found no extra articles to be included.

Specific keywords including “pes anserinus”, “pes anserine”, “pes anserinus AND bursitis”, and “pes anserinus AND tendinopathy”, “pes anserinus AND tendinitis” were used during the search. To facilitate the understanding of the results, we categorized the results into the following sections: risk factors, clinical presentation and diagnosis, conservative and surgical treatment.

DISCUSSION

Risk factors

Recently, various studies have examined the mechanical and metabolic factors that may influence the development of PAS, such as valgus knee deformity, alone or in combination with knee collateral instability. The aetiology is not well understood and may include trauma, posterior thigh muscle retraction, bone exostosis, suprapatellar plica irritation, medial meniscus injury, pes planus, genu valgum, and infection (35,36).

Metabolic and degenerative conditions such as diabetes mellitus (DM), obesity, and knee OA, classically described as risk factors for PAS in uncontrolled reports (37), do not seem to be significantly associated with it (38–40). In other cross-sectional studies, type-II DM was strongly associated with PAS compared with a non-diabetic population (37,41).

Biomechanical alterations of the lower limbs (i.e., knee deformity, instability, collateral instability, and hindfoot malalignment) were also not found to be associated with PAS development (40).

Medial knee pain has been studied in search of a correlation with PAS, but different articles have failed in this scope, finding no correlation between PA bursa swelling, as observed via magnetic resonance imaging (MRI), and the presence of medial knee pain (42). Similar results were found using US imaging, showing no correlation between any PA bursa or PA tendon degeneration and clinically defined PAS (41,43).

More recently, the medial knee collateral complex, particularly its superficial layer, has been investigated for its close anatomical relationship with the PA complex, as a structural element that may play an important role in the clinical presentation of PAS (44).

The medial collateral complex is significantly stressed during valgus loading of the knee, for example in mature women, in whom a valgus knee deformity, alone or in combination with knee collateral instability, has been identified as a risk factor for PAS development (40,45).

Clinical presentation and diagnosis

The clinical presentation of PAS is commonly characterized by pain in the medial aspect of the knee and edema at the anatomical site of PA insertion, which may be exacerbated by going up or down stairs. Despite this, several patients report posteromedial or medial knee pain without edema. The first criteria for diagnosing PAS were proposed in 1985: pain in the anteromedial region of the knee (particularly when going up or down stairs), morning pain and rigidity, pain at rest during the night, difficulty in rising from a chair or getting out of a car, frequently associated with local edema (46).

Diagnosis is primarily clinical and confirmed by imaging exams. Generally, pain is located in the proximal medial region of the knee, approximately 5 cm below the medial joint line, more frequently in overweight individuals with signs of degenerative joint disease and OA. Radiographs of the knee are normal in most patients, occasionally showing bony exostosis or signs of OA in the medial compartment. Although clinical evaluation seems straightforward, diagnosis using imaging tools such as US or MRI can be used as an adjunct (47) (Fig.3,4).

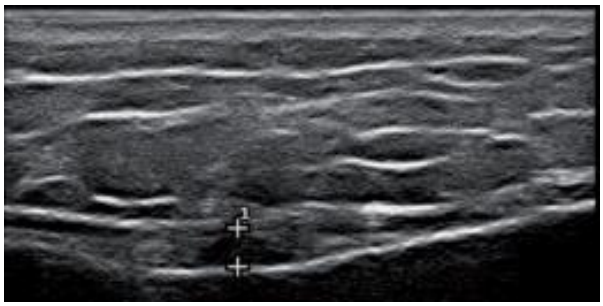

Fig. 3. *PAB with fluid accumulation as showed by the marked hypoechoic area. Retrived from: Toktas H, Dundar U, Adar S, Solak O, Ulasli AM. Ultrasonographic assessment of pes anserinus tendon and pes anserinus tendinitis bursitis syndrome in patients with knee osteoarthritis. Mod Rheumatol. 2015 Jan;25(1):128-33.*

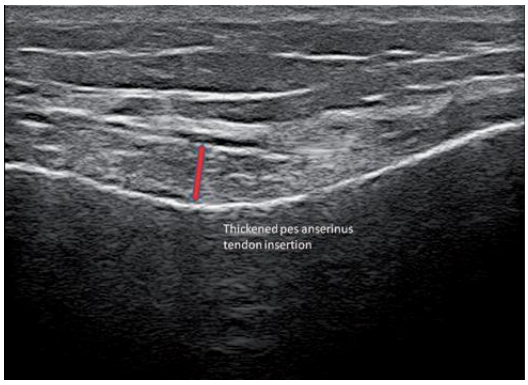

Fig. 4. *PAT: The PA tendon insertion is thickened. Retrived from: Toktas H, Dundar U, Adar S, Solak O, Ulasli AM. Ultrasonographic assessment of pes anserinus tendon and pes anserinus tendinitis bursitis syndrome in patients with knee osteoarthritis. Mod Rheumatol. 2015 Jan;25(1):128-33.*

A relatively recent study (43) evaluated 37 female patients using US analysis with a clinical diagnosis of PAS (bursitis or tendinopathy), considering the thickness of PA insertion, intratendinous morphological characteristics, the presence of a bursa greater than 2 mm, and changes in the subcutaneous fat of the medial aspect of the knee. Only one patient had PAT on imaging. Bursitis was found in one asymptomatic knee, one symptomatic unilateral knee, and one with bilateral pain. The authors concluded that most patients diagnosed with PAB or PAT did not present morphological changes on US, and that the pain etiology may result from an interaction between structural changes secondary to OA and/or altered peripheral and central pain processing mechanisms.

In another study, the prevalence of 4 out of 48 patients with type-II DM showed evidence of PAT on US imaging, suspected after clinical evaluation. The authors highlighted that none of these patients had bursal inflammation (41).

The use of US to detect PA syndrome was recently investigated in a sample of 314 knees with OA (47), classified according to the Kellgren and Lawrence (K-L) scale. The study evaluated the thickness of PA tendon insertion, intratendinous tissue characteristics, and pes anserinus bursitis. The researchers found that the mean thickness of the PA

in knees with OA, both with and without PAS, was significantly greater compared to controls. For K-L grades 3 and 4, the mean thickness was greater compared to knees with OA graded K-L 1 and 2, independent of the presence of PAS. Fibrillar echotexture was altered in all cases, but these modifications were more evident in knees with OA and PAS compared to those without it, which also presented a relatively lower VAS score.

The reported discrepancy between clinical and radiological results may be explained by three mechanisms: (1) US imaging may not be adequate for asserting the presence of PAT and/or bursitis, with MRI potentially being a better alternative; (2) the pain-generating tissue may be deeper or not well visualized by US; (3) the pain point on the medial aspect of the knee may be a tender point with an atypical pain threshold (1).

Based on the reported evidence, there is no doubt that US can be useful in evaluating soft tissues, tendon structure changes, and small quantities of fluid (48). However, the terms “tendinopathy” or “bursitis” may not be used correctly, and caution must be exercised when using the expression “PA tendino-bursitis” (43).

Regarding the use of MRI, different studies support its use, although the results are not very promising. One study found a prevalence of only 2.5% (13 knees) of PAB in about 488 patients (49). The authors emphasized the importance of the axial view to differentiate the bursa from other medial fluid collections. Similar results were shown in another study, where the presence of effusion in the PA bursa was reported in 3.7% of 451 symptomatic patients. Although 59 patients demonstrated changes in imaging, no correlation between clinical symptoms and imaging was found. Therefore, the authors concluded that clinical findings of PAB or PAT rarely show changes on MRI (42). Another article investigated the use of computed tomography (CT) and concluded that distension of the PA bursa is not synonymous with bursitis if patients do not have any symptoms, and that the syndrome could be due to tendinopathy or fasciitis affecting the PA insertion (50).

For differential diagnosis, many conditions need to be considered, such as medial meniscus tears, OA of the knee's medial compartment, L3-L4 radiculopathy, and medial collateral ligament complex injuries. Pain located inferomedial to the medial joint line in PAS differs from that in OA or meniscus tears. Moreover, clinical tests help diagnose lesions of various structures. In the case of L3-L4 radiculopathy, knee pain is associated with lumbar pain. Pathological cysts and other soft tissue masses that may mimic cysts can result in symptom overlapping with PAS. Bursae inflammation should always be included in the differential diagnosis, particularly suprapatellar bursitis and pre-patellar bursitis, which are better visualized in the sagittal MRI view.

Furthermore, cases of PAB induced by polyethylene after knee arthroplasty have been reported, with an incidence of 5.6% (51). This condition was initially considered an infectious complication after surgery, but it is now regarded as an inflammatory consequence in patients who receive joint replacements (35).

Other conditions that may be considered include muscle pain, patellofemoral syndrome, patellar chondromalacia, recurring patellar subluxation, Osgood-Schlatter disease, osteochondritis dissecans, patellar tendinopathy, synovial plica, lesion of the infra-patellar fat pad, patellar dysplasia, patellar fracture, para-articular chondroma or osteochondroma, synovitis and synovial haemangioma, and fibromyalgia syndrome (1,52–54).

Conservative and surgical treatment

Conservative management of PAS typically includes rest for the affected knee, cryotherapy for acute cases, rehabilitation, and anti-inflammatory drugs (corticosteroids and/or non-steroidal anti-inflammatory drugs) (31,55,56). For obese patients, weight loss is mandatory, as well as the treatment of associated conditions such as deviated knee, pes planus, and diabetes control. In elderly patients, avoiding muscular atrophy secondary to disuse is a primary goal, and isometric exercises can be used (31).

Recent literature includes case reports of giant bursae or ruptured bursae due to severe OA of the knee (6,57,58), and a condition defined as a “snapping” PA tendon evaluated using dynamic US (59).

Local anesthetic injections associated with corticosteroids (CS), such as 20 to 40 mg of methylprednisolone or triamcinolone in the bursa, no more than three times a year, are safe and effective (60,61).

The injections should be performed under ultrasound guidance to avoid injecting the substance into the PA tendons (Fig.5,6).

Fig. 5. *US-guided injection, the transducer was positioned in a longitudinal orientation relative to the anterior fibers of the medial collateral ligament, with an oblique transverse orientation relative to the PA. Retrieved from: Lee JH, Lee JU, Yoo SW. Accuracy and efficacy of ultrasound-guided pes anserinus bursa injection. J Clin Ultrasound. 2019 Feb;47(2):77-82.*

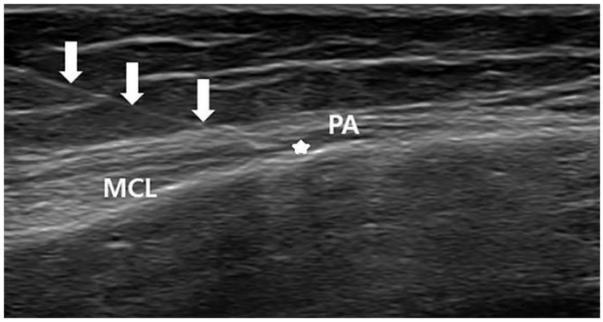

Fig. 6. *US-guided injection, longitudinal ultrasound image of a needle (white arrow) in the PA bursa (asterisk) between the medial collateral ligament (MCL) and the PA tendon. Retrieved from: Lee JH, Lee JU, Yoo SW. Accuracy and efficacy of ultrasound-guided pes anserinus bursa injection. J Clin Ultrasound. 2019 Feb;47(2):77-82.*

The interval between injections should be greater than one month, and if there is no response to treatment, one injection into the knee joint can be beneficial in refractory cases (1).

A significant improvement was noted in a cohort study of 44 patients with PAS managed with naproxen every 12 hours or corticosteroid injections. After one month, resolution was reported in 5% of patients in the naproxen group, while in the CS group, resolution was reported in 30% of patients (62).

In another study, clinical remission was observed in 11 of 12 patients treated with CS injections, compared to 7 of 17 who did not receive any injections; however, these patients were affected by clinical PAS and OA of the knee (39).

Yoon and Kim (38) reported good results in 17 out of 26 patients with knee OA and PAS, confirmed by US, treated with injections of triamcinolone acetonide. Only two patients (8.7%) demonstrated US evidence of PAS. All scores improved significantly after the injections, concluding that only the two patients who reported excellent outcomes had US evidence of PAS.

A proper rehabilitation program should be characterized by stretching and strengthening exercises for the adductors and quadriceps, especially focusing on the last 30° of knee extension using the vastus medialis muscle. This includes stretching the tendons that comprise the PA. Stretching promotes a reduction in tension in the PA tendon complex, particularly in cases secondary to restricted flexibility and muscle and/or tendon retraction.

A recent article reported the effects on 27 patients treated with kinesiotaping compared to 19 patients managed with naproxen and physical therapy. The study, which used US diagnosis of PAS, found a significant decrease in pain and swelling in the kinesiotaping group compared to the naproxen/physical therapy group, with only one case of mild local skin irritation in the kinesiotaping group (56).

In recent years, new technologies have been developed to treat tendon and muscle conditions (63), such as injections of platelet-rich plasma (PRP), which have shown overall good results (21,64). PRP injections used for PAS are safe and effective, demonstrating excellent results in pain reduction (evaluated using the VAS scale) at 6 months follow-up (55). More recently, a randomized controlled trial compared single versus double injections of PRP, reporting no difference in terms of VAS score, Western Ontario and McMaster Universities Osteoarthritis Index (WOMAC), 6-minute walking test (6MWT), and Likert Scale at one- and three-months follow-up. However, intra-group evaluation showed significant improvement. (65).

In cases of failure of conservative management (rehabilitation and injections), surgery can be indicated, although there is no clear evidence regarding the optimal timing for changing management modalities. Typically, an open procedure is preferred, with simple incisions followed by drainage of the distended bursa providing symptom improvement (46,60,66,67). This approach is recommended when there is a definitive diagnosis made clinically and using imaging. If necessary, due to the large size of the lesion or in the case of bone exostosis, the bursa can be removed (35).

CONCLUSIONS

In conclusion, PAS represents a significant source of discomfort and functional limitation for individuals, particularly those engaged in activities involving repetitive knee flexion. The actual structures located in the PA responsible for the symptoms related to PAS are still under debate, as well as its risk factors.

Effective management of this condition involves a multifaceted approach encompassing rest, activity modification, physical therapy, and possibly adjunctive interventions such as bursal injections.

Understanding contributing factors such as metabolic disorders, biomechanical abnormalities or overuse is crucial for targeted treatment and prevention of recurrence.

While PAS can pose challenges, timely intervention and adherence to a comprehensive rehabilitation plan can yield favorable outcomes, facilitating a return to pain-free movement and improved quality of life. Ongoing research and clinical advancements continue to refine our understanding and treatment strategies for this condition, underscoring the importance of a collaborative and individualized approach in optimizing patient care.

Conflict of interest

The authors declare that they have no conflict of interest.

REFERENCES

1. Helfenstein M, Kuromoto J. Anserine syndrome. *Revista Brasilera de Reumatologia*. 2010;50(3):313-327.
2. Curtis BR, Huang BK, Pathria MN, et al. Pes Anserinus: Anatomy and Pathology of Native and Harvested Tendons. *American Journal of Roentgenology*. 2019;213(5):1107-1116. doi:10.2214/AJR.19.21315
3. Handy JR. Anserine bursitis: a brief review. *Southern Medical Journal*. 1997;90(4):376-377. doi:10.1097/00007611-199704000-00002
4. Olewnik Ł, Gonera B, Podgórski M, et al. A proposal for a new classification of pes anserinus morphology. *Knee Surgery, Sports Traumatology, Arthroscopy*. 2019;27(9):2984-2993. doi:10.1007/s00167-018-5318-3
5. Alvarez-Nemegyei J, Canoso JJ. Evidence-Based Soft Tissue Rheumatology IV: Anserine Bursitis. *Journal Of Clinical Rheumatology: Practical Reports On Rheumatic & Musculoskeletal Diseases*. 2004;10(4):205-206. doi:10.1097/01.rhu.0000135561.41660.b0
6. Allen MF, Allen DE. Pes Anserinus Bursitis: A Case Report. *Cureus*. 2022;14(11):e31354. doi:10.7759/cureus.31354
7. Moschcowitz E. Bursitis Of Sartorius Bursa: An Undescribed Malady Simulating Chronic Arthritis. *Journal of the American Medical Association*. 1937;109(17):1362. doi:10.1001/jama.1937.92780430001009
8. Aicale R, Tarantino D, Maffulli N. Basic Science of Tendons. In: Gobbi A, Espregueira-Mendes J, Lane JG, Karahan M, eds. *Bio-Orthopaedics: A New Approach*. Springer; 2017:249-273. doi:10.1007/978-3-662-54181-4_21
9. Loiacono C, Palermi S, Massa B, et al. Tendinopathy: Pathophysiology, Therapeutic Options, and Role of Nutraceutics. A Narrative Literature Review. *Medicina (Mex)*. 2019;55(8):447. doi:10.3390/medicina55080447
10. Aicale R, Tarantino D, Maffulli N. Non-insertional Achilles Tendinopathy: State of the Art. In: Canata GL, d'Hooghe P, Hunt KJ, Kerkhoffs GMMJ, Longo UG, eds. *Sports Injuries of the Foot and Ankle: A Focus on Advanced Surgical Techniques*. Springer; 2019:359-367. doi:10.1007/978-3-662-58704-1_32
11. Tarantino D, Mottola R, Resta G, et al. Achilles Tendinopathy Pathogenesis and Management: A Narrative Review. *International Journal of Environmental Research and Public Health*. 2023;20(17):6681. doi:10.3390/ijerph20176681
12. Tarantino D, Aicale R, Maffulli N. Achilles Tendinopathy. In: *Evidence-Based Orthopedics*. John Wiley & Sons, Ltd; 2021:849-852. doi:10.1002/9781119413936.ch145
13. Bisaccia DR, Aicale R, Tarantino D, et al. Biological and chemical changes in fluoroquinolone-associated tendinopathies: a systematic review. *British Medical Bulletin*. 2019;130(1):39-49. doi:10.1093/bmb/ldz006
14. de Sire A, Lippi L, Mezian K, et al. Ultrasound-guided platelet-rich-plasma injections for reducing sacroiliac joint pain: A paradigmatic case report and literature review. *Journal of Back and Musculoskeletal Rehabilitation*. 2022;35(5):977-982. doi:10.3233/BMR-210310

15. Pellegrino R, Di Iorio A, Filoni S, et al. Radial or Focal Extracorporeal Shock Wave Therapy in Lateral Elbow Tendinopathy: A Real-Life Retrospective Study. *International Journal of Environmental Research and Public Health*. 2023;20(5):4371. doi:10.3390/ijerph20054371
16. Maffulli N, Aicale R, Tarantino D. Tendinopathy of the Achilles Tendon. In: Allegra F, Cortese F, Lijoi F, eds. *Ankle Joint Arthroscopy: A Step-by-Step Guide*. Springer International Publishing; 2020:227-237. doi:10.1007/978-3-030-29231-7_31
17. Tarantino D, Palermi S, Sirico F, et al. Achilles tendon pathologies: How to choose the best treatment. *Journal of Human Sport and Exercise*. 15(4proc), S1300-S1321. doi:https://doi.org/10.14198/jhse.2020.15.Proc4.29
18. Maffulli N, Wong J, Almekinders LC. Types and epidemiology of tendinopathy. *Clinics in Sports Medicine*. 2003;22(4):675-692. doi:10.1016/s0278-5919(03)00004-8
19. Maffulli N, Aicale R, Tarantino D. Autograft Reconstruction for Chronic Achilles Tendon Disorders. *Techniques in Foot & Ankle Surgery*. 2017;16(3):117. doi:10.1097/BTF.0000000000000154
20. Pellegrino R, Brindisino F, Barassi G, et al. Combined ultrasound guided peritendinous hyaluronic acid (500-730 Kda) injection with extracorporeal shock waves therapy vs. extracorporeal shock waves therapy-only in the treatment of shoulder pain due to rotator cuff tendinopathy. A randomized clinical trial. *Journal of Sports Medicine and Physical Fitness*. 2022;62(9):1211-1218. doi:10.23736/S0022-4707.22.13924-1
21. Aicale R, Tarantino D, Maffulli N. Overuse injuries in sport: a comprehensive overview. *Journal of Orthopaedic Surgery*. 2018;13(1):309. doi:10.1186/s13018-018-1017-5
22. Tarantino D, Palermi S, Sirico F, et al. Achilles Tendon Rupture: Mechanisms of Injury, Principles of Rehabilitation and Return to Play. *Journal of Functional Morphology and Kinesiology*. 2020;5(4):95. doi:10.3390/jfmk5040095
23. Demeco A, de Sire A, Marotta N, et al. Effectiveness of Rehabilitation through Kinematic Analysis of Upper Limb Functioning in Wheelchair Basketball Athletes: A Pilot Study. *Applied Sciences*. 2022;12(6):2929. doi:10.3390/app12062929
24. Riley GP, Curry V, DeGroot J, et al. Matrix metalloproteinase activities and their relationship with collagen remodelling in tendon pathology. *Matrix Biology*. 2002;21(2):185-195. doi:10.1016/s0945-053x(01)00196-2
25. Leadbetter WB. Cell-matrix response in tendon injury. *Clinics of Sports Medicine*. 1992;11(3):533-578.
26. Pellegrino R, Paolucci T, Brindisino F, et al. Effectiveness of High-Intensity Laser Therapy Plus Ultrasound-Guided Peritendinous Hyaluronic Acid Compared to Therapeutic Exercise for Patients with Lateral Elbow Tendinopathy. *Journal of Clinical Medicine*. 2022;11(19):5492. doi:10.3390/jcm11195492
27. Aicale R, Tarantino D, Maffulli N. Surgery in Tendinopathies. *Sports Medicine and Arthroscopy Review*. 2018;26(4):200. doi:10.1097/JSA.0000000000000214
28. Tarantino D, Mottola R, Sirico F, et al. Exploring the impact of vitamin D on tendon health: a comprehensive review. *Journal of Basic and Clinical Physiology and Pharmacology*. Published online May 23, 2024. doi:10.1515/jbcpp-2024-0061
29. Gnanadesigan N, Smith RL. Knee pain: osteoarthritis or anserine bursitis? *Journal of the American Medical Directors Association*. 2003;4(3):164-166. doi:10.1097/01.JAM.0000064461.69195.58
30. Saggini R, Anastasi GP, Battilomo S, et al. Consensus paper on postural dysfunction: recommendations for prevention, diagnosis and therapy. *Journal of Biological Regulators and Homeostatic Agents*. 2021;35(2):441-456. doi:10.23812/20-743-A
31. Mohseni M, Mabrouk A, Li DD, et al. Pes Anserine Bursitis. In: *StatPearls*. StatPearls Publishing; 2024. Accessed June 3, 2024. http://www.ncbi.nlm.nih.gov/books/NBK532941/
32. Safran MR, Fu FH. Uncommon causes of knee pain in the athlete. *Orthopedic Clinics of North America*. 1995;26(3):547-559.
33. Valley VT, Shermer CD. Use of musculoskeletal ultrasonography in the diagnosis of pes anserine tendinitis: a case report. *Journal of Emergency Medicine*. 2001;20(1):43-45. doi:10.1016/s0736-4679(00)00282-1
34. Zhong S, Wu B, Wang M, et al. The anatomical and imaging study of pes anserinus and its clinical application. *Medicine (Baltimore)*. 2018;97(15):e0352. doi:10.1097/MD.0000000000010352
35. Huang TW, Wang CJ, Huang SC. Polyethylene-induced pes anserinus bursitis mimicking an infected total knee arthroplasty: a case report and review of the literature. *The Journal of Arthroplasty*. 2003;18(3):383-386. doi:10.1054/arth.2003.50062
36. Tiwari V, Sampath Kumar V, Poudel RR, et al. Pes Anserinus Bursitis due to Tibial Spurs in Children. *Cureus*. 2017;9(7):e1427. doi:10.7759/cureus.1427

37. Cohen SE, Mahul O, Meir R, et al. Anserine bursitis and non-insulin dependent diabetes mellitus. *The Journal of Rheumatology*. 1997;24(11):2162-2165.
38. Yoon HS, Kim SE, Suh YR, et al. Correlation between ultrasonographic findings and the response to corticosteroid injection in pes anserinus tendinobursitis syndrome in knee osteoarthritis patients. *Journal of Korean Medical Science*. 2005;20(1):109-112. doi:10.3346/jkms.2005.20.1.109
39. Kang I, Han SW. Anserine bursitis in patients with osteoarthritis of the knee. *Southern Medical Journal*. 2000;93(2):207-209.
40. Alvarez-Nemegyei J. Risk factors for pes anserinus tendinitis/bursitis syndrome: a case control study. *Journal Of Clinical Rheumatology: Practical Reports On Rheumatic & Musculoskeletal Diseases*. 2007;13(2):63-65. doi:10.1097/01.rhu.0000262082.84624.37
41. Unlu Z, Ozmen B, Tarhan S, et al. Ultrasonographic evaluation of pes anserinus tendino-bursitis in patients with type 2 diabetes mellitus. *The Journal of Rheumatology*. 2003;30(2):352-354.
42. Hill CL, Gale DR, Chaisson CE, et al. Periarticular lesions detected on magnetic resonance imaging: prevalence in knees with and without symptoms. *Arthritis & Rheumatology*. 2003;48(10):2836-2844. doi:10.1002/art.11254
43. Uson J, Aguado P, Bernad M, et al. Pes anserinus tendino-bursitis: what are we talking about? *Scandinavian Journal of Rheumatology*. 2000;29(3):184-186. doi:10.1080/030097400750002076
44. Robinson JR, Sanchez-Ballester J, Bull AMJ, et al. The posteromedial corner revisited. An anatomical description of the passive restraining structures of the medial aspect of the human knee. *The Journal of Bone and Joint Surgery*. 2004;86(5):674-681. doi:10.1302/0301-620x.86b5.14853
45. Gardiner JC, Weiss JA. Subject-specific finite element analysis of the human medial collateral ligament during valgus knee loading. *Journal of Orthopaedic Research*. 2003;21(6):1098-1106. doi:10.1016/S0736-0266(03)00113-X
46. Larsson LG, Baum J. The syndrome of anserina bursitis: an overlooked diagnosis. *Arthritis & Rheumatology*. 1985;28(9):1062-1065. doi:10.1002/art.1780280915
47. Toktas H, Dundar U, Adar S, et al. Ultrasonographic assessment of pes anserinus tendon and pes anserinus tendinitis bursitis syndrome in patients with knee osteoarthritis. *Modern Rheumatology*. 2015;25(1):128-133. doi:10.3109/14397595.2014.931909
48. Ivanoski S, Nikodinovska VV. Sonographic assessment of the anatomy and common pathologies of clinically important bursae. *Journal of Ultrasonography*. 2019;19(78):212-221. doi:10.15557/JoU.2019.0032
49. Rennie WJ, Saifuddin A. Pes anserine bursitis: incidence in symptomatic knees and clinical presentation. *Skeletal Radiology*. 2005;34(7):395-398. doi:10.1007/s00256-005-0918-7
50. Hall FM, Joffe N. CT imaging of the anserine bursa. *American Journal of Roentgenology*. 1988;150(5):1107-1108. doi:10.2214/ajr.150.5.1107
51. Algarni AD. Pes anserinus pain syndrome following total knee arthroplasty for degenerative varus: incidence and predictors. *International Orthopaedics*. 2020;44(6):1083-1089. doi:10.1007/s00264-020-04498-w
52. Sonobe T, Hakozaki M, Matsuo Y, et al. Knee locking caused by osteochondroma of the proximal tibia adjacent to the pes anserinus: A case report. *World Journal of Clinical Cases*. 2023;11(23):5595-5601. doi:10.12998/wjcc.v11.i23.5595
53. Sakamoto A, Matsuda S. Pes Anserinus Syndrome Caused by Osteochondroma in Paediatrics: A Case Series Study. *The Open Orthopaedics Journal*. 2017;11:397-403. doi:10.2174/1874325001711010397
54. Rochwerger A, Curvale G, Demortiere E, et al. Pes anserinus syndrome and osteoid osteoma. *Clinical Journal of Sport Medicine*. 2000;10(1):72-74. doi:10.1097/00042752-200001000-00014
55. Rowicki K, Płomiński J, Bachta A. Evaluation of the effectiveness of platelet rich plasma in treatment of chronic pes anserinus pain syndrome. *Ortopedia Traumatologia Rehabilitacja*. 2014;16(3):307-318. doi:10.5604/15093492.1112532
56. Homayouni K, Foruzi S, Kalhori F. Effects of kinesiotaping versus non-steroidal anti-inflammatory drugs and physical therapy for treatment of pes anserinus tendino-bursitis: A randomized comparative clinical trial. *The Physician and Sportsmedicine*. 2016;44(3):252-256. doi:10.1080/00913847.2016.1199251
57. Corominas H, Balius R, Estrada-Alarcón P, et al. Giant pes anserinus bursitis: A rare soft tissue mass of the medial knee. *Reumatología Clínica*. 2021;17(7):420-421. doi:10.1016/j.reumae.2020.06.014

58. Yagi S, Sata M. Rupture of pes anserine bursa in a patient with pes anserine pain syndrome due to osteoarthritis. *The Journal of Medical Investigation*. 2019;66(1.2):211-212. doi:10.2152/jmi.66.211
59. Shapiro SA, Hernandez LO, Montero DP. Snapping Pes Anserinus and the Diagnostic Utility of Dynamic Ultrasound. *Journal of Clinical Imaging Science*. 2017;7:39. doi:10.4103/jcis.JCIS_45_17
60. Abeles M. Osteoarthritis of the knee: anserine bursitis as an extraarticular cause of pain. *Clinical Research*. 1983;31:4471-4476.
61. Vega-Morales D, Esquivel-Valerio JA, Negrete-López R, et al. Safety and efficacy of methylprednisolone infiltration in anserine syndrome treatment. *Reumatología Clínica*. 2012;8(2):63-67. doi:10.1016/j.reuma.2011.10.016
62. Calvo-Alén J, Rua-Figueroa I, Erausquin C. Tratamiento de las bursitis anserina: infiltración local com corticoides frente a AINE: estudo prospectivo. *Revista Española de Reumatología*. 1993;20:13-15.
63. de Albornoz PM, Aicale R, Forriol F, et al. Cell Therapies in Tendon, Ligament, and Musculoskeletal System Repair. *Sports Medicine and Arthroscopy Review*. 2018;26(2):48-58. doi:10.1097/JSA.0000000000000192
64. Aicale R, Bisaccia RD, Oliviero A, et al. Current pharmacological approaches to the treatment of tendinopathy. *Expert Opinion on Pharmacotherapy*. Published online June 8, 2020:1-11. doi:10.1080/14656566.2020.1763306
65. Karabaş Ç, Talay Çaliş H, Topaloğlu US, et al. Effects of ultrasound guided leukocyte-rich platelet-rich plasma (LR-PRP) injection in patients with pes anserinus tendinobursitis. *Transfusion and Apheresis Science*. 2021;60(3):103048. doi:10.1016/j.transci.2020.103048
66. Brookler MI, Mongan ES. Anserina bursitis. A treatable cause of knee pain in patients with degenerative arthritis. *California Medical Association*. 1973;119(1):8-10.
67. Zeiss J, Coombs RJ, Booth RL, et al. Chronic bursitis presenting as a mass in the pes anserine bursa: MR diagnosis. *Journal of Computer Assisted Tomography*. 1993;17(1):137-140. doi:10.1097/00004728-199301000-00026

European Journal of Musculoskeletal Diseases
ISSN 2038-4106 print - ISSN 2975-044X online

Article

READING DEPTH EVALUATION OF INTRAORAL SCANNERS. AN IN VITRO STUDY.

F. Ferrini*, G. Gastaldi, F. Cattoni, L. Colella and E. Gherlone

Dental School, Vita-Salute San Raffaele University, Milan, Italy.

**Correspondence to*:
Francesco Ferrini,
Dental School,
Vita-Salute San Raffaele University,
Via Olgettina 60,
20132 Milan, Italy.
e-mail: ferrini.francesco@hsr.it

ABSTRACT

The objective of this *in vitro* study is to measure and compare the detectable reading depth from different types of scanners with different acquisition technology, wireless* vs wired, and the newest technology on the market . Measurements were made by scanning a cubic-shaped reference solid with sulcus of different depths and widths in the 4 sides, in order to best simulate the possible scenarios found in clinical practice. Specifically, the anterior groove has dimensions of 1 mm in depth and 1 mm in width, the lateral grooves a width of 0.5 mm with depth varying antero-posteriorly from 1 to 4 mm, and finally, the posterior groove 1 mm in width and 5 mm in depth. For each type of scanner, 9 scans were taken, by the same operator under constant environmental conditions, in a time interval of 30 sec. For each reading, 12 measurements were taken, at 12 different points within the grooves traced in the solid. The results show, a possible overlap of values between wired and wireless scanners used, and a prevailing performance from the newest scanner. Based on the measurements and the subsequently calculated statistical values, it was found that there is no statistically significant difference, between the results acquired by the two intraoral scanners from the same series (i700), but a significant difference between series i700 and i900. Given the results obtained, it can be said that: the wireless scanner represents a future solution for evolution, the practicality of use and, the absence of data dispersion during acquisition, attests to its validity. Moreover, newest technologies aim on developing and new technologies aim to evolve and improve upon the limitations of previous models, thus providing breakthrough technologies day after day, leading on better results in everyday pratictice.

KEYWORDS: *Intra-oral scanner, wireless, wired, new technologies, reading depth, gingival sulcus*

INTRODUCTION

Intra-oral scanners (IOS) are 3D scanners that, through a scanning process, make it possible to start from a physical object and obtain a three-dimensional virtual replica of it (1). The acquisition process is made possible by the emission of a light beam, by the handpiece, which strikes the object of interest; the reflection is then captured by acquisition devices and transformed, by specific software, into three-dimensional coordinates (2). These consequently produce points that are transformed into triangles or meshes (3) (Fig.1).

Received: 11 November, 2024
Accepted: 23 January, 2025

ISSN 2038-4106 print
ISSN 2975-044X online Copyright © by BIOLIFE 2024
This publication and/or article is for individual use only and may not be further reproduced without written permission from the copyright holder. Unauthorized reproduction may result in financial and other penalties. Disclosure: All authors report no conflicts of interest relevant to this article.

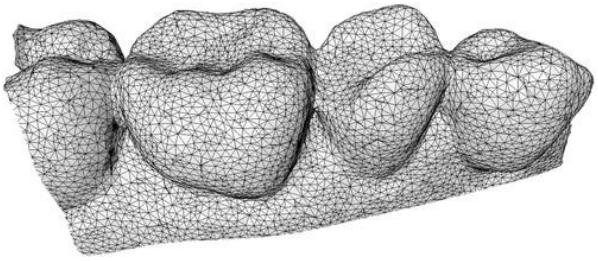

Fig. 1. *Points and meshes forming a 3D shape.*

IOS are now widely used, but nevertheless knowing their features and functionality is not so common, given the wide range of devices on the market. They are mainly distinguished into chairside intra-oral scanners and intra-oral scanners (4), which differ purely in the different workflows used, in that the former bypasses artifact production centers by providing the impression file directly to a CAD-CAM device, thus being able to deliver the artifact directly to the chairside (5). Moreover, considering this fundamental aspect, it is important to distinguish and evaluate them based on: accuracy, precision, resolution, speed, size, image quality, post-processing, cost and maintenance, and depth of reading understood as the ability to capture images at a certain distance from the emitting source; that is, a whole series of intrinsic and extrinsic variables (6) that the operator must consider, evaluate, and know, so that he or she can make the most of the instrument's capabilities (7).

In clinical practice there are countless situations where one may find oneself with grooves of different depths and widths (8).

As good practice, to make the registration more faithful (9). impression taking is used with the help of retractor wires (10) in order to have an opening in the depth and width of the gingival sulcus (11) always adapting the size of the wire to the gingival biotype and the size of the sulcus (12). Equally important for proper registration, it is necessary for the field to be clear and clean, this is possible with the help of mouth openers, retractors, aspirators, etc. (13,14).

The purpose of this study is to compare intra-oral scanners with different acquisition techniques including wireless, wired and newest technologies. In particular, it aimed to test the reading perception (15) of these scanners in depth (16), since one of the main challenges and difficulties in digital impression taking, is the registration of the gingival sulcus (17,18).

MATERIALS AND METHODS

Development

For this study, a resin reference solid model was made in the shape of a cube with grooves of different widths and depths (Fig.2).

The shape of the solid was designed to be able to standardize the acquisition and realize several different clinical conditions in the same scan. Specifically, the anterior groove has dimensions of 1 mm in depth and 1 mm in width, the lateral grooves have a width of 0.5 mm with depth varying antero-posteriorly from 1 to 4 mm, and finally, the posterior groove is 1 mm in width and 5 mm in depth (Fig.3).

Fig. 2. *Photo of the cast that was used.*

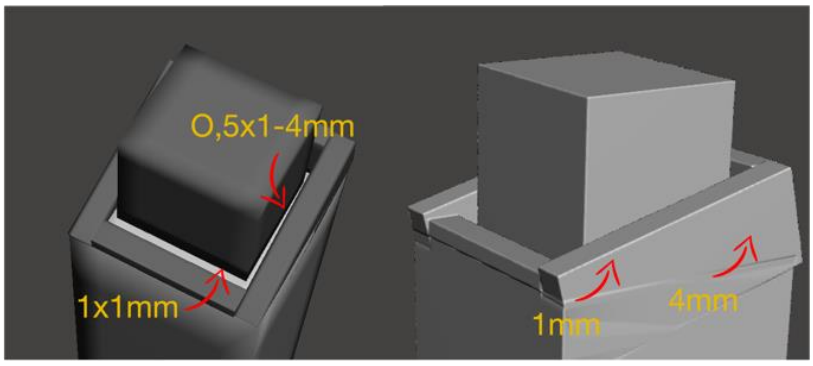

Fig. 3. *Project of the grooves.*

The creation of the solid was achieved by a digital design using a 3D designing software (PreForm vers. 3.27.1, FormLabs, Somerville, Massachusetts, USA) and three-dimensional molding with a 3D laser printer model (Form 2, FormLabs). The intraoral scanners used were: Medit i700 (Medit corp, Seongbuk-gu, Seoul, Korea) (Fig.4), Medit® i700 Wireless and Medit i900 (Fig.5,6). The results were divided into Group 1, Group 2 and Group 3 respectively.

Fig. 4. *Medit i700.*

Fig. 5. *Medit i700 wireless.*

Fig. 6. *Medit i900.*

To standardize the study and reduce possible variables, the taking of the scans was done under stable environmental conditions, in an impression time of 30 seconds, and by the same operator; in addition, for the second device, the distance of the Bluetooth base from the impression-reading handpiece was always 50 cm.

For each scanner, nine scans were carried out according to the previous arrangements. In order to perform accurate measurements, a reference grid was created on the occlusal face that could serve as a guide for the measurements taken successively within the grooves (Fig.7).



Fig. 7. *Grid for measurements designed on the cast.*

Statistical analysis

All measurements were performed on each scan of the cast with Medit Link Compare software (ML Subgroup, vers. 3.0.0, Seoul, Korea), sectioning the scan along the grooves, so that it could be possible to see the depth reached by each of the scans taken. Every measurement was recorded on an Excel page and three groups were created for the three scanners used. Nine scans were taken with each scanner and Mean (M) and Standard Deviation (SD) were calculated in order to perform a t-test calculation method to distinguish and evaluate a significant variance between the two IOS used.

RESULTS

The results obtained show an overlap of values between scanners used in groups 1, 2, and 3 in the anterior groove (1x1 mm), leading to exclude this value due to the low relevance of this result for this study, as every scanner used performed an excellent reading of this groove.

Groups 1, 2, and 3 were compared, as seen in Table I, in the lateral groves (0,5 x 1-4 mm) and the posterior groove (1x 5mm) (Table I).

Table I. *Mean and Standard Deviation in reading lateral grooves and posterior groove for each group.*

		GROUP 1	GROUP 2	GROUP 3
M	TOTAL	1,99	1,97	2,51
SD		0,827	0,871	1,135
M	0,5 x 1-4mm	2,101	2,266	2,793
SD		0,618	0,798	1,092
M	1 x 5 mm	1,699	2,388	2,485
SD		0,299	0,762	0,893

Mean and Standard Deviation calculations were made for the furrows of different width and depth detected by the three groups, and the values found were compared. Respectively for lateral furrows, with width 0.5 mm and depth varying from 1 to 4 mm, Group 1 results in both the standard deviation and mean collected lower values, compared to Group 2, and a deeper reading in Group 3. Then, in grooves with widths of 0.5 mm and depth of 4 mm, the result of mean and standard deviation was similar in group 1 and 2, with a better performance for Group 3, reaching 33% more than the other 2 Groups. In conclusion, for furrows of 1 mm width and 5 mm depth, the devices used for Group 1 and 3 performed deeper measurements than the device used for Group 2. Based on the measurements and the subsequently calculated statistical values, it was found that there was no statistically significant difference (p value < 0.05), between the results acquired by the two intraoral scanners used in Group 1 and 2. On the other hand the device used in Group 3 demonstrated a deeper reading, especially in narrow and deeper grooves, resulting in reading around 33% more than the other 2 scanners.

DISCUSSION

This study focused on the capacity of reading of two intra-oral scanners, with different acquisition techniques, to detect furrows of different width and depth.

As seen in various studies, but particularly in the study done by Kan Laohverapanich (16), intraoral scanners have very good furrow reading capabilities in comparison with traditional analog techniques. This *in vitro* study showed that the subgingival depth of an implant significantly influenced the accuracy of the 3D implant position, regardless of impression techniques. The final evaluations showed that the E3 laboratory scanner had the highest precision, and all the IOSs, except the DWIO scanner, showed better precision than the conventional impression technique.

A study conducted by Ferrari Cagidiaco (18) on the other hand, based on the results of this clinical trial, the null hypothesis, that there was no difference in the capability of the IOS independent of the vertical position of the prepared finish line, was rejected ($p < 0.005$). It was pointed out that the deeper into the sulcus the position of the margin is, the more of the part of the prepared root will be lost during the digital impression. Several clinical parameters were kept under control to ensure uniformity in order to reduce the risk of bias in this RCT. All the soft tissues around preparation margins were in similarly healthy condition; the operator was a long-time experienced user of IOS and each patient received detailed instructions before performing the digital impression. The accuracy of digital impression systems has been extensively studied in recent years. However, the wide majority of studies were performed *in vitro* and designed to detect differences among different scanners.

A recent literature review carried out by Garcia-Gil (14) was designed to evaluate the accuracy and efficiency of IOS for dental implant impression (DI) taking, compared with different impression materials (CI), and to assess the economic feasibility of introducing digital techniques, most of the studies analyzed obtained results indicating sufficient accuracy, precision or trueness to guarantee adequate passive fit; especially on partially edentulous models. Several authors concluded that dental implant angulation and depth did not influence outcomes in terms of passive fit. Regarding the economic feasibility of DI, in comparisons between DI and CI, only a single in vivo study found that DI allowed a more efficient workflow than CI.

As for studies involving comparisons between IOSs with different acquisition techniques, there are no studies comparing them for accuracy and precision. Wireless devices were found to be practical in use and, in this case, not depending on Wi-Fi transmission of data, but instead using Bluetooth transmission, the data line is not interrupted, and the speed and transmission of data does not depend on bandwidth or internet line. Wireless IOS offers clinicians a cord-free, comfortable scanning experience with the same power and capabilities as standard plug-in intraoral scanners. With a scan area of 15 mm by 13 mm, MEDIT i700 wireless can capture up to 70 frames per second for a smooth and quick intra-oral visualization. It utilizes powerful batteries in its i700 wireless, along with an intelligent power management function that switches the device to sleep mode when not in use, to save energy and enable up to 1 hour of continuous scanning. When the batteries are drained, just plug-in and charge the scanner overnight for a fresh start the next day.

The results in this study show a possible overlap of values between the two scanners from the same series (i700) but a significant difference between series i700 and i900.

With three scanners compared to each other in this study, it is appropriate to say that similar clinical studies with a wider number of IOS are desirable to assess the results acquired from this study.

CONCLUSIONS

A good knowledge of the technology of IOS systems is the basis for being able to understand their operation and the resulting image creation mechanisms.

There are many factors that can guide the clinician in choosing between one IOS and another, but primary in importance is the integration or integrability with production devices and 3D file processing applications. Based on this concept and the results obtained in the study, and the lack of statistical significance of the data, it can be affirmed that Group 2 scanner represents a future solution for the evolution of IOS technologies, with this leading to develop the newest scanner used in Group 3. Regarding the interest of this study, i.e., the evaluation of reading ability within the gingival grooves, it can be affirmed that Group 1 and 2 devices have good reading proficiency even in clinical conditions known to be difficult for the clinician, and Group 3 devices represent the great ability in developing new technologies in aid to evolution and improving. Moreover, regarding the ease of use and the absence of data leakage during acquisition, these further attest to the validity of IOSs.

Conflict of interest

The authors declare that they have no conflict of interest.

REFERENCES

1. Logozzo S, Franceschini G, Kilpela A, et al. Recent advances in dental optics – Part I: 3D intraoral scanners for restorative dentistry. *Opt Lasers Eng*. 2014;54:203-221.
2. Nikoyan L, Patel R. Intraoral scanner, three-dimensional imaging, and three-dimensional printing in the dental office. *Dent Clin North Am*. 2020;64(2):365-378.
3. Revilla-León M, Özcan M, Additively manufactured polyetheretherketone frameworks for complete- arch fixed dental prostheses: A feasibility study. *J Prosthet Dent*. 2020;124(3):372-378.
4. Revilla-León M, Özcan M, Additive manufacturing technologies used in dentistry. J Prosthet Dent. 2020;124(5):575-580.
5. Braian M, Wennerberg A. Trueness and precision of 5 intraoral scanners for scanning edentulous and dentate complete-arch mandibular casts: A comparative in vitro study. *J Prosthet Dent*. 2019;122(2):129-136.e2.
6. Zarone F, Sorrentino R, Apicella D, et al. Accuracy of a chairside intraoral scanner compared with a laboratory scanner for the completely edentulous maxilla: An in vitro 3-dimensional comparative analysis. *J Prosthet Dent*. 2020;124(6):761.e1-761.e7.
7. Naidu D, Freer TJ. Validity, reliability, and reproducibility of the iOC intraoral scanner: A comparison of tooth widths and Bolton ratios. *Am J Orthod Dentofacial Orthop*. 2013;144(2):304-310.
8. Li H, Wu T, Sun Z, Wang Z, Chen J. Influence of object translucency on the scanning accuracy of a powder-free intraoral scanner: A laboratory study. *J Prosthet Dent*. 2017;117(1):93-101.

9. Nedelcu RG, Persson AS, Scandrett R, et al. Finish line distinctness and accuracy in 7 intraoral scanners versus conventional impression: An in vitro descriptive comparison. *BMC Oral Health*. 2018;18:27.
10. Mandelli F, Ferrini F, Cavallini M, et al. Improvement of a digital impression with conventional materials: Overcoming intraoral scanner limitations. *Int J Prosthodont*. 2017;30(4):373-376.
11. Chung HM, Kim KH, Kim HS, et al. Periodontal probing on digital images compared to clinical measurements in periodontitis patients. *Sci Rep*. 2022;12:101.
12. Zheng C, Wang H, Li H, et al. Effect of free gingival graft before implant placement on peri-implant health and soft tissue changes: A randomized controlled trial. *BMC Oral Health*. 2021;21:44.
13. Revilla-León M, Özcan M, Özcan MB, et al. Analysis of different illuminance of the room lighting condition on the accuracy (trueness and precision) of an intraoral scanner. *J Prosthodont*. 2021;30(2):157-162.
14. García-Gil I, Agustín-Panadero R, Mañes-Ferrer JF, et al. Precision and practical usefulness of intraoral scanners in implant dentistry: A systematic literature review. *J Clin Exp Dent*. 2020;12(8):e784-e793.
15. Bilmenoglu C, Sahin V, Torun HO, et al. In vitro comparison of trueness of 10 intraoral scanners for implant-supported complete-arch fixed dental prostheses. *J Prosthet Dent*. 2020;124(6):755-760.
16. Laohverapanich K, et al. Different implant subgingival depth affects the trueness and precision of the 3D dental implant position: A comparative in vitro study among five digital scanners and a conventional technique. *Int J Oral Maxillofac Implants*. 2020;35(2):305-314.
17. Rech-Ortega C, Satorres-Nieto M, Agustín-Panadero R, et al. Comparative in vitro study of the accuracy of impression techniques for dental implants: Direct technique with an elastomeric impression material versus intraoral scanner. *Med Oral Patol Oral Cir Bucal*. 2019;24(1):e109-e115.
18. Ferrari Cagidiaco E, Carboncini F, De Santis R, et al. Analysis of the reproducibility of subgingival vertical margins using intraoral optical scanning (IOS): A randomized controlled pilot trial. *J Clin Med*. 2021;10(5):1012.