


European Journal of Musculoskeletal Diseases

SUPPLEMENT



Jan Saenredam. Andromeda. 1601. engraving. 25.72 x 18.1 cm



Published by
Biolife

www.biolife-publisher.it



European Journal of Musculoskeletal Diseases 13(3Suppl.1) September-
December 2024

CONTENTS

FUTURE OF BPH TREATMENT: ADVANCED TECHNIQUES FOR SYMPTOM MANAGEMENT AND SEXUAL HEALTH PRESERVATION. S.D. Pandolfo, G. Spena, A. Izzo, F. Passaro, U. Amicuzi, G. Villano, F. Capone, P. Conforti, E. Sicignano, V. Iossa, S. Cilio, F. Lasorsa, G.B. Filomena, P. Russo and A. Aveta	S1-S8
ROBOTIC-ASSISTED PARTIAL NEPHRECTOMY IN COMPLEX T2-T3 RCC: FEASIBILITY, OUTCOMES, AND EMERGING TECHNIQUES. S.D. Pandolfo, G. Spena, A. Izzo, F. Passaro, G. Villano, F. Capone, P. Conforti, U. Amicuzi, E. Sicignano, V. Iossa, S. Cilio, F. Lasorsa, G.B. Filomena, P. Russo, C. Giulioni, A. Cafarelli and A. Aveta	S9-S17
ROBOT-ASSISTED PARTIAL NEPHRECTOMY IN MANAGING COMPLETELY ENDOPHYTIC RENAL TUMORS: A SYSTEMATIC REVIEW. G. Spena, A. Izzo, F. Passaro, G. Villano, F. Capone, U. Amicuzi, P. Conforti, E. Sicignano, V. Iossa, S. Cilio, C. Giulioni, A. Cafarelli and A. Aveta	S18-S25
UPPER TRACT UROTHELIAL CARCINOMA: EAU GUIDELINES ON DIAGNOSIS, EPIDEMIOLOGY, AND RISK STRATIFICATION. G. Spena, A. Izzo, F. Passaro, U. Amicuzi, G. Villano, F. Capone, P. Conforti, E. Sicignano, V. Iossa, S. Cilio, A. Aveta, F. Lasorsa, P. Russo, G.B. Filomena and S.D. Pandolfo	S26-S32
BEYOND THE MICROSCOPE: THE UROBIOME'S HIDDEN INFLUENCE ON GENITOURINARY CANCERS. A. Aveta, S. Palumbo, G. Spena, A. Izzo, F. Passaro, G. Villano, F. Capone, U. Amicuzi, E. Sicignano, P. Conforti, S. Cilio, V. Iossa, F. Lasorsa, P. Russo, G.B. Filomena and S.D. Pandolfo	S33-S41



FUTURE OF BPH TREATMENT: ADVANCED TECHNIQUES FOR SYMPTOM MANAGEMENT AND SEXUAL HEALTH PRESERVATION

S.D. Pandolfo^{1*}, G. Spina², A. Izzo², F. Passaro², U. Amicuzi³, G. Villano³, F. Capone³, P. Conforti³, E. Sicignano³, V. Iossa⁴, S. Cilio⁵, F. Lasorsa⁶, G.B. Filomena⁷, P. Russo⁷ and A. Aveta⁸

¹ Department of Urology, University of L'Aquila, L'Aquila, Italy;

² Department of Urology, Istituto Nazionale Tumori, IRCCS, "Fondazione G. Pascale", Naples, Italy;

³ Department of Neuroscience, Reproductive Sciences and Odontostomatology, University of Naples "Federico II", Naples, Italy;

⁴ Urology Unit, Moscati Hospital, Avellino, Italy;

⁵ Department of Medicine and Surgery, Scuola Medica Salernitana, University of Salerno, Fisciano, Italy;

⁶ Department of Precision and Regenerative Medicine and Ionian Area-Urology, University of Bari "Aldo Moro", Bari, Italy;

⁷ Department of Urology, Fondazione Policlinico Universitario Agostino Gemelli, IRCCS, Rome, Italy;

⁸ Department of Urology, Ospedale del Mare, ASL Napoli 1 Centro, Naples, Italy.

*Correspondence to:

Savio Domenico Pandolfo

Department of Urology,

University of L'Aquila,

L'Aquila, Italy.

e-mail: pandolfosavio@gmail.com

ABSTRACT

Benign prostatic hyperplasia (BPH) is a common condition in older men, often causing lower urinary tract symptoms that significantly impact quality of life. Traditional treatments, such as transurethral resection of the prostate and open prostatectomy, effectively alleviate symptoms but pose risks of sexual dysfunction, particularly impacting ejaculation preservation (EP). In response, minimally invasive surgical therapies (MISTs) have emerged, aiming to reduce symptoms while preserving sexual function. This review explores key MISTs—such as iTind, Rezum, UroLift, and Aquablation—and robot-assisted simple prostatectomy (RASP) as evolving options in BPH management. These techniques offer specific advantages depending on prostate size and anatomy, with the goal of balancing efficacy and quality-of-life outcomes. Studies show promising results for EP preservation and symptom reduction, although the efficacy of each technique varies. Data were synthesized from comprehensive literature reviews, highlighting procedural details, patient selection criteria, and functional outcomes. Despite progress, limitations exist, including variability in study design and short follow-up durations. MISTs and RASP represent a shift in BPH treatment, especially for younger, sexually active men seeking therapies that prioritize sexual health. Long-term studies and randomized trials are necessary to establish the durability and comparative efficacy of these advanced interventions.

KEYWORDS: *Benign prostatic hyperplasia, lower urinary tract symptoms, minimally invasive surgical therapies, ejaculation preservation, robot-assisted simple prostatectomy*

Received: 01 November, 2024

Accepted: 17 December, 2024

ISSN 2038-4106 print

ISSN 2975-044X online Copyright © by BIOLIFE 2024

This publication and/or article is for individual use only and may not be further reproduced without written permission from the copyright holder. Unauthorized reproduction may result in financial and other penalties. Disclosure: All authors report no conflicts of interest relevant to this article.

INTRODUCTION

Benign prostatic hyperplasia (BPH) is one of the most prevalent conditions affecting older men, with symptoms of lower urinary tract dysfunction that can severely impact quality of life (1). BPH-related lower urinary tract symptoms (LUTS) are managed according to severity and the patient's overall health (2). A proper assessment can be made by performing uroflowmetry, a valuable, guideline-recommended diagnostic tool for men with benign prostatic obstruction (BPO) that also serves as a practical resource in managing BPH-related LUTS (3–5).

Current guidelines typically recommend conservative management as a first step, including lifestyle modifications and pharmacological treatments. However, these strategies often come with significant side effects, particularly impacting sexual function, which may lead to non-adherence or discontinuation of therapy. When conservative measures fail, surgical options are considered (6).

Historically, transurethral resection of the prostate (TURP) and open prostatectomy were the mainstay treatments for BPH (7). While effective in symptom relief, these procedures carry a high risk of sexual dysfunction, especially ejaculatory disorders (8–10). Importantly, before considering any surgical intervention for BPH, it is crucial to exclude prostate cancer. Studies have shown that incidental findings of prostate cancer in TURP specimens are not uncommon, with significant proportions of patients presenting with aggressive tumor features (11,12). As a result, there has been a growing interest in developing less invasive techniques that can relieve symptoms while preserving sexual function (13). This shift in focus reflects a broader trend in urology: prioritizing patients' quality of life, particularly among younger, sexually active men who are increasingly seeking treatments that minimize sexual side effects (14). In response to these demands, various minimally invasive surgical therapies (MISTs) have emerged over the past decade, including techniques such as Urolift, temporarily Implanted Nitinol Device (iTIND), Rezūm (water vapor therapy), Transperineal laser ablation (TPLA), and Aquablation. Each technique comes with its own set of advantages and limitations, often dictated by prostate size and the presence of anatomical variations like a median lobe (15). Additionally, techniques like Robot-Assisted Simple Prostatectomy (RASP) provide an alternative for larger prostates, aiming to maintain functional outcomes while effectively reducing LUTS (7).

This review aims to explore the latest advances in BPH surgical management, with a focus on MISTs and emerging techniques, assessing their efficacy, safety, and impact on sexual function, especially on ejaculation preservation (EP).

MATERIALS AND METHODS

A comprehensive and narrative review of the literature was conducted on PubMed, Embase, and the Cochrane Library, which encompassed publications up to September 2024.

Search Strategy and Data Extraction

The search strategy was designed with key terms aligned to the review's aims, including "BPH surgical techniques," "minimally invasive therapies," "ejaculatory function preservation," "Urolift," "iTIND," "Aquablation," "water vapor thermal therapy," and "robot-assisted simple prostatectomy." These keywords were chosen to capture a wide range of relevant literature on BPH surgical management, covering procedural specifics, clinical results, and long-term effectiveness.

Our review sought to include studies that detailed various surgical techniques, reported outcomes such as International Prostate Symptom Scores (IPSS), health-related quality of life (HRQL), maximum urinary flow rate (Q_{max}), post-void residual urine volume (PVR), Ejaculatory Domain-Male Sexual Health Inventory (Ej-MSHQ), and International Index of Erectile Function (IIEF), and assessed impacts on sexual function preservation. Additional articles were also identified through manual searches for references in relevant studies and reviews to ensure thorough and unbiased selection.

Data extraction was carefully conducted by two independent authors (AA and GS) following a predefined protocol for resolving any disagreements, with a third author (SDP) involved for consensus as needed, thereby ensuring data accuracy and reliability.

Data Synthesis

The collected data were synthesized to provide a thorough overview of the current state of surgical approaches for managing BPH, highlighting minimally invasive therapies and their effectiveness in preserving ejaculatory function. This synthesis offers a narrative that captures the scope of research in the field, focusing on procedural specifics, patient selection criteria, comparative results, and recent innovations in urological surgical methods.

RESULTS

TURP: is the standard still the standard for BPH??

TURP remains the gold standard surgical treatment for BPH and is widely performed for managing LUTS due to its proven efficacy in symptom relief (9). However, a significant drawback of traditional TURP is the high incidence of postoperative retrograde ejaculation, which is reported to affect 70-90% of patients (6). This adverse effect not only contributes to male infertility but also impacts overall sexual satisfaction, leading to decreased patient satisfaction and quality of life (16).

To address this concern, Jie Liao and colleagues explored a modified version of TURP that emphasizes the preservation of the bladder neck. Their study demonstrated that bladder neck preservation during TURP significantly reduced the rates of retrograde ejaculation compared to standard TURP. Specifically, at the 3-, 6-, and 12-month follow-ups, the rates of retrograde ejaculation in the bladder neck preservation group were 58.6%, 32.8%, and 32.8%, respectively, compared to 87.3%, 77.2%, and 74.7% in the standard TURP group, with all differences being statistically significant ($p < 0.001$) (17).

Despite these advancements, TURP with bladder neck preservation does not compromise the clinical outcomes typically expected from standard TURP. According to Liao's findings, both techniques demonstrated comparable improvements in IPSS, HRQL, Qmax, and PVR. Furthermore, there were no significant differences in operative time, catheterization duration, hemoglobin decrease, or hospital stay between the two groups (17).

According to a study by Saddam H. Al Demour and colleagues, the impact of TURP on EF and EP remains a topic of debate. Their research, which evaluated 91 patients undergoing TURP, found that TURP does not have a significant negative impact on EF. Specifically, patients with normal baseline EF (Group A) maintained stable EF scores postoperatively, with 90.2% of patients showing no deterioration at six months. However, for patients who had preexisting erectile dysfunction (ED) (Group B), significant improvements in EF were observed after TURP, likely due to the relief of LUTS (18).

Despite these positive outcomes for EF, the study highlighted a significant decline in EP among patients in Group A. The mean Ej-MSHQ score dropped substantially from baseline to six months post-TURP (26.44 ± 3.43 vs. 19.12 ± 4.56 , $p < 0.001$). This underscores the well-documented risk of retrograde ejaculation, a common complication attributed to bladder neck disruption during TURP. In contrast, patients with preexisting ED showed no significant change in EP, reflecting that the impact of TURP on ejaculatory outcomes is more pronounced in individuals with initially normal sexual function (18).

These findings emphasize the complexity of managing sexual function post-TURP and suggest a nuanced approach to counseling patients. While TURP may not worsen EF and could even improve it for those with baseline ED, the risk of EP dysfunction remains high. Therefore, a thorough preoperative discussion about these potential outcomes before performing TURP is essential, especially for patients who prioritize sexual function in their treatment decisions.

Novel Surgical Techniques – MISTs

1. iTIN

iTind represents a promising MIST for managing LUTS associated with BPH. Unlike traditional ablative procedures, iTind offers a unique mechanism of action using expandable nitinol struts to remodel the prostatic urethra and bladder neck without leaving a permanent implant. This non-ablative technique addresses a crucial need in urology: to provide effective symptom relief while preserving sexual and ejaculatory function.

In a comprehensive multicenter study by Kadner et al., 81 men treated with iTind demonstrated significant improvements in symptom scores and peak urinary flow, maintained over a two-year period. The average IPSS dropped from 20.51 to 8.51, while the Qmax increased from 7.62 to 16.00 mL/s. Importantly, none of the sexually active participants reported a decline in sexual or ejaculatory function. However, the presence of a median lobe was identified as a predictor of treatment failure, underscoring the need for careful patient selection (19).

Further supporting these findings, a randomized, sham-controlled trial by Elterman et al. highlighted the preservation of sexual function in 185 men treated with iTind. SHIM and IIEF scores remained stable, with an observed improvement in IIEF for men without preexisting erectile dysfunction. EP outcomes were also favorable, reinforcing iTind's role in addressing patient concerns about sexual side effects. Notably, the study reported a median prostate volume of around 40 mL for treated patients, indicating that iTind is most effective in those with moderately enlarged prostates (20).

Additionally, De Nunzio et al. presented 6-month interim results from a multicenter study involving 70 patients, showing substantial reductions in IPSS (from 21.2 to 8.3) and a notable increase in Qmax (from 7.3 to 12.0 mL/s).

Patients experienced a rapid recovery and returned to daily activities shortly after the procedure, with minimal adverse events. Crucially, sexual and urinary functions were preserved, further emphasizing iTind's potential as a safe and effective option for men seeking symptom relief without compromising their quality of life.

Overall, the recommended prostate volume for iTind use typically falls below 75 mL, with studies noting a median volume of 37 to 43 mL across cohorts, highlighting the importance of careful volume-based selection to optimize outcomes. Together, these studies illustrate iTind's capability to transform BPH management by balancing efficacy with the preservation of sexual health, making it particularly appealing for younger, sexually active men or those who are unwilling to risk the sexual dysfunction often associated with conventional treatments.

2. Rezum

Rezum® water vapor thermal therapy stands out as a minimally invasive option for managing LUTS caused by BPH, leveraging convective radiofrequency-generated steam to ablate excess prostatic tissue. This approach is distinctive in its ability to deliver targeted thermal energy precisely within the prostate, causing cell death in the treated areas without affecting adjacent anatomical structures. This precision helps avoid complications such as damage to the external sphincter or bladder neck, which are common concerns with traditional ablative techniques like transurethral needle ablation or transurethral microwave thermotherapy (21).

The ability of Rezum® to preserve sexual function, particularly ejaculatory function, is a significant advantage. In the randomized controlled trial led by McVary et al., involving 197 men with moderate to severe LUTS, Rezum® therapy resulted in a 12.5-point reduction in the IPSS and a 4.6 mL/s increase in Qmax at one year. Notably, the study reported no cases of *de novo* erectile dysfunction, and ejaculatory function remained well preserved, with a 31% decrease in ejaculatory bother scores ($p = 0.0011$), reflecting the therapy's efficacy in maintaining patients' sexual health.

In another study conducted by Alegorides et al., involving 62 patients treated across two French hospitals, similar outcomes were observed. At one year, patients experienced a 12-point reduction in IPSS (61.5%, $p < 0.001$) and a 6 mL/s improvement in Qmax ($p < 0.001$). Importantly, no new cases of erectile dysfunction occurred, and the rate of retrograde ejaculation was only 10.8%, demonstrating the therapy's potential to spare ejaculatory function (8).

Despite these benefits, Rezum® therapy is not without limitations. It is most effective for prostate sizes between 30 and 80 cm³, and while it can be used in cases with a median lobe, treatment outcomes may vary depending on prostate anatomy. Additionally, some patients experience transient urinary retention or dysuria post-procedure, and the retreatment rate, though low (reported as 2.1% in some studies), remains a consideration for long-term management. Overall, while Rezum® offers a promising balance of efficacy and preservation of sexual function, further long-term studies are needed to fully establish its role in BPH management and assess outcomes beyond the initial follow-up period (5).

3. UROLIFT

The UroLift system, a minimally invasive technique for managing LUTS associated with BPH, has gained prominence for its ability to improve urinary symptoms while preserving sexual function. Unlike traditional methods, which often lead to sexual dysfunction, the UroLift procedure employs permanent suture-based implants to mechanically retract obstructive prostatic lobes, opening the prostatic urethra without incisions or tissue removal. This approach allows for symptom relief without affecting structures vital for ejaculation, making it a preferred option for sexually active men (22,23).

In a study by Annese et al., involving 35 men with severe BPH, the UroLift system demonstrated significant improvements in urinary flow and symptom relief. Specifically, the Q-max increased by 68% ($p = 0.001$), while the PVR decreased by 68% ($p = 0.005$). The IPSS showed a 55% reduction ($p < 0.0001$), reflecting marked symptom relief. Remarkably, all patients preserved EF, with no cases of retrograde ejaculation reported. Patient satisfaction was high, with 88.6% expressing satisfaction with LUTS improvement and 100% reporting satisfaction with preserved ejaculation (24).

Bardoli et al. reported similar findings in a cohort of 11 patients treated with UroLift. They observed an average 9-point improvement in IPSS and a significant reduction in hospital stay and operating time. No patients experienced sexual dysfunction, underscoring the system's efficacy and safety. Additionally, a comparison study by Tutrone and Schiff highlighted UroLift's advantages over other therapies, such as lower catheterization rates (7% for UroLift versus 55% for Rezum) and greater patient satisfaction with postoperative recovery (83% for UroLift) (22).

Despite these benefits, UroLift is most suitable for patients with prostate volumes less than 80 cm³ and without a prominent median lobe. The technique may have limitations in achieving optimal symptom relief for individuals with

larger prostates or more complex anatomical variations. Nevertheless, UroLift remains a valuable option, particularly for those prioritizing the preservation of ejaculatory function (25).

4. TPLA

TPLA is a cutting-edge, micro-invasive technique designed to manage BPH by delivering targeted laser energy to prostatic tissue through a transperineal approach. The procedure employs the SoracteLite™ EchoLaser system, utilizing 300-micron optical fibers inserted via 21-gauge needles. Under precise ultrasound guidance, these fibers administer energy to create controlled zones of coagulative necrosis, all while sparing critical anatomical structures such as the urethra and bladder neck. This meticulous precision is particularly advantageous for preserving sexual and ejaculatory function, a concern that has driven much of the innovation in BPH treatment (26).

The efficacy of TPLA has been well documented in a multicenter study involving 160 patients, demonstrating marked improvements in LUTS and urodynamic parameters. At six months, the IPSS improved significantly, decreasing from 22.5 to 7.7 ($p < 0.001$), and the Qmax increased from 8.0 to 14.3 mL/s ($p < 0.001$). Post-void residual volume (PVR) also reduced from 89.5 to 27.2 mL ($p < 0.001$), and prostate volume shrank from 75.0 to 60.3 mL ($p < 0.001$). These gains were sustained at 12 months, with IPSS improving further to 7.0 and Qmax reaching 15.0 mL/s ($p < 0.001$), indicating the durability of the treatment's effects (27).

One of TPLA's most compelling advantages is its capacity to preserve ejaculatory function. The procedure avoids interference with the bladder neck muscles, crucial for maintaining antegrade ejaculation, which distinguishes it from more invasive options like TURP that often result in retrograde ejaculation or anejaculation. In the study, only 1.2% of patients experienced ejaculatory dysfunction, and some even reported improvements in the Ej-MSHQ scores, highlighting the potential benefits for sexual health. Although a minority experienced transient discomfort or dysuria post-procedure, the overall complication rate was low, with 4.3% of patients having minor grade I issues and just one grade III complication, a prostatic abscess, which was effectively managed (28).

However, TPLA is not without its limitations. It requires a learning curve for practitioners, and additional prospective studies with larger cohorts and longer follow-ups are necessary to fully establish its long-term efficacy and safety profile. Nonetheless, its ability to deliver significant symptom relief while minimizing adverse sexual effects positions TPLA as a promising intermediate option between pharmacological treatment and more invasive surgical interventions (29).

5. Aquablation

Aquablation therapy is a novel, minimally invasive surgical approach that utilizes a high-velocity waterjet to ablate prostate tissue. This technique is robotically executed and guided by real-time ultrasound imaging, allowing for precise tissue resection without the thermal damage associated with other methods, such as TURP. The advantage of Aquablation lies in its ability to treat a wide range of prostate sizes, up to 150 mL, while minimizing surgeon-to-surgeon variability and preserving key anatomical structures involved in sexual function, particularly the ejaculatory ducts (30).

Results from the WATER II 5-year study, involving 101 men with prostate volumes between 80 and 150 mL, demonstrated sustained improvements in urinary symptoms. The mean IPSS decreased from 22.6 to 6.8 at five years ($p < 0.001$), and the Qmax increased from 8.6 to 17.1 mL/s ($p < 0.001$). Freedom from reoperation was remarkably high, at 96.3% over five years. Importantly, a comparative trial between Aquablation and TURP showed that both procedures resulted in similar symptom relief, with a mean 12-month reduction in IPSS of 15.1 points. However, Aquablation had a significantly lower rate of retrograde ejaculation, occurring in only 6% of patients compared to 23.1% with TURP ($p = 0.0015$) (30).

In another study focused on smaller prostates (30-80 mL), Aquablation demonstrated robust outcomes, with a 15.6-point decrease in IPSS at one year and an increase in Qmax to 20.4 mL/s. Despite these strong results, 26.7% of patients reported *de novo* ejaculatory dysfunction, highlighting that while the risk is reduced compared to TURP, ejaculatory preservation is not absolute. Overall, Aquablation presents a compelling balance between efficacy and sexual function preservation, though long-term data and further studies on larger prostates are needed to optimize patient selection and procedural techniques (31).

RASP

Robot-assisted simple prostatectomy (RASP), particularly using the urethral-sparing Madigan technique (us-RASP), has emerged as a key advancement for managing BPH in cases involving large prostate volumes over 80 mL. This approach, facilitated by robotic platforms, prioritizes the preservation of the prostatic urethra, aiming to maintain sexual function while effectively resolving bladder outlet obstruction (7,32). The robotic system enhances surgical precision,

minimizing perioperative morbidity and reducing complications like significant hematuria and the need for prolonged bladder irrigation (7). Indeed, robotic technology has revolutionized modern urology, providing precise instruments that enable advanced surgical control while minimizing operative risks. This progress is especially relevant in complex procedures, where preserving functional outcomes is critical (33,34).

The largest pooled series of us-RASP, detailed by Anceschi et al., evaluated 94 patients with prostate volumes between 110 and 180 mL over a median follow-up of 40.7 months. The study revealed that 93.6% of patients experienced a $\geq 30\%$ reduction in IPSS, while 72.6% preserved ejaculatory function, as measured by the Ej-MSHQ. Notably, the presence of a median lobe did not significantly impact functional outcomes ($p = 0.891$), supporting the feasibility of us-RASP even in complex cases. In this scenario, further advancements include the use of near-infrared fluorescence imaging, which enhances the visualization and preservation of the urethral anatomy during surgery (32). Simone et al. reported promising outcomes in a preliminary series, with complete symptom relief in all cases and preservation of antegrade ejaculation in two-thirds of patients. These findings underscore the potential of robotic technology to revolutionize BPH treatment by balancing bladder obstruction resolution with sexual function preservation (35-37).

Despite these successes, limitations remain. RASP is best suited for large prostates and may not be necessary for smaller glands, where less invasive options suffice. Additionally, while early data are encouraging, further long-term studies are needed to solidify RASP's role as a durable and effective treatment option for ejaculatory function preservation.

LIMITATIONS

This review has several limitations. First, the reliance on narrative synthesis rather than a meta-analysis restricts the ability to quantitatively compare outcomes across studies. The heterogeneity in patient selection, procedural details, and follow-up periods across different studies introduces variability that may influence the reported results. Additionally, while efforts were made to include studies focused on preserving sexual function, the available literature may still lack comprehensive data, particularly for novel techniques like TPLA and Aquablation, where long-term efficacy and safety are not yet fully established.

Finally, although the emphasis was placed on functional outcomes related to EP, many studies used different definitions and assessment tools, complicating direct comparisons of EP outcomes.

CONCLUSIONS

MISTs for BPH have enabled significant progress in managing LUTS while preserving key functional outcomes, including EP. Techniques like iTind, Rezum, UroLift, and Aquablation provide viable options for patients who prioritize sexual function, each offering unique benefits based on prostate size and anatomical characteristics. Additionally, us-RASP has expanded the possibilities for treating larger prostates while maintaining urethral integrity. Together, these emerging techniques reflect a shift in urology towards patient-centered care, where symptom relief is balanced with the preservation of quality of life. However, further research with longer follow-up and larger, randomized studies is essential to establish the durability and comparative efficacy of these methods fully.

Acknowledgements

None

Funding

None

Conflict of interest

The authors declare that they have no conflict of interest.

REFERENCES

1. Manfredi C, Arcaniolo D, Spatafora P, et al. Emerging minimally invasive transurethral treatments for benign prostatic hyperplasia: a systematic review with meta-analysis of functional outcomes and description of complications. *Minerva Urol Nephrol.* 2022;74(4):389-399. doi:10.23736/S2724-6051.21.04530-4

2. Coyne KS, Sexton CC, Thompson CL, et al. The prevalence of lower urinary tract symptoms (LUTS) in the USA, the UK and Sweden: results from the Epidemiology of LUTS (EpiLUTS) study. *BJU Int.* 2009;104(3):352-360. doi:10.1111/j.1464-410X.2009.08427.x
3. Pandolfo SD, Crauso F, Aveta A, et al. A Novel Low-Cost Uroflowmetry for Patient Telemonitoring. *Int J Environ Res Public Health.* 2023;20(4):3287. doi:10.3390/ijerph20043287
4. Busetto GM, Lombardo R, De Nunzio C, et al. Ejaculation sparing of classic and minimally invasive surgical treatments of LUTS/BPH. *Prostate Cancer Prostatic Dis.* Published online April 13, 2024. doi:10.1038/s41391-024-00834-y
5. Siena G, Tellini R, Cindolo L. Can Rezūm stand out as the most versatile and better performing minimally invasive treatment for the management of LUTS related to BPH? *Minerva Urol Nephrol.* 2022;74(5):499-501. doi:10.23736/S2724-6051.22.04861-3
6. Sibona M, Destefanis P, Vercelli E, Secco S, Gontero P, Cindolo L. Ejaculation physiology and dysfunction after BPH surgery: the role of the new MISTs. *Prostate Cancer Prostatic Dis.* 2023;26(3):475-482. doi:10.1038/s41391-023-00686-y
7. Pandolfo SD, Del Giudice F, Chung BI, et al. Robotic assisted simple prostatectomy versus other treatment modalities for large benign prostatic hyperplasia: a systematic review and meta-analysis of over 6500 cases. *Prostate Cancer Prostatic Dis.* Published online November 19, 2022. doi:10.1038/s41391-022-00616-4
8. McVary KT, Gange SN, Gittelman MC, et al. Erectile and Ejaculatory Function Preserved With Convective Water Vapor Energy Treatment of Lower Urinary Tract Symptoms Secondary to Benign Prostatic Hyperplasia: Randomized Controlled Study. *J Sex Med.* 2016;13(6):924-933. doi:10.1016/j.jsxm.2016.03.372
9. Busetto GM, Giovannone R, Antonini G, et al. Short-term pretreatment with a dual 5 α -reductase inhibitor before bipolar transurethral resection of the prostate (B-TURP): evaluation of prostate vascularity and decreased surgical blood loss in large prostates. *BJU Int.* 2015;116(1):117-123. doi:10.1111/bju.12917
10. Minervini G, Romano A, Petrucci M, et al. Oral-facial-digital syndrome (OFD): 31-year follow-up management and monitoring. *J Biol Regul Homeost Agents.* 2018;32(2 Suppl. 1):127-130.
11. Tarantino G, Crocetto F, Vito CD, et al. Clinical factors affecting prostate-specific antigen levels in prostate cancer patients undergoing radical prostatectomy: a retrospective study. *Future Sci OA.* 2021;7(3):FSO643. doi:10.2144/fsoa-2020-0154
12. Cantiello F, Crocero F, Alba S, et al. Refining surgical strategies in ThuLEP for BPH: a propensity score matched comparison of En-bloc, three lobes, and two lobes techniques. *World J Urol.* 2024;42(1). doi:10.1007/s00345-024-05136-5
13. Ditunno F, Manfredi C, Licari LC, et al. Benign Prostatic Hyperplasia Surgery: A Snapshot of Trends, Costs, and Surgical Retreatment Rates in the USA. *Eur Urol Focus.* Published online 2024. doi:10.1016/j.euf.2024.04.006
14. Cameron AP, Chung DE, Dielubanza EJ, et al. The AUA/SUFU Guideline on the Diagnosis and Treatment of Idiopathic Overactive Bladder. *J Urol.* 2024;212(1):11-20. doi:10.1097/JU.0000000000003985
15. Checcucci E, Veccia A, De Cillis S, et al. New Ultra-minimally Invasive Surgical Treatment for Benign Prostatic Hyperplasia: A Systematic Review and Analysis of Comparative Outcomes. *Eur Urol Open Sci.* 2021;33:28-41. doi:10.1016/j.euros.2021.08.009
16. Gillling PJ, Barber N, Bidair M, et al. Five-year outcomes for Aquablation therapy compared to TURP: results from a double-blind, randomized trial in men with LUTS due to BPH. *Can J Urol.* 2022;29(1):10960-10968.
17. Liao J, Zhang X, Chen M, et al. Transurethral resection of the prostate with preservation of the bladder neck decreases postoperative retrograde ejaculation. *Wideochirurgia Inne Tech Maloinwazyjne Videosurgery Miniinvasive Tech.* 2019;14(1):96-101. doi:10.5114/wiitm.2018.79536
18. Al Demour SH, Abuhamad M, Santarisi AN, et al. The Effect of Transurethral Resection of the Prostate on Erectile and Ejaculatory Functions in Patients with Benign Prostatic Hyperplasia. *Urol Int.* 2022;106(10):997-1004. doi:10.1159/000524957
19. Kadner G, Valerio M, Giannakis I, et al. Second generation of temporary implantable nitinol device (iTind) in men with LUTS: 2 year results of the MT-02-study. *World J Urol.* 2020;38(12):3235-3244. doi:10.1007/s00345-020-03140-z
20. Elterman D, Alshak MN, Martinez Diaz S, et al. An Evaluation of Sexual Function in the Treatment of Lower Urinary Tract Symptoms Secondary to Benign Prostatic Hyperplasia in Men Treated with the Temporarily Implanted Nitinol Device. *J Endourol.* 2023;37(1):74-79. doi:10.1089/end.2022.0226
21. Doppalapudi SK, Gupta N. What Is New with Rezūm Water Vapor Thermal Therapy for LUTS/BPH? *Curr Urol Rep.* 2021;22(1):4. doi:10.1007/s11934-020-01018-6

22. Can the UroLift prostatic implant device treat the symptoms of benign prostatic hypertrophy, avoid sexual dysfunction and reduce hospital TURP waiting times? A single centre, single surgeon experience and review of the literature - PubMed. Accessed November 4, 2024. <https://pubmed.ncbi.nlm.nih.gov/univqaq.idm.oclc.org/28609136/>
23. Knight L, Dale M, Cleves A, Pelekanou C, Morris R. UroLift for Treating Lower Urinary Tract Symptoms of Benign Prostatic Hyperplasia: A NICE Medical Technology Guidance Update. *Appl Health Econ Health Policy*. 2022;20(5):669-680. doi:10.1007/s40258-022-00735-y
24. Annese P, d'Altiglia N, Mancini V, et al. Preserving ejaculatory function in young patients with lower urinary tract symptoms: medium- to long-term follow-up of prostatic urethral lift at a single center. *Ther Adv Urol*. 2021;13:17562872211037109. doi:10.1177/17562872211037109
25. Denisenko A, Somani B, Agrawal V. Recent advances in UroLift: A comprehensive overview. *Turk J Urol*. 2022;48(1):11-16. doi:10.5152/tud.2022.21149
26. Manenti G, Nezzo M, Ryan CP, et al. Transperineal laser ablation (TPLA) with ultrasound/MRI fusion guidance in the treatment of localized radiotherapy-resistant prostate cancer. *BJR Open*. 2023;5(1):20230042. doi:10.1259/bjro.20230042
27. Pacella CM, Patelli G, Iapicca G, et al. Transperineal laser ablation for percutaneous treatment of benign prostatic hyperplasia: a feasibility study. Results at 6 and 12 months from a retrospective multi-centric study. *Prostate Cancer Prostatic Dis*. 2020;23(2):356-363. doi:10.1038/s41391-019-0196-4
28. de Rienzo G, Lorusso A, Minafra P, et al. Transperineal interstitial laser ablation of the prostate, a novel option for minimally invasive treatment of benign prostatic obstruction. *Eur Urol*. 2021;80(1):95-103. doi:10.1016/j.eururo.2020.08.018
29. Manenti G, Perretta T, Nezzo M, et al. Transperineal Laser Ablation (TPLA) Treatment of Focal Low-Intermediate Risk Prostate Cancer. *Cancers*. 2024;16(7):1404. doi:10.3390/cancers16071404
30. Bhojani N, Bidair M, Kramolowsky E, et al. Aquablation Therapy in Large Prostates (80-150 mL) for Lower Urinary Tract Symptoms Due to Benign Prostatic Hyperplasia: Final WATER II 5-Year Clinical Trial Results. *J Urol*. 2023;210(1):143-153. doi:10.1097/JU.0000000000003483
31. Misrai V, Rijo E, Zorn KC, Barry-Delongchamps N, Descazeaud A. Waterjet Ablation Therapy for Treating Benign Prostatic Obstruction in Patients with Small- to Medium-size Glands: 12-month Results of the First French Aquablation Clinical Registry. *Eur Urol*. 2019;76(5):667-675. doi:10.1016/j.eururo.2019.06.024
32. Anceschi U, Amparore D, Prata F, et al. Predictors of mid-term functional outcomes for robot-assisted Madigan simple prostatectomy: results of a multicentric series according to the BPH-6 achievement. *Minerva Urol Nephrol*. 2023;75(5):607-615. doi:10.23736/S2724-6051.23.05373-9
33. Pandolfo SD, Wu Z, Campi R, et al. Outcomes and Techniques of Robotic-Assisted Partial Nephrectomy (RAPN) for Renal Hilar Masses: A Comprehensive Systematic Review. *Cancers*. 2024;16(4):693. doi:10.3390/cancers16040693
34. Pandolfo SD, Cerrato C, Wu Z, et al. A systematic review of robotic partial nephrectomy outcomes for advanced indications: Large (cT2-T3), solitary kidney, completely endophytic, hilar, recurrent, and multiple renal tumors. *Asian J Urol*. Published online August 1, 2023. doi:10.1016/j.ajur.2023.06.001
35. *Urethra and Ejaculation Preserving Robot-Assisted Simple Prostatectomy: Near-Infrared Fluorescence Imaging-Guided Madigan Technique*. Vol 75.; 2019. doi:10.1016/j.eururo.2018.11.051
36. Lasorsa F, Orsini A, Bignante G, et al. Predictors of delayed hospital discharge after robot-assisted partial nephrectomy: the impact of single-port robotic surgery. *World J Urol*. 2024 Dec 13;43(1):30. doi: 10.1007/s00345-024-05391-6
37. Bignante G, Orsini A, Lasorsa F, et al. PRobotic-assisted surgery for the treatment of urologic cancers: recent advances. *Expert Rev Med Devices*. 2024 Dec 1:1-13. doi: 10.1080/17434440.2024.2435546



ROBOTIC-ASSISTED PARTIAL NEPHRECTOMY IN COMPLEX T2-T3 RCC: FEASIBILITY, OUTCOMES, AND EMERGING TECHNIQUES

S.D. Pandolfo^{1*}, G. Spina², A. Izzo², F. Passaro², G. Villano³, F. Capone³, P. Conforti³, U. Amicuzi³, E. Sicignano³, V. Iossa⁴, S. Cilio⁵, F. Lasorsa⁶, G.B. Filomena⁷, P. Russo⁷, C. Giulioni⁸, A. Cafarelli⁸ and A. Aveta⁹

¹ Department of Urology, University of L'Aquila, L'Aquila, Italy;

² Department of Urology, Istituto Nazionale Tumori, IRCCS, "Fondazione G. Pascale", Naples, Italy;

³ Department of Neuroscience, Reproductive Sciences and Odontostomatology, University of Naples "Federico II", Naples, Italy;

⁴ Urology Unit, Moscati Hospital, Avellino, Italy;

⁵ Department of Medicine and Surgery, Scuola Medica Salernitana, University of Salerno, Fisciano, Italy;

⁶ Department of Precision and Regenerative Medicine and Ionian Area-Urology, University of Bari "Aldo Moro", Bari, Italy;

⁷ Department of Urology, Fondazione Policlinico Universitario Agostino Gemelli, IRCCS, Rome, Italy;

⁸ Urology Unit, Casa di Cura Villa Igea, Ancona, Italy;

⁹ Department of Urology, Ospedale del Mare, ASL Napoli 1 Centro, Naples, Italy.

*Correspondence to:

Savio Domenico Pandolfo,

Department of Urology,

University of L'Aquila,

L'Aquila, Italy.

e-mail: pandolfosavio@gmail.com

ABSTRACT

Renal cell carcinoma (RCC) management, especially for large and complex tumors classified as T2 or T3, remains a surgical challenge. Radical nephrectomy (RN) was traditionally considered the primary treatment for high-stage RCC, but recent advancements in robotic-assisted partial nephrectomy (RAPN) have expanded nephron-sparing options. This systematic review evaluates RAPN's safety, efficacy, and oncological outcomes in managing cT2-T3 RCC. Five retrospective studies encompassing 588 patients were analyzed, revealing that RAPN achieves acceptable perioperative outcomes with complication rates comparable to open techniques, yet offers the benefits of a minimally invasive approach. Functional outcomes, such as eGFR preservation, were favorable, and oncological outcomes, including positive surgical margins and recurrence rates, aligned with traditional approaches. Notably, augmented reality has introduced enhanced precision along with 3D models. This technology aids in preserving healthy tissue and achieving precise resections.

KEYWORDS: Renal cell carcinoma, T2, T3, robotic-assisted partial nephrectomy, nephron-sparing surgery, complex renal tumors

INTRODUCTION

Received: 30 September, 2024

Accepted: 17 December, 2024

ISSN 2038-4106 print

ISSN 2975-044X online Copyright © by BIOLIFE 2024

This publication and/or article is for individual use only and may not be further reproduced without written permission from the copyright holder. Unauthorized reproduction may result in financial and other penalties. Disclosure: All authors report no conflicts of interest relevant to this article.

Renal cell carcinoma (RCC) is one of the ten most frequently diagnosed cancers in adults globally, with an estimated 79,000 new cases and nearly 14,000 deaths in the USA in 2022 alone (1,2). Key risk factors for RCC include smoking, obesity, and hypertension, which lead to cellular and metabolic alterations that can promote tumor initiation and progression. (3–5).

RCC represents a significant oncological challenge, particularly in managing large tumors classified as T2 or T3 (2,6). Although partial nephrectomy (PN) has been the established approach for smaller tumors (T1), its role has expanded over recent years to include complex cases, even among larger and more intricate renal masses. Recent advances have broadened its role, extending PN to more complex cases, including larger and anatomically challenging renal masses. With the increasing usage of robot-assisted partial nephrectomy (RAPN), surgeons now have enhanced technical precision, which has allowed for the maintenance of renal function without compromising oncological outcomes in cases previously managed with more radical approaches (7–10).

The COVID-19 pandemic has further emphasized the need for minimally invasive procedures, as they may reduce hospital stays and facilitate faster recoveries, which are crucial in managing hospital resources and reducing patient exposure to infection risks (11–14). Additionally, artificial intelligence and 3D modeling are emerging as a powerful tool in surgical planning and outcomes prediction, offering insights that may enhance the precision of RAPN in managing complex renal tumors (15, p33,16). 3D model systems could support preoperative assessment and intraoperative decision-making, potentially further improving patient outcomes (17,18).

Given the evolving landscape of nephron-sparing surgery and ongoing improvements in robotic surgical techniques, this study aims to evaluate the safety, efficacy, and oncological outcomes of RAPN for cT2 and cT3 RCC (19–21). Specifically, it addresses the feasibility of RAPN in cases with extensive tumor characteristics where surgical precision and renal preservation are critical (22–26).

This systematic review aims to analyze current outcomes of RAPN specifically for larger and higher-stage renal tumors, focusing on its safety, efficacy, and potential advantages in managing cT2 and cT3 RCC.

MATERIALS AND METHODS

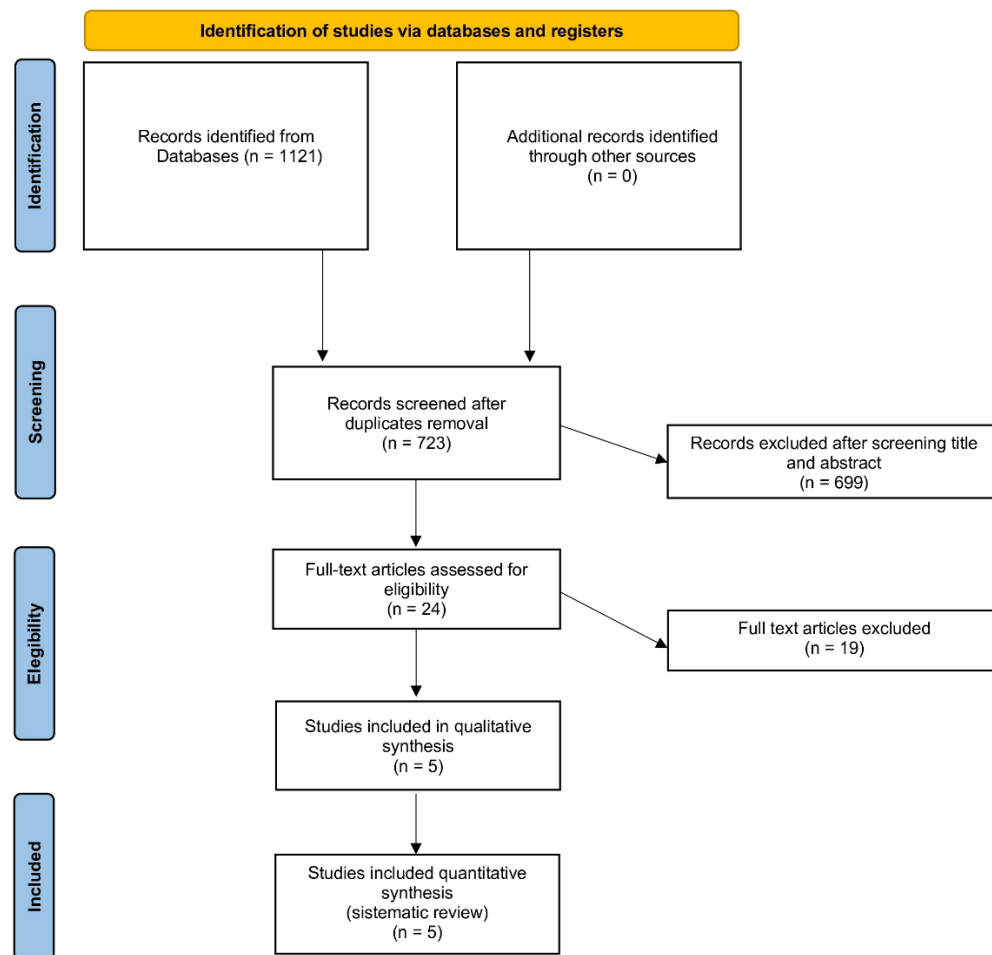
A literature review was conducted in August 2024 across the PubMed®, Scopus®, Web of Science®, ClinicalTrials.gov, and Cochrane Library® databases. The Preferred Reporting Items for Systematic Review and Meta-Analysis (PRISMA) guidelines were used to establish the selection criteria, design the search strategy, and report evidence (27–29). Search terms included patient- and intervention-specific keywords combined to form the following search string: ((T2 renal masses) OR (T3 renal masses) OR (large renal tumors) OR (advanced renal tumors) OR (complex kidney masses) OR (hilar tumors) OR (endophytic renal tumors) OR (high-risk renal tumors) OR (renal tumors >7 cm) OR (renal lesions >7 cm) OR (nephron-sparing surgery) OR (partial nephrectomy for large tumors)) AND ((robotic partial nephrectomy) OR (RAPN) OR (robot-assisted partial nephrectomy) OR (robotic kidney surgery) OR (robot-assisted surgery for renal masses) OR (minimally invasive partial nephrectomy)) NOT (radical nephrectomy).

Eligibility criteria were defined using the PICOS approach: (P) adults (≥ 18 years) diagnosed with RCC specifically with cT2 and cT3 renal masses; (I) those undergoing RAPN; (C) studies using OPN, LPN, or no comparator; (O) outcomes of interest included perioperative metrics (operative time, estimated blood loss, warm ischemia time, major complications, conversion rate), functional outcomes (eGFR preservation, CKD upstaging, Trifecta achievement), and oncologic results (positive surgical margin, recurrence, metastasis rates); (S) prospective or retrospective studies with a minimum sample size of 10 participants.

Exclusion criteria included: (1) animal or cadaveric model studies; (2) studies with fewer than 10 cases; and (3) non-original research, including editorials, meeting abstracts, case reports, letters, and grey literature, due to limited peer-reviewed details (30).

Research of the literature

The study selection process is illustrated in the PRISMA flow chart (Fig.1). The initial search yielded 1,121 studies, from which 394 duplicates were removed. After applying the selection criteria, 5 studies were included in this systematic review.



From: Page MJ, McKenzie JE, Bossuyt PM, Boutron I, Hoffmann TC, Mulrow CD, et al. The PRISMA 2020 statement: an updated guideline for reporting systematic reviews. *BMJ* 2021;372:n71. doi: 10.1136/bmj.n71

For more information, visit: <http://www.prisma-statement.org/>

Fig. 1. PRISMA 2020 flow diagram for new systematic reviews which included only searches of databases and registers.

These five retrospective studies, encompassing a total of 588 patients, provided outcome data specifically for renal masses classified as cT2-T3 (31–35). The quality of the included studies was assessed using the Newcastle-Ottawa Scale (36).

RESULTS

Five retrospective studies, including a total of 588 patients, reported outcomes for renal masses categorized as cT2-T3 (31–35) (Table I).

Table I. Robotic partial nephrectomy for T2-T3 tumors: pre- and post-operative outcomes.

Study	Year	Procedure (no. of cases)	Size CT (cm)	RENAL	OT (min)	EBL (ml)	WIT (min)	Major postop. complications*	PSM, No. (%)	Follow-Up, months	Recurrence, No.
Bertolo et al.	2018	≥ T2 RAPN (298)	7.6°	9°	150°	150°	25° 7.4% off-C	15	20	12°	25
Long et al.	2020	≥ T2 RAPN (16) LPN (7) RN (30)	8.1° 8°	[10-12] 68.8% 71.4% 83.3%	130° 140° 90°	100° 150° 25°	20 25.5	0 0 0	0 0 0	31.5 44 37	0 0 0
Yim et al.	2020	≥ cT3 (157)	7°	(10-12) 33.1%	190*	242*	19 * 20.4% off-C	7		7°	2
Morgan et al.	2021	≥ T3 RAPN and RVT (45)	4.3*	8.3*	199.6*	324. 9*	30.5*	7	3	28.5°	2
Beksac et al.	2022	≥ T2 SK RAPN (20) OPN (15)	5.8° 6°	9° 10°	258° 232°	325° 300°	27.3* 28.9*	2 5	3 3	21* 21*	2 1

abbreviations: RAPN - Robot-Assisted Partial Nephrectomy; LPN - Laparoscopic Partial Nephrectomy; OPN - Open Partial Nephrectomy; RN - Radical Nephrectomy; RSC - Retrospective Single-Center Study; RMC - Retrospective Multicenter Study; ND - National Database; PMC - Prospective Multicenter Study; CT - Computed Tomography; OT - Operative Time; EBL - Estimated Blood Loss; WIT - Warm Ischemia Time; PSM - Positive Surgical Margins; RVT - Renal Vein Thrombosis (*average; °median).

Morgan et al. concentrated on patients with renal vein thrombus (RVT) (34), whereas Beksac and colleagues specifically examined SK patients (33). Together, these studies offer valuable insights into the effectiveness of robotic partial nephrectomy for larger, complex renal tumors across diverse patient populations and clinical scenarios.

Mean tumor size ranged from 4.3 to 8.1. Notably, the smallest tumor size was classified as cT3 due to the presence of RVT, demonstrating the complexity criteria beyond just size. RENAL nephrometry varied with a range from 7 to 12 while age ranged from 53.5 to 64.9 years; OT recorded the maximum in the SK cohort with a value of 325 min. WIT ranged from 20 to 30.5 minutes. Off-clamp procedure was performed in 7.4 and 20.4% of Bertolo et al. (31) and Yim and colleagues (35) reports, respectively. EBL varied from a minimum of 100 to 325 ml.

Functional outcomes were evaluated considering eGFR variation (37). In the two series by Beksac et al. and Yim et al., eGFR was preserved at baseline values in 79.1% and 55.4% of cases at 1-year, respectively. Other authors reported a drop in eGFR at last follow-up ranging from 15.6 to 16.9. This difference in eGFR preservation across studies underscores the impact of patient selection and surgical technique on renal function outcomes. Oncological outcomes, in terms of PSM were reported from all series with a range between 0 and 8%. Authors reported a recurrence from 0 to 10%, and metastasis rates up to a maximum of 9.5%. Finally, only Yim et al. and Bertolo et al. reported trifecta achievement with a value of 64.3 and 49%, respectively (31,35), suggesting that achieving all desirable outcomes remains challenging in high-complexity cases.

DISCUSSION

Current clinical guidelines endorse a risk-adjusted approach when weighing the decision between PN and RN in challenging scenarios involving advanced RCC (38–41). Traditionally, large tumor size and higher stages, such as cT2 and cT3, presented substantial obstacles to nephron-sparing surgery (34,42–45). However, advancements in robotic surgical techniques have led to the inclusion of selected high-stage cases, allowing PN to be performed even in situations previously managed solely by RN. This shift in practice reflects an evolving view that tumor size alone should not disqualify patients from PN, particularly given the precision and minimally invasive advantages provided by robotic technology (46,47), which have expanded nephron-sparing options for complex renal tumors (48).

Despite these advancements, RN remains the benchmark treatment for cT2 RCC, especially for more complex and larger tumors where risks associated with incomplete tumor resection -PSM - and surgical complications are heightened (49). A large-scale analysis conducted by the ROSULA collaborative group highlights the outcomes of RAPN specifically for cT2 renal masses. The findings indicate that RAPN achieves acceptable WIT averaging 25 minutes, with an overall complication rate of 21%, of which around 5% are classified as major (31). While these complication rates exceed those seen with RAPN for smaller tumors, they remain lower than those documented for open partial nephrectomy in cT2

tumors (50). This underscores the viability of RAPN as an alternative to open-PN in high-stage cases where minimally invasive surgery is desirable (51,52).

Comparative studies further support RAPN's effectiveness in larger, high-stage RCC cases. For instance, Long et al. and Beksac et al. independently examined RAPN's performance in cases involving tumors larger than 7 cm. Long et al.'s series confirmed RAPN's feasibility and effectiveness for tumors exceeding this size threshold (32). Similarly, Beksac et al. demonstrated favorable outcomes in patients with a solitary kidney, a subgroup for whom preserving renal function is critical (33). In these patients, RAPN achieved outcomes comparable to open-PN, highlighting the flexibility of RAPN even in complex anatomical scenarios or where preserving remaining renal function is paramount (8).

For cases classified as T3a RCC—characterized by invasion into the renal vein or its branches, perirenal sinus fat, or renal calyces—the disease is considered locally advanced and is typically associated with poorer survival outcomes compared to T1 and T2 RCC. (53). Managing T3a tumors involves additional technical challenges due to concerns around achieving negative surgical margins and potentially extended clamping times, which can affect postoperative renal function (54). Despite these complexities, Yim et al. conducted a multi-institutional analysis and found that RAPN outcomes for larger and higher-stage tumors (T2 and T3) were comparable in terms of PSM and complication rates to those seen in lower-stage tumors. Furthermore, this study showed that preservation of eGFR and survival outcomes for RAPN in T3a tumors were similar to those achieved with open-PN, supporting RAPN's potential as a viable surgical alternative in advanced disease cases (35).

A promising advancement in this field is the integration of automatic 3D augmented reality for intraoperative guidance in RAPN, as recently explored (55). The automatically overlaid 3D virtual models onto the surgical field could enhance the surgeon's ability to visualize and precisely target the tumor while preserving healthy tissue. This technology not only aims to enhance surgical accuracy but also aligns with the goals of "Precision Surgery," reducing the surgical impact on patients' overall health.

In a subset of patients with renal vein thrombus (RVT), considered a high-risk factor for RCC progression, Morgan and colleagues examined the feasibility of RAPN (34). Their findings suggest that RVT is not an absolute contraindication for RAPN. For carefully selected pT3a RCC patients, RAPN emerged as an effective treatment option, highlighting that even in cases with venous involvement, nephron-sparing surgery can be both feasible and oncologically appropriate.

In a recent review and meta-analysis, Garg et al. assessed robotic-assisted nephrectomy with inferior vena cava thrombectomy (R-CT) and included 28 studies encompassing a total of 1,375 patients. The review highlights R-CT's potential to achieve oncological control similar to open surgery while offering reduced EBL transfusion rates, and complication rates. However, this technique's success is highly dependent on surgeon experience, as managing IVC thrombus increases procedural complexity. Patient selection is crucial, particularly for those with advanced RCC stages (e.g., pT3a with IVC thrombus), to balance safety and effectiveness (56). The findings suggest that R-CT, when appropriately applied, can broaden treatment options for high-risk patients, allowing for less invasive management with favorable perioperative outcomes and that, under experienced hands, RAPN can be applied flexibly in more advanced RCC cases, extending its utility to high-complexity patients where nephron preservation is a priority.

Chen et al. also explored advanced treatment strategies for RCC cases with vascular invasion, focusing on neoadjuvant stereotactic ablative body radiotherapy (SABR) for RCC with IVC tumor thrombus. Their study demonstrated that SABR could effectively control local disease and reduce surgical complexity by minimizing the extent of vascular invasion. This approach, while not directly analogous to RAPN, supports the idea that innovative techniques, such as SABR or RAPN in selected patients, can safely expand treatment options for high-complexity RCC cases (57–59).

Moreover, Chen et al.'s study observed no severe complications with SABR, reinforcing that with careful application, modern interventions can mitigate the challenges associated with complex RCC surgeries. Together, these findings underscore the potential for RAPN, augmented by strategies like SABR in selected cases, to offer more tailored, less invasive options for patients previously managed with radical surgery alone (60,61).

LIMITATIONS

This systematic review has several limitations. First, the analysis relies solely on five retrospective studies, which may introduce selection bias and limit the generalizability of findings. Additionally, the variability in study design, including differences in sample sizes, surgical techniques, and institutional protocols, can affect the comparability of results. There was also a limited amount of data specifically for cT3 tumors, and outcomes for this stage may not be as robustly supported as those for cT2. Furthermore, due to the observational nature of included studies, controlling the surgical experience and expertise of the surgeons was challenging; both factors are crucial for outcomes in complex cases such as those involving T2-T3 RCC. Lastly, there was a lack of long-term oncological follow-up across the studies, which restricts conclusions on the durability of RAPN in high-stage RCC.

CONCLUSIONS

This review highlights the expanding role of RAPN as a nephron-sparing alternative for managing complex renal masses in advanced RCC cases, specifically cT2 and cT3 stages. The data suggests that, in experienced hands, RAPN can provide acceptable functional and oncological outcomes, including in those challenging cases. Although RAPN exhibits higher perioperative risks than its application in smaller tumors, it generally offers favorable outcomes when compared with traditional open approaches for high-stage tumors. Future studies, ideally prospective and randomized, are needed to further define RAPN's efficacy and safety for high-risk RCC cases and to better standardize protocols across institutions.

Acknowledgements

None

Funding

None

Conflict of interest

The authors declare that they have no conflict of interest.

REFERENCES

1. Bukavina L, Bensalah K, Bray F, et al. Epidemiology of Renal Cell Carcinoma: 2022 Update. *Eur Urol.* 2022;82(5):529-542. doi:10.1016/j.eururo.2022.08.019
2. Ljungberg B, Bensalah K, Canfield S, et al. EAU guidelines on renal cell carcinoma: 2014 update. *Eur Urol.* 2015;67(5):913-924. doi:10.1016/j.eururo.2015.01.005
3. Milella M, Rutigliano M, Lasorsa F, et al. The Role of MUC1 in Renal Cell Carcinoma. *Biomolecules.* 2024;14(3). doi:10.3390/biom14030315
4. Scapoli L, Avantaggiato A, Khater AGA. Influence of hyaluronic acid on extracellular matrix produced by mesenchymal stem cells. *Eur J Musculoskelet Dis.* 2022;11(1):1-9.
5. Diagnostic Accuracy and Risks of Biopsy in the Diagnosis of a Renal Mass Suspicious for Localized Renal Cell Carcinoma: Systematic Review of the Literature - PubMed. Accessed April 23, 2024. <https://pubmed.ncbi.nlm.nih.gov/26901507/>
6. Campbell SC, Clark PE, Chang SS, Karam JA, Souter L, Uzzo RG. Renal Mass and Localized Renal Cancer: Evaluation, Management, and Follow-Up: AUA Guideline: Part I. *J Urol.* 2021;206(2):199-208. doi:10.1097/JU.0000000000001911
7. Campbell S, Uzzo RG, Allaf ME, et al. Renal Mass and Localized Renal Cancer: AUA Guideline. *J Urol.* 2017;198(3):520-529. doi:10.1016/j.juro.2017.04.100
8. Pandolfo SD, Wu Z, Campi R, et al. Outcomes and Techniques of Robotic-Assisted Partial Nephrectomy (RAPN) for Renal Hilar Masses: A Comprehensive Systematic Review. *Cancers.* 2024;16(4):693. doi:10.3390/cancers16040693
9. Autorino R, Khalifeh A, Laydner H, et al. Robot-assisted partial nephrectomy (RAPN) for completely endophytic renal masses: a single institution experience. *BJU Int.* 2014;113(5):762-768. doi:10.1111/bju.12455
10. Lu SY, Chung HJ, Huang EYH, Lin TP, Lin ATL. The perioperative outcomes between renal hilar and non-hilar tumors following robotic-assisted partial nephrectomy (RAPN). *J Chin Med Assoc JCMA.* 2018;81(8):676-681. doi:10.1016/j.jcma.2017.11.014
11. Moretti L, Bizzoca D, Vitale E, et al. Gender and socio-economic issues in the clinical assessment of orthopaedic patients during the covid-19 pandemic. *Eur J Musculoskelet Dis.* 2022;11(1):15-21.
12. Narain TA, Gautam G, Seth A, et al. Uro-oncology in times of COVID-19: The available evidence and recommendations in the Indian scenario. *Indian J Cancer.* 2020;57(2):129-138. doi:10.4103/ijc.IJC_356_20
13. Pitts CC, Levitt EB, Patch DA, et al. Ankle Fracture and Length of Stay in US Adult Population Using Data From the National COVID Cohort Collaborative. *Foot Ankle Orthop.* 2022;7(1):24730114221077282. doi:10.1177/24730114221077282
14. Minervini G, Romano A, Petrucci M, et al. Oral-facial-digital syndrome (OFD): 31-year follow-up management and monitoring. *J Biol Regul Homeost Agents.* 2018;32(2 Suppl. 1):127-130.

15. Grosso AA, Di Maida F, Tellini R, et al. Robot-assisted partial nephrectomy with 3D preoperative surgical planning: video presentation of the florentine experience. *Int Braz J Urol.* 2021;47(6):1272-1273. doi:10.1590/S1677-5538.IBJU.2020.1075
16. Wang C, Komninos C, Andersen S, et al. Ultrasound 3D reconstruction of malignant masses in robotic-assisted partial nephrectomy using the PAF rail system: a comparison study. *Int J Comput Assist Radiol Surg.* 2020;15(7):1147-1155. doi:10.1007/s11548-020-02149-4
17. Alshadidi AAF, Alshahrani AA, Aldosari LIN, et al. Investigation on the Application of Artificial Intelligence in Prosthodontics. *Appl Sci Switz.* 2023;13(8). doi:10.3390/app13085004
18. Moglia A, Georgiou K, Georgiou E, Satava RM, Cuschieri A. A systematic review on artificial intelligence in robot-assisted surgery. *Int J Surg Lond Engl.* 2021;95:106151. doi:10.1016/j.ijso.2021.106151
19. Antonelli A, Mari A, Tafuri A, et al. Prediction of significant renal function decline after open, laparoscopic, and robotic partial nephrectomy: External validation of the Martini's nomogram on the RECORD2 project cohort. *Int J Urol Off J Jpn Urol Assoc.* 2022;29(6):525-532. doi:10.1111/iju.14831
20. Benway BM, Bhayani SB, Rogers CG, et al. Robot assisted partial nephrectomy versus laparoscopic partial nephrectomy for renal tumors: a multi-institutional analysis of perioperative outcomes. *J Urol.* 2009;182(3):866-872. doi:10.1016/j.juro.2009.05.037
21. Kim DK, Kim LHC, Raheem AA, et al. Comparison of Trifecta and Pentafecta Outcomes between T1a and T1b Renal Masses following Robot-Assisted Partial Nephrectomy (RAPN) with Minimum One Year Follow Up: Can RAPN for T1b Renal Masses Be Feasible? *PloS One.* 2016;11(3):e0151738. doi:10.1371/journal.pone.0151738
22. Zeuschner P, Greguletz L, Meyer I, et al. Open versus robot-assisted partial nephrectomy: A longitudinal comparison of 880 patients over 10 years. *Int J Med Robot Comput Assist Surg MRCAS.* 2021;17(1):1-8. doi:10.1002/rcs.2167
23. Brassetti A, Anceschi U, Bertolo R, et al. Surgical quality, cancer control and functional preservation: introducing a novel trifecta for robot-assisted partial nephrectomy. *Minerva Urol E Nefrol Ital J Urol Nephrol.* 2020;72(1):82-90. doi:10.23736/S0393-2249.19.03570-7
24. Kobayashi S, Cho B, Mutaguchi J, et al. Surgical Navigation Improves Renal Parenchyma Volume Preservation in Robot-Assisted Partial Nephrectomy: A Propensity Score Matched Comparative Analysis. *J Urol.* 2020;204(1):149-156. doi:10.1097/JU.0000000000000709
25. Saitta C, Afari JA, Autorino R, et al. Development of a novel score (RENSAFE) to determine probability of acute kidney injury and renal functional decline post surgery: A multicenter analysis. *Urol Oncol.* Published online October 23, 2023:S1078-1439(23)00330-7. doi:10.1016/j.urolonc.2023.09.015
26. Flammia RS, Anceschi U, Tuderti G, et al. Development and internal validation of a nomogram predicting 3-year chronic kidney disease upstaging following robot-assisted partial nephrectomy. *Int Urol Nephrol.* Published online October 17, 2023. doi:10.1007/s11255-023-03832-6
27. Bernardo WM. PRISMA statement and PROSPERO. *Int Braz J Urol Off J Braz Soc Urol.* 2017;43(3):383-384. doi:10.1590/S1677-5538.IBJU.2017.03.02
28. Page MJ, McKenzie JE, Bossuyt PM, et al. The PRISMA 2020 statement: An updated guideline for reporting systematic reviews. *J Clin Epidemiol.* 2021;134:178-189. doi:10.1016/j.jclinepi.2021.03.001
29. Moher D, Shamseer L, Clarke M, et al. Preferred reporting items for systematic review and meta-analysis protocols (PRISMA-P) 2015 statement. *Syst Rev.* 2015;4(1):1. doi:10.1186/2046-4053-4-1
30. Methley AM, Campbell S, Chew-Graham C, McNally R, Cheraghi-Sohi S. PICO, PICOS and SPIDER: a comparison study of specificity and sensitivity in three search tools for qualitative systematic reviews. *BMC Health Serv Res.* 2014;14:579. doi:10.1186/s12913-014-0579-0
31. Bertolo R, Autorino R, Simone G, et al. Outcomes of Robot-assisted Partial Nephrectomy for Clinical T2 Renal Tumors: A Multicenter Analysis (ROSULA Collaborative Group). *Eur Urol.* 2018;74(2):226-232. doi:10.1016/j.eururo.2018.05.004
32. Long G, Liu M, Zhang Y, et al. Robot-assisted laparoscopic partial nephrectomy is a safe and effective option for clinical T2 renal cell carcinoma: a case-series from single-institution. *Transl Cancer Res.* 2020;9(11):7140-7148. doi:10.21037/tcr-20-2324

33. Beksac AT, Okhawere KE, Abou Zeinab M, et al. Robotic partial nephrectomy for management of renal mass in patients with a solitary kidney: can we expand the indication to T2 and T3 disease? *Minerva Urol Nephrol.* 2022;74(2):203-208. doi:10.23736/S2724-6051.22.04671-7
34. Morgan TN, Dai JC, Kusin S, et al. Clinical Outcomes of Robotic Assisted Partial Nephrectomy for Pathologic T3a Renal Masses With Venous Tumor Thrombus. *Urology.* 2022;159:120-126. doi:10.1016/j.urology.2021.06.054
35. Yim K, Aron M, Rha KH, et al. Outcomes of Robot-assisted Partial Nephrectomy for Clinical T3a Renal Masses: A Multicenter Analysis. *Eur Urol Focus.* 2021;7(5):1107-1114. doi:10.1016/j.euf.2020.10.011
36. Wells GA, Shea B, O'Connell D, et al. The Newcastle-Ottawa Scale (NOS) for assessing the quality of nonrandomised studies in meta-analyses. Published online 2000.
37. Crocerossa F, Fiori C, Capitanio U, et al. Estimated Glomerular Filtration Rate Decline at 1 Year After Minimally Invasive Partial Nephrectomy: A Multimodel Comparison of Predictors. *Eur Urol Open Sci.* 2022;38:52-59. doi:10.1016/j.euros.2022.02.005
38. Cerrato C, Meagher MF, Autorino R, et al. Partial versus radical nephrectomy for complex renal mass: multicenter comparative analysis of functional outcomes (Rosula collaborative group). *Minerva Urol Nephrol.* 2023;75(4):425-433. doi:10.23736/S2724-6051.23.05123-6
39. Cerrato C, Patel D, Autorino R, et al. Partial or radical nephrectomy for complex renal mass: a comparative analysis of oncological outcomes and complications from the ROSULA (Robotic Surgery for Large Renal Mass) Collaborative Group. *World J Urol.* 2023;41(3):747-755. doi:10.1007/s00345-023-04279-1
40. Azizi M, Sadeghi M, Amirian F, Mohammadi K, Ramezani M. Huge Papillary Renal Cell Carcinoma with Extension to the Inferior Vena Cava: A Case Report. *Biomed Res Ther.* 2022;9(8):5196-5200. doi:10.15419/bmrat.v9i8.756
41. Andrade HS, Zargar H, Caputo PA, et al. Five-year Oncologic Outcomes After Transperitoneal Robotic Partial Nephrectomy for Renal Cell Carcinoma. *Eur Urol.* 2016;69(6):1149-1154. doi:10.1016/j.eururo.2015.12.004
42. Pandolfo SD, Cerrato C, Wu Z, et al. A systematic review of robotic partial nephrectomy outcomes for advanced indications: Large (cT2-T3), solitary kidney, completely endophytic, hilar, recurrent, and multiple renal tumors. *Asian J Urol.* Published online August 1, 2023. doi:10.1016/j.ajur.2023.06.001
43. Nandan N, Vecchia A, Antonelli A, et al. Outcomes and predictors of benign histology in patients undergoing robotic partial or radical nephrectomy for renal masses: a multicenter study. *Cent Eur J Urol.* 2020;73(1):33-38. doi:10.5173/ceju.2020.0019
44. Arora S, Chun B, Ahlawat RK, et al. Conversion of Robot-assisted Partial Nephrectomy to Radical Nephrectomy: A Prospective Multi-institutional Study. *Urology.* 2018;113:85-90. doi:10.1016/j.urology.2017.11.046
45. Ashrafi AN, Gill IS. Minimally invasive radical nephrectomy: a contemporary review. *Transl Androl Urol.* 2020;9(6):3112-3122. doi:10.21037/tau-2019-suc-16
46. Lasorsa F, Bignante G, Orsini A, et al. Partial nephrectomy in elderly patients: a systematic review and analysis of comparative outcomes. *Eur J Surg Oncol.* 2024;50(10). doi:10.1016/j.ejso.2024.108578
47. Grob G, Rogers D, Pandolfo SD, et al. Oncologic outcomes following radical nephroureterectomy for upper tract urothelial carcinoma: a literature review. *Transl Androl Urol.* 2023;12(8):1351-1362. doi:10.21037/tau-22-882
48. Azhar RA, Gill IS, Aron M. Robotic nephron-sparing surgery for renal tumors: Current status. *Indian J Urol IJU J Urol Soc India.* 2014;30(3):275-282. doi:10.4103/0970-1591.135667
49. Baheen Q, Liu Z, Hao Y, et al. The Significant Role of Tumor Volume on the Surgical Approach Choice, Surgical Complexity, and Postoperative Complications in Renal Cell Carcinoma With Venous Tumor Thrombus From a Large Chinese Center Experience. *Front Oncol.* 2022;12:869891. doi:10.3389/fonc.2022.869891
50. Ficarra V, Bhayani S, Porter J, et al. Robot-assisted partial nephrectomy for renal tumors larger than 4 cm: results of a multicenter, international series. *World J Urol.* 2012;30(5):665-670. doi:10.1007/s00345-012-0943-9
51. Porpiglia F, Mari A, Bertolo R, et al. Partial Nephrectomy in Clinical T1b Renal Tumors: Multicenter Comparative Study of Open, Laparoscopic and Robot-assisted Approach (the RECORD Project). *Urology.* 2016;89:45-51. doi:10.1016/j.urology.2015.08.049
52. Malkoc E, Ramirez D, Kara O, et al. Robotic and open partial nephrectomy for localized renal tumors larger than 7 cm: a single-center experience. *World J Urol.* 2017;35(5):781-787. doi:10.1007/s00345-016-1937-9

53. Paner GP, Stadler WM, Hansel DE, Montironi R, Lin DW, Amin MB. Updates in the Eighth Edition of the Tumor-Node-Metastasis Staging Classification for Urologic Cancers. *Eur Urol*. 2018;73(4):560-569. doi:10.1016/j.eururo.2017.12.018
54. Russell CM, Lebastchi AH, Chipollini J, et al. Multi-institutional Survival Analysis of Incidental Pathologic T3a Upstaging in Clinical T1 Renal Cell Carcinoma Following Partial Nephrectomy. *Urology*. 2018;117:95-100. doi:10.1016/j.urology.2018.04.002
55. Amparore D, Pecoraro A, Checcucci E, et al. 3D imaging technologies in minimally invasive kidney and prostate cancer surgery: which is the urologists' perception? *Minerva Urol Nephrol*. 2022;74(2):178-185. doi:10.23736/S2724-6051.21.04131-X
56. Garg H, Psutka SP, Hakimi AA, et al. A Decade of Robotic-Assisted Radical Nephrectomy with Inferior Vena Cava Thrombectomy: A Systematic Review and Meta-Analysis of Perioperative Outcomes. *J Urol*. 2022;208(3):542-560. doi:10.1097/JU.0000000000002829
57. Chen J, Liu Z, Peng R, et al. Neoadjuvant stereotactic ablative body radiotherapy combined with surgical treatment for renal cell carcinoma and inferior vena cava tumor thrombus: a prospective pilot study. *BMC Urol*. 2024;24:31. doi:10.1186/s12894-024-01405-y
58. M L, A S, W K, et al. Transitional cell carcinoma with extension of the renal vein and IVC tumor thrombus: report of three cases and literature review. *World J Surg Oncol*. 2016;14(1). doi:10.1186/s12957-016-1041-z
59. Wu Z, Chen H, Chen Q, et al. Prognostic Significance of Grade Discrepancy Between Primary Tumor and Venous Thrombus in Nonmetastatic Clear-cell Renal Cell Carcinoma: Analysis of the REMEMBER Registry and Implications for Adjuvant Therapy. *Eur Urol Oncol*. Published online July 17, 2023:S2588-9311(23)00119-0. doi:10.1016/j.euo.2023.06.006
60. Margulis V, Freifeld Y, Pop LM, et al. Neoadjuvant SABR for Renal Cell Carcinoma Inferior Vena Cava Tumor Thrombus-Safety Lead-in Results of a Phase 2 Trial. *Int J Radiat Oncol Biol Phys*. 2021;110(4):1135-1142. doi:10.1016/j.ijrobp.2021.01.054
61. Bignante G, Orsini A, Lasorsa F, et al. PRobotic-assisted surgery for the treatment of urologic cancers: recent advances. *Expert Rev Med Devices*. 2024:1-13. doi: 10.1080/17434440.2024.2435546



ROBOT-ASSISTED PARTIAL NEPHRECTOMY IN MANAGING COMPLETELY ENDOPHYTIC RENAL TUMORS: A SYSTEMATIC REVIEW

G. Spena¹, A. Izzo¹, F. Passaro¹, G. Villano², F. Capone², U. Amicuzi², P. Conforti², E. Sicignano³, V. Iossa³, S. Cilio⁴, C. Giulioni⁵, A. Cafarelli⁵ and A. Aveta^{6*}

¹ Department of Urology, Istituto Nazionale Tumori, IRCCS, "Fondazione G. Pascale", Naples, Italy;

² Department of Neuroscience, Reproductive Sciences and Odontostomatology, University of Naples "Federico II", Naples, Italy;

³ Urology Unit, Moscati Hospital, Avellino, Italy;

⁴ Department of Medicine and Surgery, Scuola Medica Salernitana, University of Salerno, Fisciano, Italy;

⁵ Urology Unit, Casa di Cura Villa Igea, Ancona, Italy;

⁶ Department of Urology, Ospedale del Mare, ASL Napoli 1 Centro, Naples, Italy.

*Correspondence to:

Achille Aveta,

Department of Urology,

Ospedale del Mare,

ASL Napoli 1 Centro,

Naples, Italy.

e-mail: achille-aveta@hotmail.it

ABSTRACT

Renal cell carcinoma (RCC) is a major health concern globally, with numerous new cases each year in the United States. Partial nephrectomy (PN) is central to managing both small (cT1) and complex larger (cT2) renal tumors. The advancement of robot-assisted partial nephrectomy (RAPN) has broadened its application, particularly for completely endophytic renal tumors—lesions fully enclosed within kidney parenchyma, presenting unique challenges due to their lack of visible landmarks. This systematic review analyzed over 1,545 patients, to evaluate RAPN outcomes for endophytic tumors. Results demonstrated that RAPN achieves comparable oncological and functional outcomes to OPN, with reduced blood loss, shorter operative time, and enhanced margin control. The use of intraoperative ultrasound further improved outcomes, aiding tumor localization and precision.

KEYWORDS: *Renal cell carcinoma, robot-assisted partial nephrectomy, RAPN, endophytic renal tumors, nephron-sparing surgery, intraoperative ultrasound*

INTRODUCTION

Renal cell carcinoma (RCC) represents a significant health concern, with high incidence rates globally, including thousands of new cases in the United States each year (1,2). Emerging research highlights the significance of specific biomarkers in the pathogenesis of RCC (3–5). In managing small renal masses (cT1) and more complex, larger tumors (cT2), partial nephrectomy (PN) has established itself as a cornerstone treatment (6,7).

The rapid advancement of robot-assisted partial nephrectomy (RAPN) has broadened the indications for treating entirely endophytic masses, offering a safe and effective alternative, especially in high-volume robotic centers (8–11).

Received: 13 September, 2024

Accepted: 17 December, 2024

ISSN 2038-4106 print

ISSN 2975-044X online Copyright © by BIOLIFE 2024

This publication and/or article is for individual use only and may not be further reproduced without written permission from the copyright holder. Unauthorized reproduction may result in financial and other penalties. Disclosure: All authors report no conflicts of interest relevant to this article.

Completely endophytic renal tumors present a significant surgical challenge due to their entirely intraparenchymal location, which complicates intraoperative identification and resection (12). Without external visual cues, their localization often relies on advanced technologies like intraoperative ultrasound, particularly in minimally invasive procedures. A completely endophytic mass is defined as a renal tumor entirely located within the kidney parenchyma, without any external or exophytic component visible on the surface. According to the R.E.N.A.L. nephrometry scoring system, these tumors are assigned a score of 3 for the "E" (endophytic/exophytic) component, indicating their fully intraparenchymal position (13). Endophytic tumors are often amenable to treatment with percutaneous ablation techniques (14–17). Traditionally, these tumors were managed with open partial nephrectomy (OPN), which provides tactile feedback and direct spatial access, facilitating hemostasis control (18). However, robotic surgery has enabled a minimally invasive approach for these complex cases, achieving comparable oncological and functional outcomes to OPN, even for high-complexity tumors (19–21). Overall, robotic surgery has significantly boosted interest in urological surgery, enabling surgeons to tackle complex cases with precision and minimally invasive techniques (22–26).

Given the ongoing advancements in surgical techniques and accumulating evidence, our study focuses specifically on evaluating the outcomes of RAPN for highly challenging cases of completely endophytic renal tumors.

MATERIALS AND METHODS

This systematic review of the literature was conducted in January 2024 using the PubMed, Scopus, Web of Science, and Cochrane Library databases (MEDLINE, EMBASE, and Web of Science databases). The search strategy, selection criteria, and reporting process adhered to the Preferred Reporting Items for Systematic Review and Meta-Analysis (PRISMA) guidelines. To specifically focus on endophytic renal tumors treated with robotic partial nephrectomy (RAPN), patient- and intervention-related terms were combined to form the following search string: ((robotic partial nephrectomy) OR (RAPN) OR (robot-assisted partial nephrectomy) OR (robot-assisted surgery) OR (robotic surgery) OR (nephron-sparing surgery) OR (minimally invasive partial nephrectomy) OR (robotic-assisted kidney surgery) OR (kidney-sparing surgery) OR (robotic-assisted nephron-sparing) OR (partial kidney resection)) AND ((endophytic) OR (completely intrarenal) OR (fully intraparenchymal) OR (RENAL score 3 E) OR (intraparenchymal renal tumors) OR (internal kidney tumors) OR (entirely intrarenal masses) OR (central kidney tumors) OR (renal masses without exophytic component) OR (complex renal tumors)).

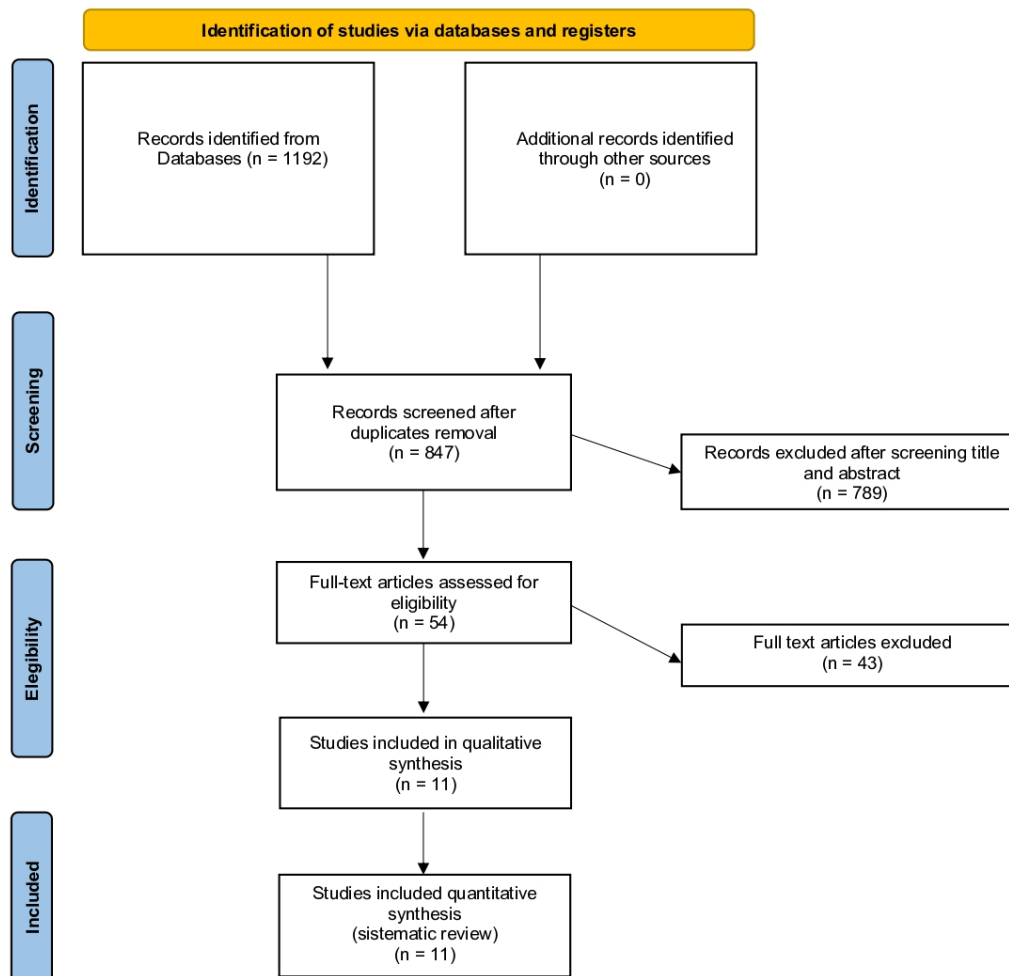
The search results were refined by language (English), species (human), and publication type (article). Eligibility criteria were defined using the PICOS (Patient, Intervention, Comparator, Outcome, Study type) framework as follows: (P) Adult patients (≥ 18 years) diagnosed with renal cell carcinoma (RCC) with fully endophytic tumors; (I) Patients undergoing RAPN; (C) Comparison with OPN, LPN, or no comparator; (O) Relevant outcomes included perioperative parameters (operative time, estimated blood loss, warm ischemia time, major complication rate, conversion rate), functional outcomes (eGFR preservation, CKD progression, Trifecta achievement), and oncological outcomes (positive surgical margins, recurrence rate, metastasis rate); (S) Retrospective or prospective comparative studies with a minimum cohort size of 10 patients.

Exclusion criteria encompassed studies on animal or cadaver models, studies with very small sample sizes, and non-original research formats such as editorials, conference abstracts, case reports, letters to the editor, or grey literature, as these often lack detail and peer review.

SEARCH RESULTS

The search initially identified 1,192 studies. Of these, 349 were duplicate. Overall, 11 studies which included more than 1,545 patients, were included in the systematic review (19,20,27–35).

The PRISMA flow chart of the study selection process is shown in Figure 1 (Fig.1). Quality assessment of the included studies has been evaluated with the Newcastle-Ottawa Scale (36).



From: Page MJ, McKenzie JE, Bossuyt PM, Boutron I, Hoffmann TC, Mulrow CD, et al. The PRISMA 2020 statement: an updated guideline for reporting systematic reviews. *BMJ* 2021;372:n71. doi: 10.1136/bmj.n71

For more information, visit: <http://www.prisma-statement.org/>

Fig. 1. PRISMA 2020 flow diagram for new systematic reviews which included searches of only databases and registers.

RESULTS

Data on completely endophytic renal masses were reported in eleven studies, encompassing a total of 1,545 patients (19,20,27–35) (Table I,II). All the studies had a retrospective design. Among those, two studies, including 232 patients, compared RAPN to OPN (4,7), and only one paper, with 112 patients, to LPS (33).

The average age of the patients ranged between 47.3 and 68 years, while the mean tumor size varied from 1.9 to 4.1 cm. RENAL nephrometry varied widely if we consider also comparative studies of mesophytic and exophytic lesions with a range from 4 to 10; when considering endophytic mass only, the minimum moves to 8.3. OT recorded ranges from 105 to 201 min, with this maximum value recorded in the cohort which employed intraoperative ultrasound, in Sun et al. series (29).

A wide range for EBL was recorded, from 50 to 300 ml. Warm ischemia was employed in all series and its value ranged from 13 to 25.6 min. Longer follow-ups have been recorded for studies of Raheem et al. and Komninos et al., with median periods of 59 and 48 months, respectively (Table I) (28,35). Functional outcomes were evaluated as the latest eGFR percentage change with values from -4.5 to -16 ml/min. Oncological outcomes, in terms of PSM were reported from all series, with a range between 0 and 6, while recurrence and metastasis rates were not regularly reported. However, both recorded values from 0 to 3. Finally, only five studies reported trifecta (or pentafecta) achievement with values from 39 to 75% (Table II) (27,30,32,33,35).

Table I. Summary of reported studies: baseline characteristics and perioperative outcomes of robotic partial nephrectomy for endophytic renal tumors.

Study	Procedure (no of case)	Size CT (cm)	RENAL	OT (min)	EBL (ml)	WIT (min), Median	PSM, No. (%)
Autorino 2014	RAPN (389) Exophytic (179) Mesophytic (145) Endophytic (65)	3.7, 3.3, 2.6	6.4, 7.6, 8.7	186.7, 189.8, 175.8	287, 244, 225.8	17.1, 20.2, 21.7	4 (2.2), 5 (3.5), 3 (4.6)
Komminos 2014	RAPN Exophytic (45) Mesophytic (116) Endophytic (64)	2.5, 3.4, 2.6	5, 8, 9	143, 175, 169	200, 300, 275	21, 24, 24	1 (2.1), 4 (4), 5 (12.5)
Curtiss 2015	RAPN (297) Meso-Exophytic (267) Endophytic (30)	2.7, 2.3	6, 9	162, 165	100, 100	17, 17	5 (2.4), 0 (0)
Kara 2016	RAPN (87), OPN (56)	2.8, 3.1	9, 9	185, 206	175, 341	24, 20.6	4 (5.4), 4 (8.7)
Raheem 2018	RAPN (52), OPN (37)	2.8, 2.5	8.9, 8.3	170, 161	300, 200	24, 27	5 (9.6), 3 (8.1)
Harke 2018	RAPN (64), OPN (76)	2.6, 2.5	-	169, 140	-	13, 18	-
Sun 2020	RAPN (55), IOUS (38), no IOUS (20)	2.9, 3.2	-	201.2, 189.8	144.7, 257.5	20.4, 25.6	3 (7.9), 3 (15)
Carbonara 2020	RAPN (970) Exophytic (510) Mesophytic (313) Endophytic (147)	3.2, 4.1, 2.4	4, 8, 10	155.7, 163.4, 178.5	130, 185.5, 177	16, 21, 22	18 (3.9), 11 (3.7), 6 (4.5)
Gu 2020	RAPN (61), LPN (51)	2.3, 2.5	-	105, 108	50	20, 20	2 (3.3), 1 (2)
Minoda 2021	RAPN (144) Enucleation (72) Resection (72)	2.6	9	151, 140, 167	78, 56, 86	23, 21	4 (2.8), 3 (6.7), 1 (2.2)
Motoyama 2022	RAPN (265) Exophytic (127) Mesophytic (112) Endophytic (26)	2.9, 2.3, 1.9	6, 8, 9	178, 168, 172	55, 44, 51	13, 13, 16	1 (0.8), 1 (0.9), 0 (0)

Abbreviations: RAPN - Robot-Assisted Partial Nephrectomy; LPN - Laparoscopic Partial Nephrectomy; OPN - Open Partial Nephrectomy; CT - Computed Tomography; OT - Operative Time; EBL - Estimated Blood Loss; WIT - Warm Ischemia Time; PSM - Positive Surgical Margins; IOUS - Intraoperative Ultrasound.

Table II. Summary of postoperative outcomes for robotic partial nephrectomy in endophytic renal tumors – review of reported studies.

Study	Follow-Up, months	Latest eGFR Change (%)	Major Postop. Complications*	Tri/Pentafecta Achievement, No. (%)
Autorino 2014	14.5, 15.7, 12.6	-6.5, -11.7, -9.4	3 (1.7), 7 (4.8), 1 (1.4)	96 (53.6), 86 (59.3), 39 (60)
Komninos 2014	38, 43, 48	-1, -3, -4.5	2 (3), 0 (0), 2 (4.4)	38 (16-63), 43 (15-54), 48 (20-59)
Curtiss 2015	-	-	9 (3.4), 0 (0)	-
Kara 2016	15.2, 18	-	18 (20.7), 20 (35.7)	-
Raheem 2018	59, 53	-11, -8	2 (3.8), 1 (2.7)	-
Harke 2018	-	-	-	(75), (68.4)
Sun 2020	-	-6.4, -9.9	1 (2.6), 0 (0)	-
Carbonara 2020	32.3, 27.8, 21.6	-5.5, -9.6, -10.8	32.3 (25.4), 27.8 (43), 21.6 (20)	234 (68.8), 114 (50.9), 44 (45.4)
Gu 2020	-	-9.8, -10.6	2 (3.2), 0 (0)	26 (42.6), 19 (37.3)
Minoda 2021	-	-6.6, -4.9, -16	4 (2.8), 3 (4.3), 1 (1.4)	-
Motoyama 2022	-	-	3 (2.4), 2 (1.8), 2 (7.7)	-

Abbreviations: RAPN - Robot-Assisted Partial Nephrectomy; LPN - Laparoscopic Partial Nephrectomy; OPN - Open Partial Nephrectomy; CT - Computed Tomography; OT - Operative Time; eGFR - Estimated Glomerular Filtration Rate; IOUS - Intraoperative Ultrasound.

DISCUSSION

RAPN has increasingly become the preferred approach for challenging tumors, including entirely endophytic ones, which are defined as lesions fully encapsulated by healthy kidney parenchyma (14,30). While a standardized definition is lacking, most studies classify an endophytic mass as having a score of 3 in the “E” domain of the RENAL nephrometry score, generally describing these lesions as being entirely surrounded by healthy renal parenchyma (14,20). All studies describe a fully endophytic lesion as a challenging case, primarily because the lack of external clues makes precise tumor localization difficult, and the extensive contact area between the tumor and healthy parenchyma further complicates the procedure (35). These factors can complicate accurate tumor localization, increase the risk of vascular injury, and necessitate more complex parenchymal reconstruction, potentially impacting perioperative and oncological outcomes as well as renal function preservation (37,38, pp3-). The first single-center study comparing endophytic, mesophytic, and exophytic masses in RAPN was reported by Autorino et al. (30). Since that time, three additional single-center studies have been published (19,34,35), while Carbonara et al. reported multicenter data (27). All studies concur that RAPN is feasible for endophytic renal masses, achieving functional and oncological outcomes similar to those observed in the broader RAPN population. Additionally, Minoda et al. specifically examined the differences between enucleation and standard resection techniques (20). Authors reported resection superiority over standard resection for endophytic mass with regard to renal function and shorter OT; while no difference in complication rate and PSM were reported. However, these results were retrospectively collected and the indication for resection method was not standardized or randomized but dependent on surgeon’s preference.

Studies comparing RAPN and OPN for endophytic tumors have demonstrated comparable long-term oncologic and functional outcomes. (28), with favorable trifecta achievement (68.4% vs 75%; OPN vs RAPN) (32) and shorter LOS and EBL for RAPN (31). When compared to LSP, outcomes appear again superimposable to the robotic technology with

shorter learning curve and more expensive (33). Focusing on tumor localization, ultrasonography has been highlighted as an essential tool in LPN for defining surgical planes more clearly (39). Additionally, intraoperative ultrasounds (IOUS) offer real-time imaging that aids in identifying and detailing the anatomical relationship between the renal lesion and surrounding structures, such as the pelvicalyceal system, renal sinus, and vessels. In robotic surgery, the robotic IOUS probe proves especially beneficial for maintaining an optimal angle and consistent contact with the kidney surface. (40,41). Sun et al. shared their positive experience with intraoperative US, reporting reduced EBL (144 vs. 257 ml), shorter WIT (20.4 vs. 25.6 min), and lower rates of positive surgical margins (7.9% vs. 15%) after RAPN (29).

As shown, RAPN is a feasible and safe treatment option for completely endophytic renal masses. Raheem et al. also investigated long-term outcomes, comparing the functional and oncologic results of RAPN and OPN with a median follow-up period of 59 months (28). They reported PSM rates of 9.6% for RAPN and 8.1% for OPN, significantly higher than rates observed in non-endophytic tumors. In a prior study, the same group recorded PSM rates of 2.1% and 4% for exophytic and mesophytic tumors, respectively. Notably, evidence suggests that the presence of a PSM does not necessarily correlate with disease recurrence.

CONCLUSIONS

This systematic review underscores that RAPN is a feasible and effective approach for managing completely endophytic renal tumors, which present significant technical challenges due to their intraparenchymal location and absence of visual cues. Advanced intraoperative tools, like robotic ultrasound, have proven valuable for overcoming the challenges of localizing these tumors, enhancing surgical precision, and minimizing complications. The use of intraoperative ultrasound during RAPN has been associated with reduced OT, lower EBL, and improved control over PSM, as reported in studies specifically utilizing this modality. However, long-term oncological outcomes for RAPN in endophytic tumors remain an area for further exploration.

In summary, this review supports RAPN as a viable and effective treatment option for completely endophytic renal tumors, particularly when performed in high-volume centers with robotic expertise. Future prospective research will be essential to refine surgical techniques, assess long-term impacts on renal function, and optimize management strategies for endophytic tumors to achieve the best patient outcomes.

Acknowledgements

None

Funding

None

Conflict of interest

The authors declare that they have no conflict of interest.

REFERENCES

1. Ljungberg B, Bensalah K, Canfield S, et al. EAU guidelines on renal cell carcinoma: 2014 update. *Eur Urol*. 2015;67(5):913-924. doi:10.1016/j.eururo.2015.01.005
2. Campbell SC, Clark PE, Chang SS, Karam JA, Souter L, Uzzo RG. Renal Mass and Localized Renal Cancer: Evaluation, Management, and Follow-Up: AUA Guideline: Part I. *J Urol*. 2021;206(2):199-208. doi:10.1097/JU.0000000000001911
3. Lasorsa F, Orsini A, Bignante G, et al. Predictors of delayed hospital discharge after robot-assisted partial nephrectomy: the impact of single-port robotic surgery. *World J Urol*. 2024 Dec 13;43(1):30. doi: 10.1007/s00345-024-05391-6
4. Milella M, Rutigliano M, Lasorsa F, et al. The Role of MUC1 in Renal Cell Carcinoma. *Biomolecules*. 2024;14(3). doi:10.3390/biom14030315
5. Cerrato C, Pandolfo SD, Autorino R, et al. Gender-specific counselling of patients with upper tract urothelial carcinoma and Lynch syndrome. *World J Urol*. 2023;41(7):1741-1749. doi:10.1007/s00345-023-04344-9
6. Campbell S, Uzzo RG, Allaf ME, et al. Renal Mass and Localized Renal Cancer: AUA Guideline. *J Urol*. 2017;198(3):520-529. doi:10.1016/j.juro.2017.04.100
7. Lasorsa F, Bignante G, Orsini A, et al. Partial nephrectomy in elderly patients: a systematic review and analysis of comparative outcomes. *Eur J Surg Oncol*. 2024;50(10). doi:10.1016/j.ejso.2024.108578

8. Antonelli A, Mari A, Tafuri A, et al. Prediction of significant renal function decline after open, laparoscopic, and robotic partial nephrectomy: External validation of the Martini's nomogram on the RECORD2 project cohort. *Int J Urol Off J Jpn Urol Assoc.* 2022;29(6):525-532. doi:10.1111/iju.14831
9. Benway BM, Bhayani SB, Rogers CG, et al. Robot assisted partial nephrectomy versus laparoscopic partial nephrectomy for renal tumors: a multi-institutional analysis of perioperative outcomes. *J Urol.* 2009;182(3):866-872. doi:10.1016/j.juro.2009.05.037
10. Cerrato C, Meagher MF, Autorino R, et al. Partial versus radical nephrectomy for complex renal mass: multicenter comparative analysis of functional outcomes (Rosula collaborative group). *Minerva Urol Nephrol.* 2023;75(4):425-433. doi:10.23736/S2724-6051.23.05123-6
11. Cerrato C, Patel D, Autorino R, et al. Partial or radical nephrectomy for complex renal mass: a comparative analysis of oncological outcomes and complications from the ROSULA (Robotic Surgery for Large Renal Mass) Collaborative Group. *World J Urol.* 2023;41(3):747-755. doi:10.1007/s00345-023-04279-1
12. Pandolfo SD, Cerrato C, Wu Z, et al. A systematic review of robot-assisted partial nephrectomy outcomes for advanced indications: Large tumors (cT2-T3), solitary kidney, completely endophytic, hilar, recurrent, and multiple renal tumors. *Asian J Urol.* 2023;10(4):390-406. doi:10.1016/j.ajur.2023.06.001
13. Altunrende F, Laydner H, Hernandez AV, et al. Correlation of the RENAL nephrometry score with warm ischemia time after robotic partial nephrectomy. *World J Urol.* 2013;31(5):1165-1169. doi:10.1007/s00345-012-0867-4
14. Pandolfo SD, Beksac A, Derweesh IH, et al. Percutaneous Ablation versus Robot-Assisted Partial Nephrectomy for Completely Endophytic Renal Masses: A Multicenter Trifecta Analysis with a Minimum 3-year Follow-up. *J Endourol.* Published online November 11, 2022. doi:10.1089/end.2022.0478
15. Pandolfo SD, Loizzo D, Beksac AT, et al. Percutaneous thermal ablation for cT1 renal mass in solitary kidney: A multicenter trifecta comparative analysis versus robot-assisted partial nephrectomy. *Eur J Surg Oncol.* 2023;49(2):486-490. doi:10.1016/j.ejso.2022.09.022
16. Pandolfo SD, Carbonara U, Beksac AT, et al. Microwave versus cryoablation and radiofrequency ablation for small renal mass: a multicenter comparative analysis. *Minerva Urol Nephrol.* 2023;75(1). doi:10.23736/S2724-6051.22.05092-3
17. Aveta A, Iossa V, Spena G, et al. Ablative Treatments for Small Renal Masses and Management of Recurrences: A Comprehensive Review. *Life.* 2024;14(4). doi:10.3390/life14040450
18. Bignante G, Orsini A, Lasorsa F, et al. Robotic-assisted surgery for the treatment of urologic cancers: recent advances. *Expert Rev Med Devices.* Published online December 1, 2024. doi:10.1080/17434440.2024.2435546
19. Antonelli A, Bennardo F, Brancaccio Y, et al. Can Bone Compaction Improve Primary Implant Stability? An In Vitro Comparative Study with Osseodensification Technique. *Applied Sciences.* 2020;10:8623. doi:10.3390/app10238623
20. Minoda R, Takagi T, Yoshida K, Kondo T, Tanabe K. Comparison of Surgical Outcomes Between Enucleation and Standard Resection in Robot-Assisted Partial Nephrectomy for Completely Endophytic Renal Tumors Through a 1:1 Propensity Score-Matched Analysis. *J Endourol.* 2021;35(12):1779-1784. doi:10.1089/end.2021.0213
21. Pandolfo SD, Wu Z, Campi R, et al. Outcomes and Techniques of Robotic-Assisted Partial Nephrectomy (RAPN) for Renal Hilar Masses: A Comprehensive Systematic Review. *Cancers.* 2024;16(4):693. doi:10.3390/cancers16040693
22. Grob G, Rogers D, Pandolfo SD, et al. Oncologic outcomes following radical nephroureterectomy for upper tract urothelial carcinoma: a literature review. *Transl Androl Urol.* 2023;12(8):1351-1362. doi:10.21037/tau-22-882
23. Loizzo D, Pandolfo SD, Del Giudice F, et al. Ureteroscopy and tailored treatment of upper tract urothelial cancer: recent advances and unmet needs. *BJU Int.* 2022;130(1):35-37. doi:10.1111/bju.15746
24. Pandolfo SD, Cilio S, Aveta A, et al. Upper Tract Urothelial Cancer: Guideline of Guidelines. *Cancers.* 2024;16(6):1115. doi:10.3390/cancers16061115
25. Napolitano L, Manfredi C, Cirillo L, et al. Cytoreductive Nephrectomy and Metastatic Renal Cell Carcinoma: State of the Art and Future Perspectives. *Med Kaunas Lith.* 2023;59(4):767. doi:10.3390/medicina59040767
26. Wu Z, Li M, Wang L, et al. Neoadjuvant systemic therapy in patients undergoing nephroureterectomy for urothelial cancer: a multidisciplinary systematic review and critical analysis. *Minerva Urol Nephrol.* 2022;74(5). doi:10.23736/S2724-6051.22.04659-6
27. Carbonara U, Simone G, Minervini A, et al. Outcomes of robot-assisted partial nephrectomy for completely endophytic renal tumors: A multicenter analysis. *Eur J Surg Oncol J Eur Soc Surg Oncol Br Assoc Surg Oncol.* 2021;47(5):1179-1186. doi:10.1016/j.ejso.2020.08.012
28. Abdel Raheem A, Chang KD, Alenzi MJ, et al. Robot-Assisted Partial Nephrectomy for Totally Endophytic Renal Tumors: Step by Step Standardized Surgical Technique and Long-Term Outcomes with a Median 59-Month Follow-Up. *J Laparoendosc Adv Surg Tech A.* 2019;29(1):1-11. doi:10.1089/lap.2018.0124
29. Sun Y, Wang W, Zhang Q, Zhao X, Xu L, Guo H. Intraoperative ultrasound: technique and clinical experience in robotic-assisted renal partial nephrectomy for endophytic renal tumors. *Int Urol Nephrol.* 2021;53(3):455-463. doi:10.1007/s11255-020-02664-y
30. Autorino R, Khalifeh A, Laydner H, et al. Robot-assisted partial nephrectomy (RAPN) for completely endophytic renal masses: a single institution experience. *BJU Int.* 2014;113(5):762-768. doi:10.1111/bju.12455
31. Kara O, Maurice MJ, Malkoc E, et al. Comparison of robot-assisted and open partial nephrectomy for completely endophytic renal tumours: a single centre experience. *BJU Int.* 2016;118(6):946-951. doi:10.1111/bju.13572

32. Harke NN, Mandel P, Witt JH, et al. Are there limits of robotic partial nephrectomy? TRIFECTA outcomes of open and robotic partial nephrectomy for completely endophytic renal tumors. *J Surg Oncol*. 2018;118(1):206-211. doi:10.1002/jso.25103
33. Gu L, Liu K, Shen D, et al. Comparison of Robot-Assisted and Laparoscopic Partial Nephrectomy for Completely Endophytic Renal Tumors: A High-Volume Center Experience. *J Endourol*. 2020;34(5):581-587. doi:10.1089/end.2019.0860
34. Curtiss KM, Ball MW, Gorin MA, Harris KT, Pierorazio PM, Allaf ME. Perioperative outcomes of robotic partial nephrectomy for intrarenal tumors. *J Endourol*. 2015;29(3):293-296. doi:10.1089/end.2014.0348
35. Komninos C, Shin TY, Tuliao P, et al. Robotic partial nephrectomy for completely endophytic renal tumors: complications and functional and oncologic outcomes during a 4-year median period of follow-up. *Urology*. 2014;84(6):1367-1373. doi:10.1016/j.urolgy.2014.08.012
36. Wells GA, Shea B, O'Connell D, et al. The Newcastle-Ottawa Scale (NOS) for assessing the quality of nonrandomised studies in meta-analyses. Published online 2000.
37. Saitta C, Afari JA, Autorino R, et al. Development of a novel score (RENSAFE) to determine probability of acute kidney injury and renal functional decline post surgery: A multicenter analysis. *Urol Oncol*. Published online October 23, 2023:S1078-1439(23)00330-7. doi:10.1016/j.urolonc.2023.09.015
38. Flammia RS, Anceschi U, Tuderti G, et al. Development and internal validation of a nomogram predicting 3-year chronic kidney disease upstaging following robot-assisted partial nephrectomy. *Int Urol Nephrol*. 2024;56(3):913-921. doi:10.1007/s11255-023-03832-6
39. Fazio LM, Downey D, Nguan CY, et al. Intraoperative laparoscopic renal ultrasonography: use in advanced laparoscopic renal surgery. *Urology*. 2006;68(4):723-727. doi:10.1016/j.urolgy.2006.04.022
40. Kaczmarek BF, Sukumar S, Petros F, et al. Robotic ultrasound probe for tumor identification in robotic partial nephrectomy: Initial series and outcomes. *Int J Urol Off J Jpn Urol Assoc*. 2013;20(2):172-176. doi:10.1111/j.1442-2042.2012.03127.x
41. Calace FP, Napolitano L, Arcaniolo D, et al. Micro-Ultrasound in the Diagnosis and Staging of Prostate and Bladder Cancer: A Comprehensive Review. *Med Kaunas Lith*. 2022;58(11):1624. doi:10.3390/medicina58111624



UPPER TRACT UROTHELIAL CARCINOMA: EAU GUIDELINES ON DIAGNOSIS, EPIDEMIOLOGY, AND RISK STRATIFICATION

G. Spena¹, A. Izzo¹, F. Passaro¹, U. Amicuzi², G. Villano², F. Capone², P. Conforti², E. Sicignano², V. Iossa³, S. Cilio⁴, A. Aveta⁵, F. Lasorsa⁶, P. Russo⁷, G.B. Filomena⁷ and S.D. Pandolfo^{8*}

¹ Department of Urology, Istituto Nazionale Tumori, IRCCS, "Fondazione G. Pascale", Naples, Italy;

² Department of Neuroscience, Reproductive Sciences and Odontostomatology, University of Naples "Federico II", Naples, Italy;

³ Urology Unit, Moscati Hospital, Avellino, Italy;

⁴ Department of Medicine and Surgery, Scuola Medica Salernitana, University of Salerno, Fisciano, Italy;

⁵ Department of Urology, Ospedale del Mare, ASL Napoli 1 Centro, Naples, Italy;

⁶ Department of Precision and Regenerative Medicine and Ionian Area-Urology, University of Bari "Aldo Moro", Bari, Italy;

⁷ Department of Urology, Fondazione Policlinico Universitario Agostino Gemelli, IRCCS, Rome, Italy;

⁸ Department of Urology, University of L'Aquila, L'Aquila, Italy.

*Correspondence to:

Savio Domenico Pandolfo,

Department of Urology,

University of L'Aquila,

67100 L'Aquila, Italy.

e-mail: pandolfosavio@gmail.com

ABSTRACT

Upper tract urothelial carcinoma (UTUC) is a rare but aggressive subtype of urothelial cancer, accounting for 5-10% of cases within this group. While it shares some environmental risk factors with bladder cancer, such as smoking and aromatic amine exposure, UTUC has unique epidemiological and genetic risk factors, including exposure to aris-tolochic acid and associations with Lynch syndrome. The European Association of Urology (EAU) guidelines provide a comprehensive approach to UTUC, emphasizing its distinct diagnostic and risk stratification needs. The guidelines recommend contrast-enhanced CT scans as the primary diagnostic tool, with MR urography as an alternative when contrast is contraindicated. For risk stratification, the EAU guidelines classify patients based on tumor characteristics and individual factors, such as age, comorbidity, and genetic predisposition, to tailor management plans effectively. Additionally, a dedicated TNM staging system is included to enhance disease classification. While the EAU guidelines represent an important resource for clinicians managing UTUC, further research, particularly into molecular biomarkers, is essential to refine risk assessment and improve prognostic accuracy. This review analyzes the EAU guidelines on UTUC, highlighting their strengths in addressing the unique aspects of UTUC diagnosis, risk stratification, and follow-up.

KEYWORDS: *UTUC, upper-tract urothelial carcinoma, EAU guidelines, diagnosis, risk stratification*

INTRODUCTION

Upper tract urothelial carcinoma (UTUC), though comprising only 5-10% of all urothelial carcinomas, is distinct from bladder cancer (BC), the most prevalent form in this category (1-3). UTUC shares several environmental risk factors with BC, particularly tobacco and aromatic amine exposure (4). However, UTUC also exhibits unique epidemiological characteristics and risk factors. Notably, aristolochic acid exposure, found in certain traditional Chinese herbal remedies, is associated with TP53 mutations in the urothelium, contributing to a higher UTUC incidence in specific regions, such as Taiwan (4,5). In Taiwan, UTUC constitutes 30% of urothelial cancers and displays a higher prevalence in females, alongside more adverse pathological features compared to other regions (6,7).

Clinically, UTUC frequently presents with hematuria in the majority of cases (around 80%), while flank pain is noted in about 20% of patients. Advanced cases often exhibit systemic symptoms associated with metastatic disease, such as unintended weight loss, fever, night sweats, and appetite loss (8). Occasionally, UTUC is identified incidentally through routine imaging for unrelated conditions (9).

While most UTUC cases are sporadic, genetic predispositions play a role in 10-20% of cases. Alterations in mismatch repair genes, linked to Lynch syndrome (LS) or hereditary non-polyposis colorectal cancer, have been identified as genetic risk factors (10). Current guidelines recommend genetic testing for individuals under 60 with UTUC and a family history of related cancers to identify those at elevated risk (4).

The asymptomatic or subtle nature of UTUC contributes to delayed diagnosis and high invasiveness at presentation, with approximately 70% of UTUC cases identified as invasive compared to 15-20% in BC (11). Furthermore, UTUC is generally more aggressive, with 5-year mortality rates exceeding 50%, in contrast to rates below 25% for BC (12,13).

Diagnosing UTUC presents particular challenges that often lead to poorer prognoses. Although similar in concept to BC diagnostics, UTUC requires diagnostic ureteroscopy (URS), which allows for cytology and biopsy (14). However, collecting tissue from the up-per tract can be technically challenging, and discrepancies between biopsy results and final pathology are common, complicating accurate staging and leading to suboptimal out-come. The COVID-19 pandemic has further complicated UTUC management, as delays in elective procedures and diagnostics have contributed to even later-stage presentations and potentially worsened outcomes (15).

Given the unique complexities in diagnosing and managing UTUC, there is a need for clear, evidence-based guidance tailored to this malignancy. This review focuses on the European Association of Urology (EAU) guidelines, evaluating their recommendations on diagnosis, and risk stratification, while identifying areas where further research and guideline development may enhance UTUC management.

MATERIALS AND METHODS

A focused literature review was conducted on MEDLINE/PubMed, Scopus, and Web of Science databases to identify the EAU guidelines on UTUC and their updates from 2010 to the present (September 2024). Selection criteria were established to prioritize clinical guidelines, consensus statements, and key studies informing guideline development. The search strategy was structured around specific terms related to UTUC management and clinical guide-lines, using the following search string: ((upper tract urothelial carcinoma) OR (UTUC) OR (urothelial carcinoma of the upper tract) OR (non-muscle-invasive bladder cancer guide-lines) OR (NMIBC guidelines) OR (urologic oncology guidelines)) AND ((evidence-based guidelines) OR (clinical guidelines) OR (treatment recommendations) OR (management strategies) OR (urology guidelines)) NOT (animal studies) NOT (editorials).

To ensure a comprehensive review, additional relevant articles were identified by manually examining the reference lists of key guidelines and review articles. Inclusion criteria focused on articles providing detailed recommendations on UTUC management, treatment protocols, and classification criteria. Data analysis was performed independently by two authors (G.S and A.A.), with any discrepancies resolved through consultation with a third author to maintain accuracy and consistency (S.D.P.).

RESULTS

Epidemiology

EAU guidelines recognize UTUC as relatively uncommon compared to BC, representing about 5-10% of all urothelial cancers to the EAU, UTUC most frequently affects individuals aged 70 to 90, with men showing a susceptibility approximately twice that of women (16,17).

Ther incidence in recent years may be attributed to improved detection methods and increased survival rates for BC (2,18). UTUC is also seen as a secondary condition following BC; an EAU multicenter study reported a 7.5% incidence

of UTUC in NMIBC patients treated with BCG over a 50-month follow-up, with intravesical recurrence and non-papillary tumors as key predictors (19). Furthermore, even after radical cystectomy for muscle-invasive BC, approximately 3-5% of patients may develop metachronous UTUC, indicating shared risk factecular pathways between UTUC and BC (20).

Risk factors

The EAU guidelines highlight the influence of environmental factors, particularly aristolochic acid and tobacco exposure, in UTUC development, noting that smoking raises UTUC risk between 2.5 and 7 times (LE: 2A, SE: weak) (21,22). They also acknowledge personal habits, such as alcohol consumption over 15 g/day, as potential risks, with a significantly increased UTUC risk in patients with such history compared to non-drinkers (23,24).

Hereditary factors, including LS also considered risk factors in all reviewed guidelines (10,25). The EAU proposes the Amsterdam criteria to identify families at high risk of LS (LE: 2A, SE: weak). Building on the EAU guidelines that highlight hereditary factors like LS as significant risks for UTUC, Cerrato et al. detail LS's complex impact on urothelial malignancies, showing a notable variation in cancer types associated with gender. LS is an autosomal dominant condition linked to mutations in mismatch repair genes, with UTUC being the third most common malignancy in LS patients, constituting up to 21% of new cases without prior diagnosis of LS (10,26).

Diagnosis

According to Soria et al., the EAU guidelines specifically address diagnostic measures for UTUC by highlighting the importance of recognizing symptoms such as hematuria, flank pain, and systemic signs tied to advanced disease, including weight loss, fever, and fatigue. Furthermore, they advocate for the use of contrast-enhanced CT scans of the abdomen and pelvis as a primary diagnostic tool due to its high sensitivity and specificity, followed by magnetic resonance urography if CT contrast is contraindicated (2). Indeed, among the guidelines addressing UTUC, only the EAU guidelines provide a comprehensive description of its suspicious symptoms, including micro/macro-hematuria, flank pain, and systemic signs linked to metastatic disease, such as anorexia, weight loss, malaise, fatigue, fever, night sweats, and cough (27–29). For diagnosing suspected UTUC, the EAU recommends contrast-enhanced CT scans of the abdomen and pelvis, which demonstrate high diagnostic accuracy, with a sensitivity of 92% (CI: 0.85–0.96) and specificity of 95% (CI: 0.88–0.98) (30,31). If contrast medium is contraindicated, MR urography is suggested, despite its lower sensitivity and specificity, with renal ultrasound as an additional follow-up if needed (32,33). A crucial aspect of the UTUC diagnostic pathway is cystoscopy to inspect the bladder, although cytologic sampling is not emphasized by EAU as it is in other guidelines (34).

EAU guidelines, instead, recommends urine sampling from the renal pelvis or ureter during endourological procedures. Indeed, recent preliminary evidence suggests that microbiome profiling through direct urine sampling from the renal pelvis or ureter during endourological procedures may improve the identification of diagnostic biomarkers for UTUC. This approach reduces sample contamination and enables the detection of specific bacterial taxa, such as *Porphyromonas*, a bacterium commonly found in the oral cavity, which has shown potential associations with urothelial carcinomas, including bladder cancer (35–37).

In cases where a clear diagnosis remains elusive, the EAU advises caution with ureteroscopy due to potential risks, recommending against biopsies whenever possible to avoid associated complications (SE: strong). For staging and assessing metastatic spread, the EAU suggests whole-body CT scans (SE: strong) and, if necessary, 18F-Fluorodeoxyglucose PET/CT to evaluate lymph node involvement (SE: weak) (38,39). Finally, the AUA guidelines suggest obtaining biopsy samples of suspicious lesions during endoscopic procedures, whereas the EAU panel recommends avoiding biopsies whenever possible due to associated risks (SE: strong) (40,41).

The diagnostic evaluation of UTUC includes imaging to rule out potential metastasis to other organs or lymph nodes. The EAU recommends whole-body CT scans for diagnosis and staging (SE: strong), or, if contraindicated, MR urography. For assessing nodal metastasis, 18F-Fluorodeoxyglucose PET/CT is suggested, albeit with a weaker evidence strength (SE: weak) (33,42).

Risk Stratification and Prognosis

EAU guidelines underscore the importance of detailed clinical assessment to effectively classify UTUC patients into low- and high-risk categories, as this classification plays a crucial role in guiding treatment decisions and managing peri-operative risks. For low-risk patients, kidney-sparing treatment options may be feasible, while those classified as high-risk are more likely to benefit from radical treatment approaches (LE: 3, SE: weak) (43,44). This stratification process aids in tailoring treatments to the individual risk profile, optimizing patient outcomes by balancing treatment effectiveness with potential risks.

For high-risk classification under the EAU criteria, several key factors are considered. High-grade cancer cells identified through positive cytology are a strong indicator, along with signs of local invasion observed in imaging and

nodal involvement, which signals potential metastatic spread. Tumor characteristics, such as a size greater than 2 cm, hydronephrosis (indicating obstruction in the kidney's drainage system), and multifocality (multiple tumor sites within the urinary tract), further define patients as high-risk, guiding clinicians toward more aggressive treatment plans (45,46).

Beyond tumor characteristics, the EAU guidelines also recognize patient-specific factors that contribute to a more aggressive UTUC course. African American patients, for instance, are noted to have worse outcomes, pointing to potential genetic or socio-environmental influences. Advanced age and tobacco consumption are also significant risk factors, as both have been associated with poorer prognosis and a higher likelihood of disease progression (47–49). Additionally, delayed surgical intervention, high comorbidity scores, and low performance indices are linked to increased risk, as they may limit the patient's resilience against intensive treatments.

The EAU guidelines also mention various blood-based biomarkers as potential indicators of prognosis. While promising, these biomarkers are not yet validated for routine use, reflecting an area of ongoing research (LE: 3). In recent years, emerging molecular biomarkers have shown promise for UTUC diagnosis and risk stratification, though none have yet been integrated into routine clinical management. Research on biomarkers for prognosis and disease monitoring is ongoing and essential. Additionally, liquid biopsies analyzing circulating tumor DNA (ctDNA) have gained attention, as ctDNA, a component of cell-free DNA, contains tumor-specific genetic alterations and can be detected in body fluids like plasma. While studies on ctDNA as a biomarker in UTUC remain limited, it offers a potentially valuable non-invasive diagnostic tool (3).

Finally, EAU guidelines highlight the importance of various patient-related factors in risk stratification for UTUC, including advanced age, tobacco use, and comorbidities, which can influence disease severity and treatment outcomes. Racial disparities in survival outcomes, as studied by Zappia et al., add further insight into UTUC risk factors by revealing how race may impact disease progression and post-surgical survival, although the study found no significant survival disadvantage across racial groups undergoing radical nephroureterectomy (RNU) (7).

DISCUSSION

UTUC is a rare subtype within urothelial carcinomas, sharing several characteristics with BC (50). The EAU guidelines provide comprehensive coverage of UTUC, distinguishing it as an independent entity from BC, with specific focus on its unique epidemiology, symptomatology, and diagnosis requirements. Unlike some other guidelines, the EAU guidelines elaborate on UTUC's unique epidemiological features, including associated risk factors like environmental exposures and hereditary syndromes, such as Lynch syndrome (21,22,38).

Our analysis highlights the strength of the EAU guidelines in presenting a structured diagnostic approach, starting with symptom recognition (hematuria, flank pain, and systemic symptoms linked to advanced disease), advancing to recommendations on imaging and endoscopic evaluation (46,51). The EAU guidelines particularly recommend the use of contrast-enhanced CT for high diagnostic accuracy and endorse MR urography when contrast media is contraindicated. Additionally, direct urine sampling during endourological assessment is encouraged to increase diagnostic specificity. These recommendations provide clinicians with a clear framework, supported by substantial evidence, to guide UTUC diagnosis.

In terms of risk stratification, the EAU guidelines stand out by categorizing patients based on risk to inform the likelihood of aggressive disease progression, considering factors such as tumor size, multifocality, and high-grade cytology findings. This stratification assists in guiding decisions related to UTUC's management pathway, reinforcing the need for individualized patient assessment based on comprehensive clinical findings (21).

One notable distinction in the EAU guidelines is their emphasis on a dedicated TNM staging system for UTUC, rather than relying on a BC-based staging framework. This allows for a more accurate representation of disease progression and aligns with UTUC's unique biological behavior. Such a distinction is essential for optimizing patient outcomes, as it enhances the precision of disease classification and follow-up protocols (21).

CONCLUSIONS

The EAU guidelines provide a detailed framework for diagnosing and stratifying UTUC, recognizing its unique features compared to bladder cancer. By recommending specific diagnostic tools, such as contrast-enhanced CT and MR urography, and emphasizing tailored risk stratification based on tumor and patient characteristics, these guidelines support more precise management strategies. The inclusion of a dedicated TNM staging system further underscores UTUC's distinct nature. While the guidelines enhance current clinical practice, ongoing research into biomarkers is needed to refine risk assessment and improve patient outcomes further.

Funding

None

Institutional Review Board Statement

Not needed

Data Availability Statement

This manuscript is based on data from eminent international guidelines and articles available at Societies websites and Scientific Databases.

Acknowledgments

None

Conflict of interest

The authors declare that they have no conflict of interest.

REFERENCES

1. Siegel RL, Miller KD, Fuchs HE, Jemal A. Cancer Statistics, 2021. *CA Cancer J Clin.* 2021;71(1):7-33. doi:10.3322/caac.21654
2. Soria F, Shariat SF, Lerner SP, et al. Epidemiology, diagnosis, preoperative evaluation and prognostic assessment of upper-tract urothelial carcinoma (UTUC). *World J Urol.* 2017;35(3):379-387. doi:10.1007/s00345-016-1928-x
3. Mu N, Jylhä C, Axelsson T, Sydén F, Brehmer M, Tham E. Patient-specific targeted analysis of circulating tumour DNA in plasma is feasible and may be a potential biomarker in UTUC. *World J Urol.* 2023;41(12):3421-3427. doi:10.1007/s00345-023-04583-w
4. Nally E, Young M, Chauhan V, et al. Upper Tract Urothelial Carcinoma (UTUC): Prevalence, Impact and Management Challenge. *Cancer Manag Res.* 2024;16:467-475. Published 2024 May 17. doi:10.2147/CMAR.S445529
5. Jain A, Nalavenkata S, Nahm C, Yuen L, Di Mascio D, Kim L. A diagnostic and management conundrum in a rare case of a small renal mass UTUC with IVC and bilateral renal vein tumour thrombus. *Urol Case Rep.* 2021;39:101817. doi:10.1016/j.eucr.2021.101817
6. Colin P, Koenig P, Ouzzane A, et al. Environmental factors involved in carcinogenesis of urothelial cell carcinomas of the upper urinary tract. *BJU Int.* 2009;104(10):1436-1440. doi:10.1111/j.1464-410X.2009.08838.x
7. Zappia J, Yong C, Slaven J, et al. Survival Outcomes by Race Following Surgical Treatment for Upper Tract Urothelial Carcinoma. *Clin Genitourin Cancer.* 2024;22(6):102220. doi:10.1016/j.clgc.2024.102220
8. Zganjar AJ, Thiel DD, Lyon TD. Diagnosis, workup, and risk stratification of upper tract urothelial carcinoma. *Transl Androl Urol.* 2023;12(9):1456-1468. doi:10.21037/tau-23-45
9. Kumar R, Kumar Airon R, Mittal A, Singal R, Sharma K, Singal S. Evaluation of Multidetector Computed Tomography in Haematuria. *Maedica (Bucur).* 2017;12(2):87-94.
10. Cerrato C, Pandolfo SD, Autorino R, et al. Gender-specific counselling of patients with upper tract urothelial carcinoma and Lynch syndrome. *World J Urol.* Published online March 24, 2023. doi:10.1007/s00345-023-04344-9
11. Rouprêt M, Seisen T, Birtle AJ, et al. European Association of Urology Guidelines on Upper Urinary Tract Urothelial Carcinoma: 2023 Update. *Eur Urol.* Published online March 24, 2023;S0302-2838(23)02652-0. doi:10.1016/j.eururo.2023.03.013
12. Coleman JA, Clark PE, Bixler BR, et al. Diagnosis and Management of Non-Metastatic Upper Tract Urothelial Carcinoma: AUA/SUO Guideline. *J Urol.* 2023;209(6):1071-1081. doi:10.1097/JU.0000000000003480
13. Wu Z, Li M, Wang L, et al. Neoadjuvant systemic therapy in patients undergoing nephroureterectomy for urothelial cancer: a multidisciplinary systematic review and critical analysis. *Minerva Urol Nephrol.* 2022;74(5). doi:10.23736/S2724-6051.22.04659-6
14. Grob G, Rogers D, Pandolfo SD, et al. Oncologic outcomes following radical nephroureterectomy for upper tract urothelial carcinoma: a literature review. *Transl Androl Urol.* 2023;12(8):1351-1362. doi:10.21037/tau-22-882

15. Moretti L, Bizzoca D, Vitale E, et al. Gender and socio-economic issues in the clinical assessment of orthopaedic patients during the covid-19 pandemic. *European Journal of Musculoskeletal Diseases*. 2022;11(1):15-21.
16. Siegel RL, Miller KD, Jemal A. Cancer statistics, 2020. *CA Cancer J Clin*. 2020;70(1):7-30. doi:10.3322/caac.21590
17. Shariat SF, Favaretto RL, Gupta A, et al. Gender differences in radical nephroureterectomy for upper tract urothelial carcinoma. *World J Urol*. 2011;29(4):481-486. doi:10.1007/s00345-010-0594-7
18. Almås B, Halvorsen OJ, Johannesen TB, Beisland C. Higher than expected and significantly increasing incidence of upper tract urothelial carcinoma. A population based study. *World J Urol*. 2021;39(9):3385-3391. doi:10.1007/s00345-020-03576-3
19. Nishiyama N, Hotta H, Takahashi A, et al. Upper tract urothelial carcinoma following intravesical bacillus Calmette-Guérin therapy for nonmuscle-invasive bladder cancer: Results from a multi-institutional retrospective study. *Urol Oncol*. 2018;36(6):306.e9-306.e15. doi:10.1016/j.urolonc.2018.02.009
20. Sanderson KM, Rouprêt M. Upper urinary tract tumour after radical cystectomy for transitional cell carcinoma of the bladder: an update on the risk factors, surveillance regimens and treatments. *BJU Int*. 2007;100(1):11-16. doi:10.1111/j.1464-410X.2007.06841.x
21. EAU Guidelines on Upper Urinary Tract Urothelial Cell Carcinoma - INTRODUCTION - Uroweb. Uroweb - European Association of Urology. Accessed December 4, 2023. <https://uroweb.org/guidelines/upper-urinary-tract-urothelial-cell-carcinoma/chapter/introduction>
22. Diagnosis and Management of Non-Metastatic Upper Tract Urothelial Carcinoma: AUA/SUO Guideline - American Urological Association. Accessed December 4, 2023. <https://www.auanet.org/guidelines-and-quality/guidelines/non-metastatic-upper-tract-urothelial-carcinoma>
23. Dickman KG, Fritsche HM, Grollman AP, Thalmann GN, Catto J. Epidemiology and Risk Factors for Upper Urinary Urothelial Cancers. In: Shariat SF, Xylinas E, eds. *Upper Tract Urothelial Carcinoma*. Springer; 2015:1-30. doi:10.1007/978-1-4939-1501-9_1
24. Zaitu M, Kawachi I, Takeuchi T, Kobayashi Y. Alcohol consumption and risk of upper-tract urothelial cancer. *Cancer Epidemiol*. 2017;48:36-40. doi:10.1016/j.canep.2017.03.002
25. Metcalfe MJ, Petros FG, Rao P, et al. Universal Point of Care Testing for Lynch Syndrome in Patients with Upper Tract Urothelial Carcinoma. *J Urol*. 2018;199(1):60-65. doi:10.1016/j.juro.2017.08.002
26. Umar A, Boland CR, Terdiman JP, et al. Revised Bethesda Guidelines for hereditary nonpolyposis colorectal cancer (Lynch syndrome) and microsatellite instability. *J Natl Cancer Inst*. 2004;96(4):261-268. doi:10.1093/jnci/djh034
27. Rai BP, Luis Dominguez Escrig J, Vale L, et al. Systematic Review of the Incidence of and Risk Factors for Urothelial Cancers and Renal Cell Carcinoma Among Patients with Haematuria. *Eur Urol*. 2022;82(2):182-192. doi:10.1016/j.eururo.2022.03.027
28. Baard J, Cormio L, Cavadas V, et al. Contemporary patterns of presentation, diagnostics and management of upper tract urothelial cancer in 101 centres: the Clinical Research Office of the Endourological Society Global upper tract urothelial carcinoma registry. *Curr Opin Urol*. 2021;31(4):354-362. doi:10.1097/MOU.0000000000000899
29. Jakus D, Šolić I, Borovac JA, Šitum M. The influence of the initial clinical presentation of upper tract urothelial carcinoma on histopathological tumor features. *Int Urol Nephrol*. Published online November 28, 2023. doi:10.1007/s11255-023-03883-9
30. Rud E, Galtung KF, Lauritzen PM, Baco E, Flatabø T, Sandbæk G. Examining the upper urinary tract in patients with hematuria-time to revise the CT urography protocol? *Eur Radiol*. 2020;30(3):1664-1670. doi:10.1007/s00330-019-06521-0
31. Janisch F, Shariat SF, Baltzer P, et al. Diagnostic performance of multidetector computed tomographic (MDCTU) in upper tract urothelial carcinoma (UTUC): a systematic review and meta-analysis. *World J Urol*. 2020;38(5):1165-1175. doi:10.1007/s00345-019-02875-8
32. Tsikitas LA, Hopstone MD, Raman A, Duddalwar V. Imaging in Upper Tract Urothelial Carcinoma: A Review. *Cancers (Basel)*. 2023;15(20):5040. doi:10.3390/cancers15205040
33. Razavi SA, Sadigh G, Kelly AM, Cronin P. Comparative effectiveness of imaging modalities for the diagnosis of upper and lower urinary tract malignancy: a critically appraised topic. *Acad Radiol*. 2012;19(9):1134-1140. doi:10.1016/j.acra.2012.05.004
34. Potretzke AM, Knight BA, Vetter JM, et al. Diagnostic Utility of Selective Upper Tract Urinary Cytology: A Systematic Review and Meta-analysis of the Literature. *Urology*. 2016;96:35-43. doi:10.1016/j.urology.2016.04.030

35. Nardelli C, Aveta A, Pandolfo SD, et al. Microbiome Profiling in Bladder Cancer Patients Using the First-morning Urine Sample. *Eur Urol Open Sci.* 2024;59:18-26. doi:10.1016/j.euros.2023.11.003
36. Russo F, Esposito S, Tripodi L, et al. Insights into *Porphyromonas somerae* in Bladder Cancer Patients: Urinary Detection by ddPCR. *Microorganisms.* 2024;12(10):2049. doi:10.3390/microorganisms12102049
37. Di Stasio D, Lauritano D, Minervini G, et al. Management of denture stomatitis: A narrative review. *Journal of Biological Regulators and Homeostatic Agents.* 2018;32(2):113-116.
38. Pandolfo SD, Cilio S, Aveta A, et al. Upper Tract Urothelial Cancer: Guideline of Guidelines. *Cancers (Basel).* 2024;16(6):1115. doi:10.3390/cancers16061115
39. Loizzo D, Pandolfo SD, Del Giudice F, et al. Ureteroscopy and tailored treatment of upper tract urothelial cancer: recent advances and unmet needs. *BJU International.* 2022;130(1):35-37. doi:10.1111/bju.15746
40. Vashistha V, Shabsigh A, Zynger DL. Utility and diagnostic accuracy of ureteroscopic biopsy in upper tract urothelial carcinoma. *Arch Pathol Lab Med.* 2013;137(3):400-407. doi:10.5858/arpa.2012-0136-OA
41. Mori K, Katayama S, Laukhtina E, et al. Discordance Between Clinical and Pathological Staging and Grading in Upper Tract Urothelial Carcinoma. *Clin Genitourin Cancer.* 2022;20(1):95.e1-95.e6. doi:10.1016/j.clgc.2021.10.002
42. Voskuilen CS, Schweitzer D, Jensen JB, et al. Diagnostic Value of 18F-fluorodeoxyglucose Positron Emission Tomography with Computed Tomography for Lymph Node Staging in Patients with Upper Tract Urothelial Carcinoma. *Eur Urol Oncol.* 2020;3(1):73-79. doi:10.1016/j.euo.2019.09.004
43. Rouprêt M, Colin P, Yates DR. A new proposal to risk stratify urothelial carcinomas of the upper urinary tract (UTUCs) in a predefinitive treatment setting: low-risk versus high-risk UTUCs. *Eur Urol.* 2014;66(2):181-183. doi:10.1016/j.eururo.2013.12.007
44. Seisen T, Colin P, Rouprêt M. Risk-adapted strategy for the kidney-sparing management of upper tract tumours. *Nat Rev Urol.* 2015;12(3):155-166. doi:10.1038/nrurol.2015.24
45. Messer JC, Terrell JD, Herman MP, et al. Multi-institutional validation of the ability of preoperative hydronephrosis to predict advanced pathologic tumor stage in upper-tract urothelial carcinoma. *Urol Oncol.* 2013;31(6):904-908. doi:10.1016/j.urolonc.2011.07.011
46. Foerster B, Abufaraj M, Mari A, et al. The Performance of Tumor Size as Risk Stratification Parameter in Upper Tract Urothelial Carcinoma (UTUC). *Clin Genitourin Cancer.* 2021;19(3):272.e1-272.e7. doi:10.1016/j.clgc.2020.09.002
47. Di Stasio D, Lauritano D, Gritti P, et al. Psychiatric disorders in oral lichen planus: a preliminary case control study. *J Biol Regul Homeost Agents.* 2018;32(2 Suppl. 1):97-100.
48. Xia L, Taylor BL, Pulido JE, Guzzo TJ. Impact of surgical waiting time on survival in patients with upper tract urothelial carcinoma: A national cancer database study. *Urol Oncol.* 2018;36(1):10.e15-10.e22. doi:10.1016/j.urolonc.2017.09.013
49. Aziz A, Fritsche HM, Gakis G, et al. Comparative analysis of comorbidity and performance indices for prediction of oncological outcomes in patients with upper tract urothelial carcinoma who were treated with radical nephroureterectomy. *Urol Oncol.* 2014;32(8):1141-1150. doi:10.1016/j.urolonc.2014.04.008
50. Aveta A, Cacciapuoti C, Barone B, et al. The Impact of Meat Intake on Bladder Cancer Incidence: Is It Really a Relevant Risk? *Cancers.* 2022;14(19):4775. doi:10.3390/cancers14194775
51. Calace FP, Napolitano L, Arcaniolo D, et al. Micro-Ultrasound in the Diagnosis and Staging of Prostate and Bladder Cancer: A Comprehensive Review. *Medicina (Kaunas).* 2022;58(11):1624. doi:10.3390/medicina58111624



Review

BEYOND THE MICROSCOPE: THE UROBIOME'S HIDDEN INFLUENCE ON GENITOURINARY CANCERS

A. Aveta¹, S. Palumbo², G. Spena³, A. Izzo³, F. Passaro³, G. Villano⁴, F. Capone⁴, U. Amicuzi⁴, E. Sicignano⁴, P. Conforti⁴, S. Cilio⁵, V. Iossa⁶, F. Lasorsa⁷, P. Russo⁸, G.B. Filomena⁸ and S.D. Pandolfo^{9*}

¹ Department of Urology, Ospedale del Mare, ASL Napoli 1 Centro, Naples, Italy;

² Department of Molecular Medicine and Medical Biotechnologies, Naples, Italy;

³ Department of Urology, Istituto Nazionale Tumori, IRCCS, "Fondazione G. Pascale", Naples, Italy;

⁴ Department of Neuroscience, Reproductive Sciences and Odontostomatology, University of Naples "Federico II", Naples, Italy;

⁵ Department of Medicine and Surgery, Scuola Medica Salernitana, University of Salerno, Fisciano, Italy;

⁶ Urology Unit, Moscati Hospital, Avellino, Italy;

⁷ Department of Precision and Regenerative Medicine and Ionian Area-Urology, University of Bari "Aldo Moro", Bari, Italy;

⁸ Department of Urology, Fondazione Policlinico Universitario Agostino Gemelli, IRCCS, Rome, Italy;

⁹ Department of Urology, University of L'Aquila, L'Aquila, Italy.

*Correspondence to:

Savio Domenico Pandolfo,

Department of Urology,

University of L'Aquila,

67100 L'Aquila, Italy.

e-mail: pandolfosavio@gmail.com

ABSTRACT

Context: The human microbiome plays a crucial role in health and disease, and alterations in microbial communities have been implicated in various cancers. The urinary microbiome has emerged as a potential contributor to the development and progression of genitourinary cancers. **Objective:** To review the current literature on the relationship between the urinary microbiome and genitourinary cancers, including bladder cancer, kidney cancer, and prostate cancer. **Evidence acquisition:** A narrative review of relevant articles was conducted, summarizing the current understanding of the urinary microbiome in the context of genitourinary malignancies. **Evidence synthesis:** The review highlights the complex interplay between the urinary microbiome and genitourinary cancers. While research in this area is still evolving, evidence suggests that the urinary microbiome may contribute to chronic inflammation, immune dysregulation, and tumorigenesis in the urinary tract. Specific microbial signatures have been associated with cancer risk, diagnosis, and prognosis. **Conclusions:** The urinary microbiome holds promise as a non-invasive biomarker for genitourinary cancers and a potential target for novel therapeutic strategies. Further research is needed to fully elucidate the functional role of the urinary microbiome in cancer development and progression.

KEYWORDS: Urinary microbiome, genitourinary cancers, bladder cancer, kidney cancer, prostate cancer, microbial biomarkers, cancer pathogenesis

Received: 02 December, 2024

Accepted: 17 December, 2024

ISSN 2038-4106 print

ISSN 2975-044X online Copyright © by BIOLIFE 2024

This publication and/or article is for individual use only and may not be further reproduced without written permission from the copyright holder. Unauthorized reproduction may result in financial and other penalties. Disclosure: All authors report no conflicts of interest relevant to this article.

INTRODUCTION

The 19th-century doctrine that urine is a sterile fluid has been definitively overturned (1). Advances in microbial detection, including 16S ribosomal RNA (16S rRNA) and whole-genome shotgun sequencing, have revealed a complex ecosystem of microorganisms inhabiting the urinary tract, collectively termed the “urobiome”. This microbial community plays a vital role in urinary health, influencing everything from immune responses to nutrient metabolism (2).

Since the recognition of bacteria, it has been established that humans coexist with vast microbial ecosystems at various bodily sites, including the skin, mucous membranes, and notably, the gastrointestinal tract (3,4). Recent research indicates that microbiomes in these sites are essential not only for immunity but also for key physiological processes. The urinary microbiome, once thought absent or irrelevant, now joins these other microbial habitats in demonstrating profound immunological and physiological effects (5).

Importantly, the urobiome begins to develop rapidly from early childhood, but it is constantly shaped and reshaped by a variety of factors throughout our lives. These include our genetics, diet, environment, exposure to toxins, and hormone levels (6–8).

Furthermore, an increasing body of evidence connects specific microorganisms to cancer pathogenesis, as demonstrated by agents like *Helicobacter pylori* in gastric cancer and Human *Papilloma Virus* in cervical cancer (9). Similar mechanisms are being investigated within the urinary tract, where shifts in the urobiome composition may influence cancer susceptibility and progression (10). This inflammatory environment can trigger the release of harmful metabolites, such as reactive oxygen and nitrogen species, which can damage DNA and initiate tumorigenesis. Any imbalance in this microbial community, whether in the types of organisms present or their relative abundances, may disrupt the host's physiological equilibrium and foster cancer development (11).

In recent years, modifications in the composition of the urobiome have been linked to various urological disorders, including urinary tract infections and cancers. Particularly in the context of malignancies, this could be highly significant for identifying potential biomarkers for diagnosis as well as exploring new therapeutic options to complement conventional treatments (12).

We examined current literature on the connection between the urinary microbiome and genitourinary cancers, including bladder, kidney, and prostate malignancies, seeking to synthesize and critically appraise the existing evidence. This analysis highlights the potential of microbiome research to deepen our understanding of cancer biology and improve clinical outcomes.

MATERIALS AND METHODS

We conducted a narrative review using PubMed, covering publications from the database's inception to November 2024, with no time restrictions. Our search focused on articles published in English and included the following keywords: "urobiome," "urinary microbiome," "genitourinary cancer," "urogenital cancer," "bladder cancer," "prostate cancer," "kidney cancer," and "Upper Tract Urothelial Carcinoma." We applied Boolean operators (AND, OR) to combine keywords and refine search results. For example, we used combinations such as ("urobiome" OR "urinary microbiome") AND ("bladder cancer" OR "prostate cancer") to increase relevance.

We included studies conducted on humans and published in peer-reviewed journals. We excluded nonhuman studies, case reports, editorials, letters, unpublished studies, conference posters, and comments. Relevant information from the included studies was extracted and synthesized narratively to provide a descriptive summary of the findings.

RESULTS

The Urobiome and Bladder Cancer

Bladder cancer (BCa) ranks as one of the most common cancers affecting the urinary tract worldwide. The majority of these cases, about 70–80%, are classified as non-muscle invasive bladder cancer (NMIBC), making it the predominant type diagnosed (13). In addition to established risk factors like genetics, tobacco use, and contact with occupational chemicals or toxins, the urobiome is now being recognized as a potential new contributor to BCa development (14,15).

While research continues to explore the intricate relationship between the urinary microbiome and bladder cancer, several studies have shed light on potential mechanisms by which urinary microbes may contribute to carcinogenesis. One key mechanism involves biofilm-forming bacteria, which drive chronic inflammation and subsequently facilitate carcinogenesis (2) (Fig.1). For instance, Alfano et al. highlighted how different bacterial compositions can influence the

extracellular matrix, leading to altered expression of metalloproteinases, enzymes that degrade the extracellular matrix and can promote tumor invasion and metastasis (16). Chen et al. emphasized the role of the urinary microbiome in modulating the immune response, which can influence the body's ability to detect and destroy cancer cells. Patients with PD-L1-positive NMIBC showed greater bacterial richness and differences in bacterial representations compared to PD-L1-negative patients. The bacterial genus *Leptotrichia* was associated with increased expression of PD-L1, a marker that can inhibit T cell activity and promote tumor immune evasion (17).

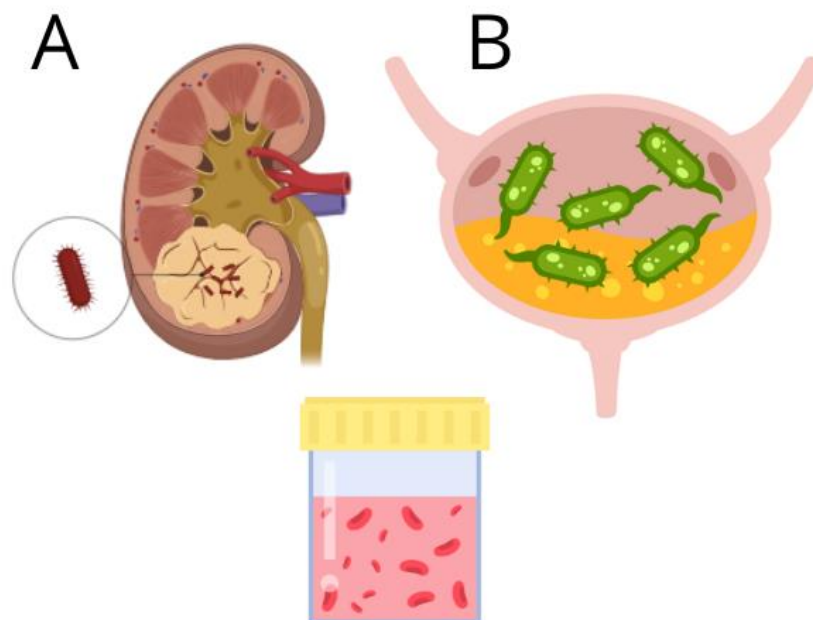


Fig. 1. Schematic representation of microbial involvement in urologic cancers. (A) Upper tract urothelial carcinoma (UTUC), highlighting the presence of bacteria possibly contributing to carcinogenesis within the renal pelvis. (B) Bladder cancer (BCa) with bacterial presence in the bladder environment, illustrating potential roles of microbial communities in tumor progression and immune modulation.

Various factors contribute to differences in the urinary microbiome. While generally consistent among healthy individuals, studies have identified pathogenic variations related to age and sex (18). Sex-related differences, in particular, have been studied more extensively than age-related ones, showing distinct microbial compositions between males and females. For example, *Lactobacillus* and *Gardnerella* species typically dominate the female urinary microbiota, whereas *Corynebacterium*, *Staphylococcus*, and *Streptococcus* are more commonly found in the male urinary tract (8). These differences may be due to variations in lower urinary tract anatomy, hormonal influences, and metabolic processes (19,20). It is plausible that this disparity in microbial communities contributes to the observed differences in the incidence of genitourinary cancers between men and women.

Although the link between the urinary microbiome and bladder cancer has become more apparent, the findings remain inconsistent, partly due to variations in sample types used across studies (21). The first link between urinary bladder microbiota and urothelial bladder cancer development was established by Xu et al. in 2014, who used 16S sequencing to compare voided urine samples from 8 Urothelial cell carcinoma (UCC) patients and 6 healthy controls. Although voided urine was viewed as less reliable for profiling the bladder microbiome, *Pseudomonas* and *Anaerococcus* species were more frequently detected in patients with UCC (18). In 2018, Popović et al. compared 12 male bladder cancer patients with 11 controls, finding no significant overall microbiome differences but noted an enrichment of operational taxonomic units (OUT) belonging to genus *Fusobacterium* in cancer patients (2). Conversely, Wu et al. analyzed 49 mid-stream urine samples and identified higher levels of *Acinetobacter*, *Anaerococcus*, *Rubrobacter*, *Sphingobacterium*, *Atopostipes*, and *Geobacillus* in patients with bladder cancer (22). In a similar study, Hai Bi et al. examined mid-stream urine from 29 cancer patients and 26 controls, finding *A. europaeus* more commonly present in those with cancer (23).

In 2021, Ma et al. further conducted an analysis of microbiota in 15 cancer patients and 11 controls, finding that *Stenotrophomonas*, *Enterococcaceae*, *Enterococcus*, *Myroides*, and *Parvimonas* were notably enriched in the samples from cancer patients (24).

Pederzoli et al., in the same year, expanded the scope by examining both urine and tumor tissue samples from 49 bladder cancer patients compared to 59 controls. They reported a higher abundance of *Klebsiella* in the urine and *Burkholderia* in the tumor tissues of bladder cancer patients, suggesting that certain bacteria may colonize specific niches in cancerous tissues (25). Similarly, Hussein et al. identified higher levels of *Actinobacteria*, *Proteobacteria*, *Actinomyces*, *Achromobacter*, *Brevibacterium*, and *Brucella* in the microbiota of 43 cancer patients compared to 10 controls, further supporting the theory of a unique bacterial signature associated with bladder cancer (21). In a comparable investigation, Chipollini et al. found that *Bacteroides*, *Lachnospirillum*, and *Burkholderiaceae* were more frequent in controls, whereas *Faecalibacterium* was prevalent in samples from invasive cancer cases (26). Zeng et al., focusing on 40 NMIBC patients, provided insights into the prognostic significance of microbiome diversity, showing that patients with lower alpha diversity in their microbiome had a longer recurrence-free survival (27).

Further findings in 2022 by Ahn et al. showed that *Micrococcus sp.* was significantly more prevalent in 32 bladder cancer patients compared to 24 controls, while Parra-Grande et al. identified an enrichment of *Actinobacteria* in non-tumor samples (28,29).

More recent studies have continued to build on these findings. In 2023, Zhang et al. compared 51 NMIBC patients with 47 controls and found *Eubacterium sp. CAG:581*, *Bacteroides sp. 4_3_47FAA*, and *Flavobacteriales* to be enriched in cancer patients (30). That same year, Hrbáček et al. concluded that the microbiota in 34 bladder cancer patients had reduced richness and diversity when compared to 29 controls, underscoring the role of altered microbial composition in cancer pathophysiology (31).

In relation to the type of sample analyzed, Oresta et al. observed notable microbial differences among catheterized urine, midstream voided urine, and bladder washout samples in bladder cancer patients. Specifically, catheterized urine samples from these patients showed higher levels of *Veillonella* and *Corynebacterium* and lower levels of *Ruminococcus* compared to controls. In bladder washouts, there was a marked increase in certain taxa like *Burkholderiaceae*, while midstream urine samples were predominantly enriched with *Streptococcus* (32). Similarly, Bukavina et al. found that catheterized urine samples exhibited less variability in bacterial genera and lower levels of contamination compared to voided urine samples (33,34). In contrast, Nardelli et al. found that first-morning urine samples provide a practical option for analyzing the urobiome. Increased prevalence of *Porphyromonas* and *Porphyromonas somerae* was observed in BCa patients compared to controls using Next-Generation Sequencing (NGS), with a stronger association in male BCa patients over 50 years old ($p < 0.05$) (35). This finding was further supported by Russo et al., who confirmed the presence of *P. somerae* in BCa patients using droplet digital Polymerase Chain Reaction on a cohort of over 100 patients (36).

Intriguingly, emerging evidence suggests a potential interchange between the urinary microbiome and the response to Bacillus Calmette-Guérin (BCG) therapy. One of the most promising frontiers in bladder cancer research lies in the modulation of the urinary microbiome, particularly in the context of BCG therapy, a standard treatment for non-muscle-invasive bladder cancer (NMIBC). While BCG is known to elicit a robust immune response against tumor cells, the precise mechanisms underlying its efficacy remain incompletely understood (37).

A comprehensive analysis of tumor tissue, urine samples, and formalin-fixed paraffin-embedded tissue blocks from NMIBC patients identified distinct differences in the microbiome between BCG responders and non-responders. Notably, responders exhibited a greater abundance of *Lactobacillus* species, suggesting a potential role for these commensal bacteria in augmenting the antitumor immune response (37). Similarly, Heidrich et al. investigated the urinary microbiome in men with NMIBC and compared it to that of men with benign prostatic hyperplasia. While no significant differences were observed between the groups overall, an enrichment of *Lactobacillus*, *Streptococcus*, and *Cutibacterium* was associated with a favorable response to BCG therapy (38).

However, *Lactobacillus*'s role in BCG therapy remains ambiguous. While some studies have reported a positive correlation between *Lactobacillus* abundance and treatment response, others have yielded conflicting results.

Conversely, James et al. observed an association between a high abundance of *Aerococcus* and increased rates of cancer recurrence. In contrast, *Escherichia/Shigella* and *Ureaplasma* were found to be more prevalent in patients who remained disease-free (39). These findings suggest a complex interplay between specific bacterial taxa and the response to BCG therapy.

These findings together highlight the complex and evolving relationship between the urinary microbiome and BCa, suggesting that specific microbial signatures, coupled with sample type and demographic factors, may play a critical role in bladder cancer risk, prognosis, and progression.

The Urobiome and Upper Tract Urothelial Carcinoma

Upper tract urothelial carcinoma (UTUC) represents less than 10% of all urothelial cancers, with BCa being the most prevalent form (40). Both UTUC and BCa share several environmental risk factors, notably smoking and exposure to

aristolochic acid (41,42). Clinically, UTUC often presents with hematuria in nearly 80% of cases, and less frequently, with flank pain (20%) (43). In some cases, UTUC is incidentally detected on cross-sectional imaging showing a collecting system lesion (44).

The often pauci-symptomatic nature of UTUC contributes to delayed diagnosis and a higher prevalence of invasive disease at presentation, with approximately 70% of UTUC cases showing invasiveness compared to only 15–20% in BCa (45). Although UTUC and BCa share similarities in risk factors and certain aspects of tumor biology, UTUC has a more aggressive clinical course, evidenced by a five-year mortality rate exceeding 50%, more than double that of BCa (<25%) (46).

Given the emerging role of the urobiome in other genitourinary cancers, it is plausible that the urinary microbiome may also influence the development and progression of UTUC. However, to date, there is a paucity of research specifically investigating the relationship between the urobiome and UTUC (35,36) (Fig. 1). Further studies are warranted to explore the potential contributions of the urinary microbiome to UTUC carcinogenesis and to assess its potential as a biomarker for risk stratification, early detection, and treatment response.

The Urobiome and Prostate Cancer

Prostate cancer represents a significant global health burden, ranking among the most frequently diagnosed malignancies and leading causes of cancer-related mortality in men. Epidemiological data underscores its substantial impact, with millions of new cases diagnosed annually worldwide (47). Localized prostate cancer, confined to the prostate gland, is often amenable to curative treatments such as surgery (radical prostatectomy) or radiotherapy. These approaches aim to eradicate the tumor and offer the potential for long-term disease control (48). However, advanced prostate cancer, characterized by local invasion or distant metastasis, necessitates systemic therapies like androgen deprivation therapy, chemotherapy, and novel hormonal agents (49).

Despite therapeutic advances, significant challenges persist in the management of advanced prostate cancer, particularly in cases of castration-resistant prostate cancer (CRPC), which frequently exhibits resistance to conventional ADT and chemotherapy. The exploration of novel therapeutic modalities, including those targeting the human microbiome, holds promise for improving outcomes in this challenging clinical context (11,50).

Several studies have reported associations between specific alterations in the urobiome and an increased risk of prostate cancer. Yu et al. discovered that specific bacterial groups, including *Bacteroidetes* and *Firmicutes*, were more prevalent in the prostatic secretions of men with prostate cancer than in those with benign prostatic hyperplasia (51). Similarly, a study by Shrestha et al. identified a cluster of bacteria, such as *Streptococcus anginosus* and *Anaerococcus lactolyticus*, linked to an elevated risk of prostate cancer (19).

However, research on the urobiome in prostate cancer has produced inconsistent results. This variability may stem from differences in study methodologies, including urine collection techniques and analysis methods. Alanee et al. analyzed first-void urine samples after prostatic massage and reported an increase in *Veillonella*, *Streptococcus*, and *Bacteroides* and a decrease in *Faecalibacterium*, *Lactobacilli*, and *Actinobacter* in men with prostate cancer (52). Tsai et al. analyzed the urobiome in men with lower urinary tract symptoms (LUTS), BPH, and prostate cancer, using men with LUTS but without BPH as controls. Their findings revealed unique urobiome profiles for each group, with higher levels of *Escherichia*, *Shigella*, and *Pseudomonas* in prostate cancer patients compared to those with BPH (53). Additionally, Hurst et al. found a significant association between the urobiome and prostate cancer risk, independent of common risk factors like PSA levels. They identified certain anaerobic bacteria, such as *Fenollaria* and *Porphyromonas*, which may be associated with poorer prognosis (54).

While a definitive causal relationship between infection and prostate cancer remains elusive, accumulating evidence suggests that the urinary microbiome may contribute to prostate carcinogenesis through the induction of chronic prostatic inflammation (55). This hypothesis posits that pro-inflammatory bacterial species, upon colonization of the prostate, can elicit a persistent inflammatory response that may promote the development of inflammatory atrophy, a recognized factor for prostate cancer (56).

Despite the heterogeneity in findings, the urobiome shows potential as a non-invasive biomarker for prostate cancer. Further research is needed to clarify its role in prostate carcinogenesis and to explore its potential for early diagnosis, risk assessment, and prognostic stratification.

The Urobiome and Kidney Cancer

Renal cell carcinoma (RCC) is a common malignancy, with an estimated 79000 incident cases in the US during 2022 (57). The relationship between urinary tract infections (UTIs) and the development of renal cell carcinoma (RCC) remains an area of ongoing investigation (57–59). In one retrospective study, Parker et al. found a positive association between

the history of UTIs and the development of renal cell carcinoma. This association was particularly pronounced in men with a history of smoking, suggesting a potential synergistic effect between these two risk factors (60).

While UTIs have been proposed as a potential risk factor for RCC, the recent identification of a distinct urinary tract microbiome suggests a more complex interplay between the microbiota and the kidney (8). This interaction remains insufficiently explored in the context of RCC pathogenesis.

Recent technological advancements now enable the identification of specific bacterial species in the urinary tract, opening opportunities for further research into the role of the urinary microbiome in RCC occurrence. By analyzing microbial communities within the urinary tracts of individuals both with and without RCC, researchers may better understand the possible connection between UTIs, the urinary microbiome, and RCC development.

CONCLUSIONS

This review has highlighted the intricate connections between the urobiome and genitourinary cancers, underscoring its potential role in disease development and progression. However, translating this knowledge into clinical applications requires us to address several key challenges. Firstly, we must move beyond simple associations and establish definitive causal links between the composition of the urobiome and the development of cancer. This necessitates robust research, including longitudinal studies and advanced analytical techniques, to unravel the complex interplay between the urobiome, host factors, and disease pathogenesis. Secondly, identifying reliable microbial biomarkers for risk assessment and early diagnosis is crucial. This will enable the development of targeted screening and prevention strategies for individuals at high risk of developing genitourinary cancers. Finally, we must integrate our understanding of the urobiome with other emerging fields, such as immunotherapy and precision oncology. This could lead to the development of personalized treatment strategies that leverage the urobiome to enhance therapeutic efficacy and minimize adverse effects.

In conclusion, the urobiome holds immense promise for revolutionizing our approach to genitourinary cancers. By addressing these fundamental challenges, we can pave the way for a future where the urobiome is harnessed to improve patient outcomes and transform the landscape of cancer care.

Funding

None

Acknowledgments

None

Conflict of interest

The authors declare that they have no conflict of interest.

REFERENCES

1. Siegel RL, Miller KD, Fuchs HE, Jemal A. Cancer Statistics, 2021. *CA Cancer J Clin.* 2021;71(1):7-33. doi:10.3322/caac.21654
2. Soria F, Shariat SF, Lerner SP, et al. Epidemiology, diagnosis, preoperative evaluation and prognostic assessment of upper-tract urothelial carcinoma (UTUC). *World J Urol.* 2017;35(3):379-387. doi:10.1007/s00345-016-1928-x
3. Mu N, Jylhä C, Axelsson T, Sydén F, Brehmer M, Tham E. Patient-specific targeted analysis of circulating tumour DNA in plasma is feasible and may be a potential biomarker in UTUC. *World J Urol.* 2023;41(12). doi:10.1007/s00345-023-04583-w
4. Nally E, Young M, Chauhan V, et al. Upper Tract Urothelial Carcinoma (UTUC): Prevalence, Impact and Management Challenge. *Cancer management and research.* 2024;16. doi:10.2147/CMAR.S445529
5. Jain A, Nalavenkata S, Nahm C, Yuen L, Di Mascio D, Kim L. A diagnostic and management conundrum in a rare case of a small renal mass UTUC with IVC and bilateral renal vein tumour thrombus. *Urol Case Rep.* 2021;39:101817. doi:10.1016/j.eucr.2021.101817
6. Colin P, Koenig P, Ouzzane A, et al. Environmental factors involved in carcinogenesis of urothelial cell carcinomas of the upper urinary tract. *BJU Int.* 2009;104(10):1436-1440. doi:10.1111/j.1464-410X.2009.08838.x
7. Zappia J, Yong C, Slaven J, et al. Survival Outcomes by Race Following Surgical Treatment for Upper Tract Urothelial Carcinoma. *Clin Genitourin Cancer.* 2024;22(6):102220. doi:10.1016/j.clgc.2024.102220

8. Zganjar AJ, Thiel DD, Lyon TD. Diagnosis, workup, and risk stratification of upper tract urothelial carcinoma. *Transl Androl Urol.* 2023;12(9):1456-1468. doi:10.21037/tau-23-45
9. Kumar R, Kumar Airon R, Mittal A, Singal R, Sharma K, Singal S. Evaluation of Multidetector Computed Tomography in Haematuria. *Maedica (Bucur).* 2017;12(2):87-94.
10. Cerrato C, Pandolfo SD, Autorino R, et al. Gender-specific counselling of patients with upper tract urothelial carcinoma and Lynch syndrome. *World J Urol.* Published online March 24, 2023. doi:10.1007/s00345-023-04344-9
11. Roupřet M, Seisen T, Birtle AJ, et al. European Association of Urology Guidelines on Upper Urinary Tract Urothelial Carcinoma: 2023 Update. *Eur Urol.* Published online March 24, 2023:S0302-2838(23)02652-0. doi:10.1016/j.eururo.2023.03.013
12. Coleman JA, Clark PE, Bixler BR, et al. Diagnosis and Management of Non-Metastatic Upper Tract Urothelial Carcinoma: AUA/SUO Guideline. *J Urol.* 2023;209(6):1071-1081. doi:10.1097/JU.0000000000003480
13. Wu Z, Li M, Wang L, et al. Neoadjuvant systemic therapy in patients undergoing nephroureterectomy for urothelial cancer: a multidisciplinary systematic review and critical analysis. *Minerva Urol Nephrol.* 2022;74(5). doi:10.23736/S2724-6051.22.04659-6
14. Grob G, Rogers D, Pandolfo SD, et al. Oncologic outcomes following radical nephroureterectomy for upper tract urothelial carcinoma: a literature review. *Transl Androl Urol.* 2023;12(8):1351-1362. doi:10.21037/tau-22-882
15. Moretti L, Bizzoca D, Vitale E, et al. Gender and socio-economic issues in the clinical assessment of orthopaedic patients during the covid-19 pandemic. *European Journal of Musculoskeletal Diseases.* 2022;11(1):15-21.
16. Siegel RL, Miller KD, Jemal A. Cancer statistics, 2020. *CA Cancer J Clin.* 2020;70(1):7-30. doi:10.3322/caac.21590
17. Shariat SF, Favaretto RL, Gupta A, et al. Gender differences in radical nephroureterectomy for upper tract urothelial carcinoma. *World J Urol.* 2011;29(4):481-486. doi:10.1007/s00345-010-0594-7
18. Almås B, Halvorsen OJ, Johannesen TB, Beisland C. Higher than expected and significantly increasing incidence of upper tract urothelial carcinoma. A population based study. *World J Urol.* 2021;39(9):3385-3391. doi:10.1007/s00345-020-03576-3
19. Nishiyama N, Hotta H, Takahashi A, et al. Upper tract urothelial carcinoma following intravesical bacillus Calmette-Guérin therapy for nonmuscle-invasive bladder cancer: Results from a multi-institutional retrospective study. *Urol Oncol.* 2018;36(6):306.e9-306.e15. doi:10.1016/j.urolonc.2018.02.009
20. Sanderson KM, Roupřet M. Upper urinary tract tumour after radical cystectomy for transitional cell carcinoma of the bladder: an update on the risk factors, surveillance regimens and treatments. *BJU Int.* 2007;100(1):11-16. doi:10.1111/j.1464-410X.2007.06841.x
21. EAU Guidelines on Upper Urinary Tract Urothelial Cell Carcinoma - INTRODUCTION - Uroweb. Uroweb - European Association of Urology. Accessed September 4, 2023. <https://uroweb.org/guidelines/upper-urinary-tract-urothelial-cell-carcinoma/chapter/introduction>
22. Diagnosis and Management of Non-Metastatic Upper Tract Urothelial Carcinoma: AUA/SUO Guideline - American Urological Association. Accessed September 4, 2023. <https://www.auanet.org/guidelines-and-quality/guidelines/non-metastatic-upper-tract-urothelial-carcinoma>
23. Dickman KG, Fritsche HM, Grollman AP, Thalmann GN, Catto J. Epidemiology and Risk Factors for Upper Urinary Urothelial Cancers. In: Shariat SF, Xylinas E, eds. Upper Tract Urothelial Carcinoma. *Springer*; 2015:1-30. doi:10.1007/978-1-4939-1501-9_1
24. Zaitse M, Kawachi I, Takeuchi T, Kobayashi Y. Alcohol consumption and risk of upper-tract urothelial cancer. *Cancer Epidemiol.* 2017;48:36-40. doi:10.1016/j.canep.2017.03.002
25. Metcalfe MJ, Petros FG, Rao P, et al. Universal Point of Care Testing for Lynch Syndrome in Patients with Upper Tract Urothelial Carcinoma. *J Urol.* 2018;199(1):60-65. doi:10.1016/j.juro.2017.08.002
26. Umar A, Boland CR, Terdiman JP, et al. Revised Bethesda Guidelines for hereditary nonpolyposis colorectal cancer (Lynch syndrome) and microsatellite instability. *J Natl Cancer Inst.* 2004;96(4):261-268. doi:10.1093/jnci/djh034
27. Rai BP, Luis Dominguez Escrig J, Vale L, et al. Systematic Review of the Incidence of and Risk Factors for Urothelial Cancers and Renal Cell Carcinoma Among Patients with Haematuria. *Eur Urol.* 2022;82(2):182-192. doi:10.1016/j.eururo.2022.03.027

28. Baard J, Cormio L, Cavadas V, et al. Contemporary patterns of presentation, diagnostics and management of upper tract urothelial cancer in 101 centres: the Clinical Research Office of the Endourological Society Global upper tract urothelial carcinoma registry. *Curr Opin Urol.* 2021;31(4):354-362. doi:10.1097/MOU.0000000000000899
29. Jakus D, Šolić I, Borovac JA, Šitum M. The influence of the initial clinical presentation of upper tract urothelial carcinoma on histopathological tumor features. *Int Urol Nephrol.* Published online November 28, 2023. doi:10.1007/s11255-023-03883-9
30. Rud E, Galtung KF, Lauritzen PM, Baco E, Flatabø T, Sandbæk G. Examining the upper urinary tract in patients with hematuria-time to revise the CT urography protocol? *Eur Radiol.* 2020;30(3):1664-1670. doi:10.1007/s00330-019-06521-0
31. Janisch F, Shariat SF, Baltzer P, et al. Diagnostic performance of multidetector computed tomographic (MDCTU) in upper tract urothelial carcinoma (UTUC): a systematic review and meta-analysis. *World J Urol.* 2020;38(5):1165-1175. doi:10.1007/s00345-019-02875-8
32. Tsikitas LA, Hopstone MD, Raman A, Duddalwar V. Imaging in Upper Tract Urothelial Carcinoma: A Review. *Cancers (Basel).* 2023;15(20):5040. doi:10.3390/cancers15205040
33. Razavi SA, Sadigh G, Kelly AM, Cronin P. Comparative effectiveness of imaging modalities for the diagnosis of upper and lower urinary tract malignancy: a critically appraised topic. *Acad Radiol.* 2012;19(9):1134-1140. doi:10.1016/j.acra.2012.05.004
34. Potretzke AM, Knight BA, Vetter JM, et al. Diagnostic Utility of Selective Upper Tract Urinary Cytology: A Systematic Review and Meta-analysis of the Literature. *Urology.* 2016;96:35-43. doi:10.1016/j.urology.2016.04.030
35. Nardelli C, Aveta A, Pandolfo SD, et al. Microbiome Profiling in Bladder Cancer Patients Using the First-morning Urine Sample. *Eur Urol Open Sci.* 2024;59:18-26. doi:10.1016/j.euros.2023.11.003
36. Russo F, Esposito S, Tripodi L, et al. Insights into *Porphyromonas somerae* in Bladder Cancer Patients: Urinary Detection by ddPCR. *Microorganisms.* 2024;12(10):2049. doi:10.3390/microorganisms12102049
37. Di Stasio D, Lauritano D, Minervini G, et al. Management of denture stomatitis: A narrative review. *Journal of Biological Regulators and Homeostatic Agents.* 2018;32(2):113-116.
38. Pandolfo SD, Cilio S, Aveta A, et al. Upper Tract Urothelial Cancer: Guideline of Guidelines. *Cancers (Basel).* 2024;16(6):1115. doi:10.3390/cancers16061115
39. Loizzo D, Pandolfo SD, Del Giudice F, et al. Ureterscopy and tailored treatment of upper tract urothelial cancer: recent advances and unmet needs. *BJU International.* 2022;130(1):35-37. doi:10.1111/bju.15746
40. Vashistha V, Shabsigh A, Zynger DL. Utility and diagnostic accuracy of ureteroscopic biopsy in upper tract urothelial carcinoma. *Arch Pathol Lab Med.* 2013;137(3):400-407. doi:10.5858/arpa.2012-0136-OA
41. Antonelli A, Bennardo F, Brancaccio Y, Barone S, Femiano F, Nucci L, Minervini G, Fortunato L, Attanasio F, Giudice A. Can Bone Compaction Improve Primary Implant Stability? An In Vitro Comparative Study with Osseodensification Technique. *Applied Sciences.* 2020; 10(23):8623. <https://doi.org/10.3390/app10238623>
42. Voskuilen CS, Schweitzer D, Jensen JB, et al. Diagnostic Value of 18F-fluorodeoxyglucose Positron Emission Tomography with Computed Tomography for Lymph Node Staging in Patients with Upper Tract Urothelial Carcinoma. *Eur Urol Oncol.* 2020;3(1):73-79. doi:10.1016/j.euo.2019.09.004
43. Rouprêt M, Colin P, Yates DR. A new proposal to risk stratify urothelial carcinomas of the upper urinary tract (UTUCs) in a predefinitive treatment setting: low-risk versus high-risk UTUCs. *Eur Urol.* 2014;66(2):181-183. doi:10.1016/j.eururo.2013.12.007
44. Bignante G, Orsini A, Lasorsa F, et al. Robotic-assisted surgery for the treatment of urologic cancers: recent advances. *Expert Rev Med Devices.* Published online December 1, 2024. doi:10.1080/17434440.2024.2435546
45. Messer JC, Terrell JD, Herman MP, et al. Multi-institutional validation of the ability of preoperative hydronephrosis to predict advanced pathologic tumor stage in upper-tract urothelial carcinoma. *Urol Oncol.* 2013;31(6):904-908. doi:10.1016/j.urolonc.2011.07.011
46. Foerster B, Abufaraj M, Mari A, et al. The Performance of Tumor Size as Risk Stratification Parameter in Upper Tract Urothelial Carcinoma (UTUC). *Clin Genitourin Cancer.* 2021;19(3):272.e1-272.e7. doi:10.1016/j.clgc.2020.09.002
47. Shigeta K, Kikuchi E, Abe T, et al. A Novel Risk-based Approach Simulating Oncological Surveillance After Radical Nephroureterectomy in Patients with Upper Tract Urothelial Carcinoma. *Eur Urol Oncol.* 2020;3(6):756-763. doi:10.1016/j.euo.2019.06.021

48. Xia L, Taylor BL, Pulido JE, Guzzo TJ. Impact of surgical waiting time on survival in patients with upper tract urothelial carcinoma: A national cancer database study. *Urol Oncol*. 2018;36(1):10.e15-10.e22. doi:10.1016/j.urolonc.2017.09.013
49. Aziz A, Fritsche HM, Gakis G, et al. Comparative analysis of comorbidity and performance indices for prediction of oncological outcomes in patients with upper tract urothelial carcinoma who were treated with radical nephroureterectomy. *Urol Oncol*. 2014;32(8):1141-1150. doi:10.1016/j.urolonc.2014.04.008
50. Aveta A, Cacciapuoti C, Barone B, et al. The Impact of Meat Intake on Bladder Cancer Incidence: Is It Really a Relevant Risk? *Cancers*. 2022;14(19):4775. doi:10.3390/cancers14194775
51. Calace FP, Napolitano L, Arcaniolo D, et al. Micro-Ultrasound in the Diagnosis and Staging of Prostate and Bladder Cancer: A Comprehensive Review. *Medicina (Kaunas)*. 2022;58(11):1624. doi:10.3390/medicina58111624