LAB PUBLISHER RESEARCH IN SCIENCE

EJMD European Journal of Musculoskeletal Diseases

Case Report

A DIGITAL PALATIN LANDMARK: AN INNOVATIVE TOOL IN FULL-ARCH DIGITAL IMPLANTS SURGICAL PLANNING AND PROSTHETIC REHABILITATION

T. Tealdo[1], M. Zarantonello[2], M. Bevilacqua[3], C. Alberti[4], D. De Santis[2] And F. Gelpi[2-5]

[1]Private practitioner in Alba, Cuneo, Italy;
[2]Head and Neck Department, Department of Surgery, Dentistry, Pediatrics and Gynecology, University of Verona, Verona, Italy;
[3]Private practitioner in Boves, Cuneo, Italy;
[4]Private practitioner in Rosà, Vicenza, Italy
[5]Private practitioner in Caldiero, Verona, Italy;

Correspondence to:
Morris Zarantonello, DDS
Head and Neck Department,
Department of Surgery, Dentistry, Pediatrics and Gynecology,
University of Verona,
Verona, Italy
E-mail: morris.zarantonello@hotmail.it

ABSTRACT

The main aim of this paper, which focuses on a clinical case report, is to evaluate and discuss the effectiveness of using a palatal landmark as a tool to improve the overall digital workflow in immediate-loading primary prosthetics for full-arch structures. The palatine landmark allows the vertical dimension to be maintained from the pre-extraction phase to the delivery phase of the temporary restoration. The patient is treated with 4 implants in the premaxilla and 2 in the pterygoid area (these 2 posterior fixtures are extremely important to dramatically reduce the posterior cantilever). In this case report, no particular issues were encountered in matching the pre-/intra-/post-surgery digital full arch impression using a photogrammetry device (Shining Elite Plus). The temporary Toronto was applied within the expected timeframe (less than 24 hours) and the patient was highly satisfied. The palatine landmark allows an excellent matching of the digital files, the pre-extraction optical impression, with the one generated with the shining elite photogrammetry. This photogrammetry can be applied to both the four post-extraction anterior implants and the posterior implants to generate a file for the primary/temporary prosthetic structure and also for the permanent one. This new photogrammetry device allows for more predictable, precise impression-taking, even with an open flap. To read soft tissue (such as the fornix in the lower arch, which is often mobile), "caps" are used, which are placed directly above the MUA immediately after the fixture is inserted. Despite the extremely limited number of patients, at the moment in our opinion, there are no other better techniques or devices that allow full-arch completion of complex cases in such a short time, and with such satisfactory results reported by patients themselves. We hope this first article will serve as a starting point for sharing and further exploring this new technique, also in NZP® rehabilitation in atrophic patients.

Received: 29 July 2026
Accepted: 01 September 2026

© 2026 The Author(s). Published by LAB Publishers. This is an open-access article distributed under the terms of the Creative Commons Attribution-Non Commercial 4.0 International License (CC BY-NC 4.0).
Disclosure: All authors report no conflicts of interest relevant to this article.

KEYWORDS: *precision and stability in fully digital planning, analogical and digital reference in full arch impression, full arch rehabilitation, digital matching, intra oral photogrammetry, NZP®*

INTRODUCTION

In modern daily practice, regardless of immediate full-arch implant-supported prosthetic rehabilitation, the use of digital devices and technologies is increasingly prevalent, increasingly abandoning the "traditional" workflow based on materials, impression-taking, casting, and the design of handcrafted, analog prosthetic devices (1-5).

A stubborn aspiration leads clinicians to seek a fully digital approach as soon as possible, even if not all cases can be included in it at the moment.

Often, the clinician faces the need to pre-emptively redefine the patient's aesthetics (gummy smiles to be corrected, periodontal terminal dentition) and not having stable spatial references capable of maintaining the initial information. Any surgical procedure could affect the entire workflow, leading to a loss of information about the vertical dimension.

In 2024, the Authors proposed a hybrid protocol (digital and analog) for the detection of palatal wrinkles (plaster impression plus silicon impression material) to identify a stable area for further digital matching of derived STL files (6).

A clinical challenge often encountered in digital workflow is maintaining or increasing the vertical dimension of occlusion in the patient being treated. Compromised periodontal teeth that may have become progressively inclined over the years (sometimes aggravated by loss of posterior teeth) may require correcting the patient's VDO, requiring an increase (7, 8).

In other cases, a gummy smile that requires corrective osteoplasty at the same time as implant placement without losing the VDO represents an indication for the use of a device capable of accompanying the various surgical steps and maintaining the initial information useful to both the clinician and the laboratory technician to deliver a temporary prosthetic device that adheres to the conceived and shared plan (9). Most digital technologies start as stand-alone solutions but are soon implemented in broader digital networks (10).

These issues, already present in traditional dentistry, are increasingly diminishing thanks to the increasingly widespread and sophisticated use of digital technology. What has been presented in this paper is an idea proposed by Dr. Tealdo's team (Palatine EYE) in which the main aim is to use a fixed, screwed, artificial, non-moving, easily recognizable landmark (reference point) in an area not subject to structural changes (such as mobile gingiva, or attached gingiva subjected to local-regional anesthetic injection) that can serve as a pivotal point for pre- and post-operative digital impressions. It can be integrated into both digital impression, such as photogrammetry, and traditional registration.

This can yield a virtually perfect match between the initial pre-operative impression and the intra-operative impression, enabling immediate full-arch loading with an extremely precise arch and requiring only limited checks and adjustments.

MATERIALS AND METHODS

A 55-year-old patient with a medical history positive for asthma (ASA 2) came to us seeking resolution of his long-neglected dental problems. The concerns he reported were aesthetic and functional due to a detrimental terminal dentition.

After an intra- and extra-oral clinical and radiographic examination (CBCT), intra- and extra-oral photographs (Fig. 1-7) showing the smile, but not the gums, and initial optical impressions (which also have forensic medical value), we have made a diagnosis of upper terminal dentition, a severe generalized periodontitis, and severe tooth mobility.

All the clinical, radiological and digital detected data gave to the Authors the indication for a full arch implants supported screws retained rehabilitation; more specifically with insertion of six implants, two of which in the pterygoid region (to permanently eliminate a significant posterior cantilever), and subsequent immediate loading rehabilitation (which, in our case, occurred within 24 hours of the end of the implants placement). The temporary rehabilitation does not yet use pterygoid implants as supports. This will occur during the construction of the definitive upper rehabilitation.

Since this is a case due to the extraction of all the teeth, the patient would have lost the vertical dimension, it was decided to resort to the palatal landmark: a stable device in the vault of the palate corresponding to the posterior portion to the palatine wrinkles on the midline, whose mathematics are easily recognized by the intraoral scanner engineering software and which allows information to be collected in the pre-surgical phase and transferred to the dental laboratory in the post-surgical phase.

Fig. 1. *Initial smile exposure highlines the features of the patient.*

Fig. 2. *Intraoral aspect of the terminal dentition.*

Fig. 3. *Lateral right side aspect of the intraoral detrimental condition.*

Fig. 4. *Lateral left side aspect of the intraoral detrimental condition.*

Fig. 5. *Occlusal aspect of the distal missing teeth.*

Fig. 6. *Initial Orthopantomography of the patient very useful to be evaluated according the Bedrossian algoritm.*

Fig. 7. *Inter arch relationship in Maximun Intercuspidation.*

The anatomical reference is to be inserted before surgery, once anesthesia has been administered to the patient, with the terminal teeth still in place, by inserting it at the mid-palate with the appropriate driver. Subsequently, both arches are scanned (Aoral Scan Shining Elite 3D, Hangzhou, China), and the vertical dimension is measured at maximum intercuspation. The procedure then continues with tooth extraction and implant insertion (Biomax fixtures for anterior implants and Ptery-fit from Noris for pterygoid implants, as well as low-profile components) (Fig. 8-22).

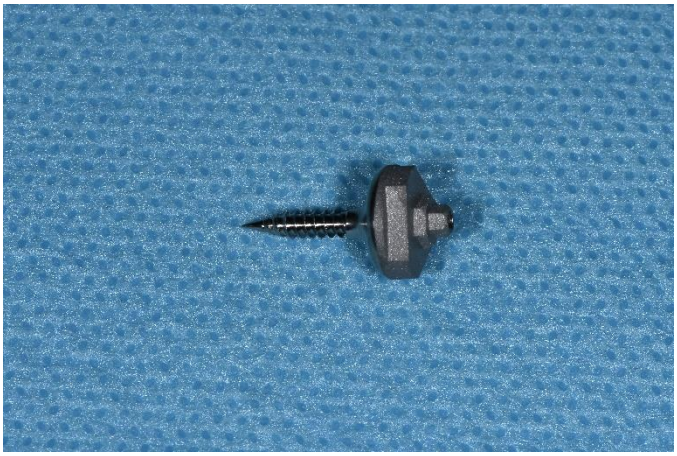

Fig. 8. *The digital palatal landmark is so close and similar to a screw.*

The flaps are sutured, and the arch is rescanned first with the healing cups in place and then, after removing them, the scanning is repeated with the scan flags conceived for photogrammetry (Aoral Scan Shining Elite 3D Hangzhou-China). During scanning, the constant presence of this digital palatal reference, which remains stable relative to the initial position, enables the association of images at zero time with post-intervention images with extreme precision. Moreover, the anatomical reference allows us to take the new vertical dimension by retracing the initial vertical position, and then we proceed to create the artifact.

Fig. 9. *This device is conceived to be placed and scanned before the surgery.*

Fig. 10. *Teeth extraction means an information loss and subsequently a VDO loss.*

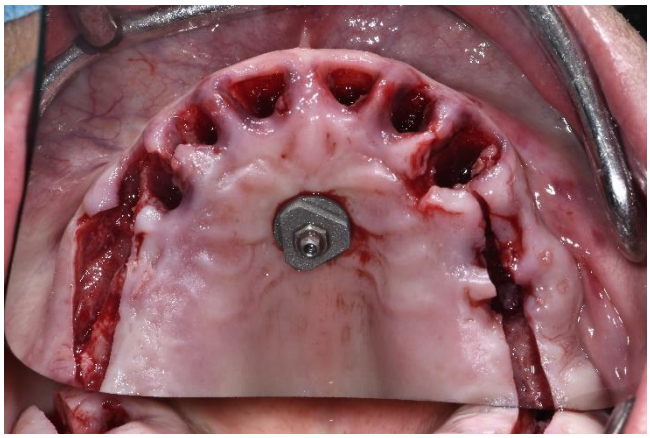

Fig. 11. *The palatal landmark is stable in the palatal bone to ensure a correct data flow.*

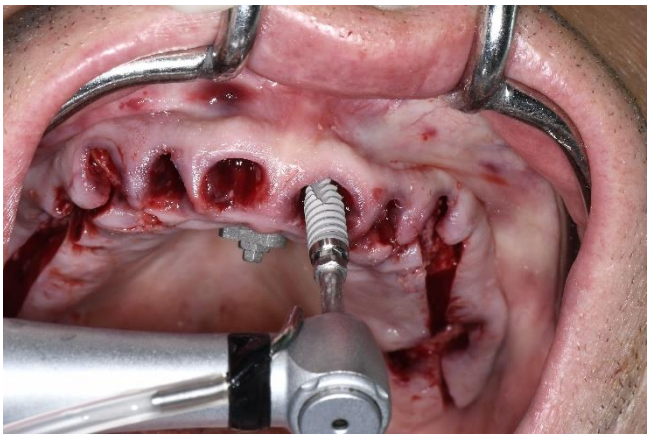

Fig. 12. *Implant placement should not interfere with the palatal landmark.*

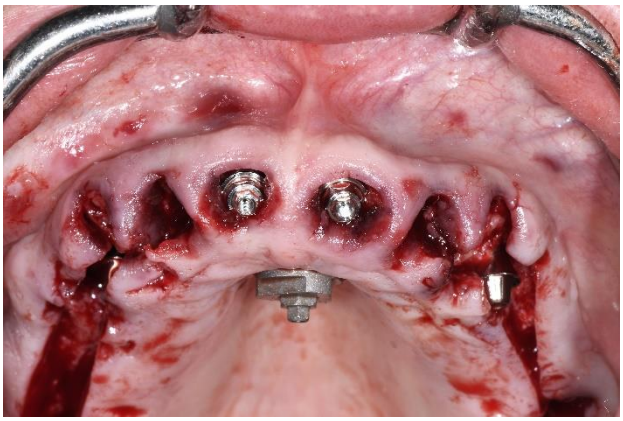

Fig. 13. *The low-profile abutments are screwed on the implants and the palatal eye is still in the palatine vault.*

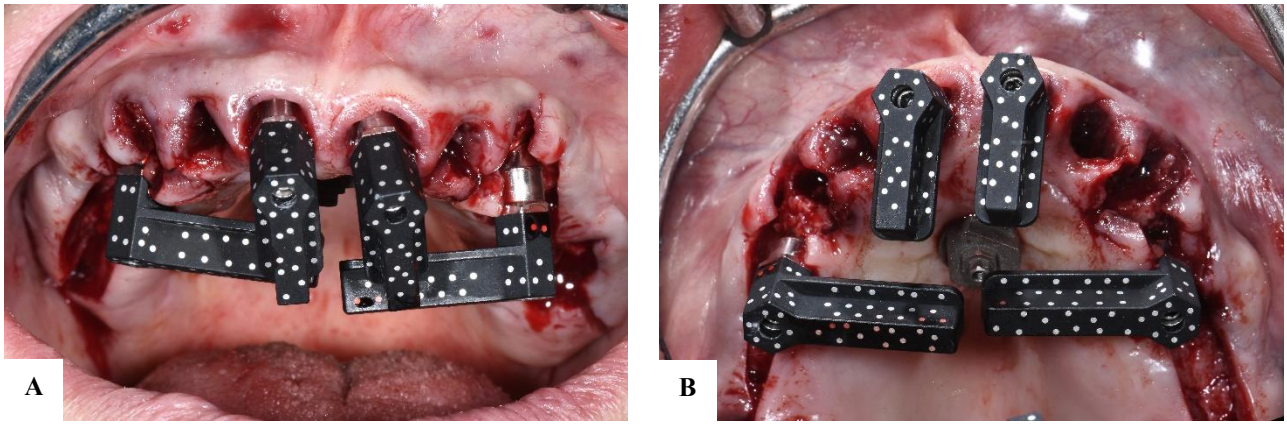

Fig. 14a, b. *The photogrammetric flags are screwed on the low-profile abutments according to a convergent pattern.*

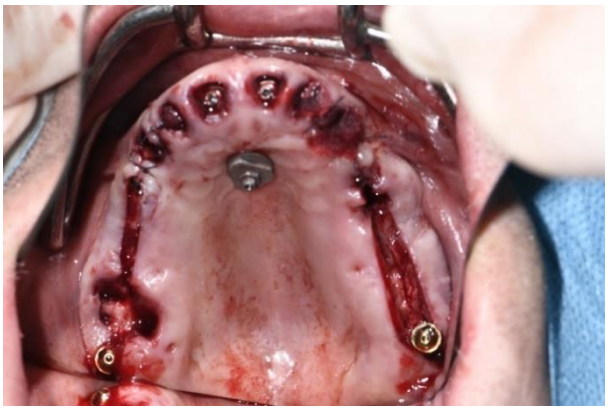

Fig. 15. *After the intraoral scan, two distal pterygoid implants are placed in the distal area to allow a cantilever reduction to the final restoration.*

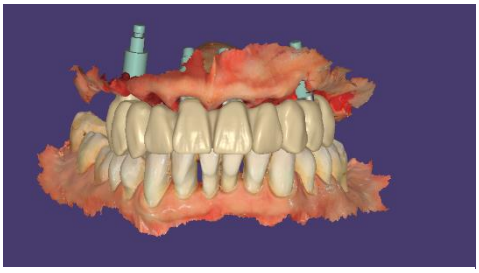

Fig. 16. *The whole data collection process allows the laboratory technician to design the temporary restoration according to a fully digital system.*

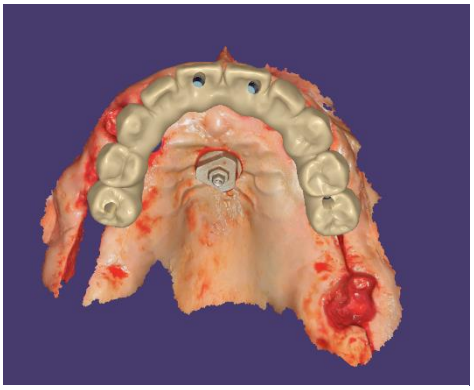

Fig. 17. *The palatal aspect of the digital reference point confirms VDO reference and maintenance.*

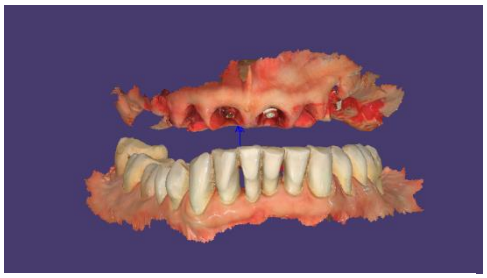

Fig. 18. *This Exocad's Tooth extraction tool confirms the role of the palatal landmark to maintain the VDO.*

Fig. 19. *Frontal aspect of the provisional printed restoration.*

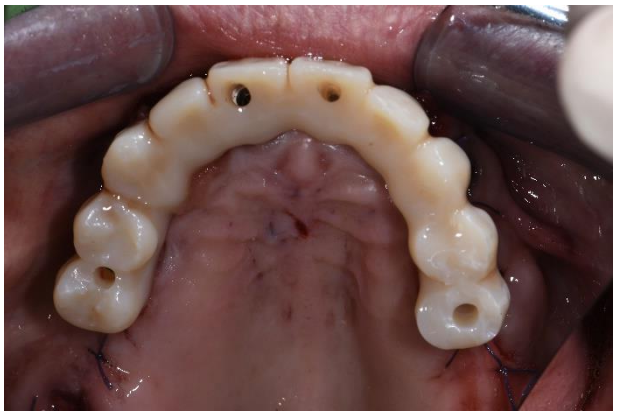

Fig. 20. *Occlusal aspect of the provisional printed restoration.*

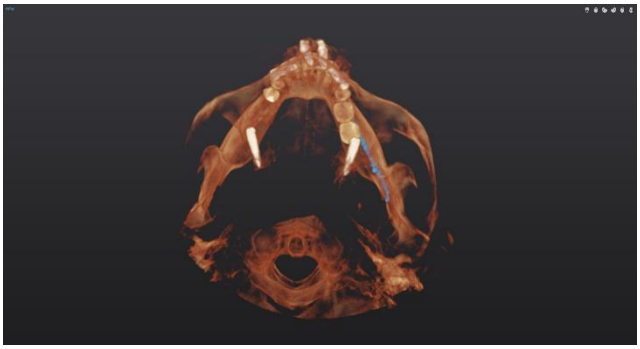

Fig. 21. *The 3D Cbct scan confirmed the right apex engagement of the pterygoid implants in the pterygoid region.*

Fig. 22. *The orthopantomography for a radiological check of the provisional prosthetic fitting.*

The current case was used with photogrammetry, AoralScan Shining Elite 3D Hangzhou-China Shining Elite, intraoral, which features those black flags with white dots on its surface, which the software automatically recognizes. With the flap open, transverse rod copies are applied that protrude from the tissues and are then replaced with these flags, which converge toward the center without overlapping, three-dimensionally, to create a convergence area approximately equal to a 5-cent euro coin. The scan is performed following the occlusal axis, the long axis of the scan abutment, until the software recognizes the position of each individual flag in three dimensions. These are automatically converted according to the manufacturer's instructions for individual implants.

The temporary restoration is printed, not milled, and extends to the 4 conventionally angled post-extraction anterior implants and does not involve the pterygoid implants, which are usually used only as support during the construction phase of the definitive restoration. Pterygoid implants can also be recorded with a plaster impression or digitally using photogrammetry, with the same black-and-white flag structures.

After a 3-month healing period (Fig. 23), a functional and aesthetic reevaluation of the printed temporary rehabilitation was mandatory to plan the features of the final prosthetic restoration. In this case, the available prosthetic space has allowed the authors to plan a natural rehabilitation using an assembling technique (class IV according to Tealdo's classification) (9).

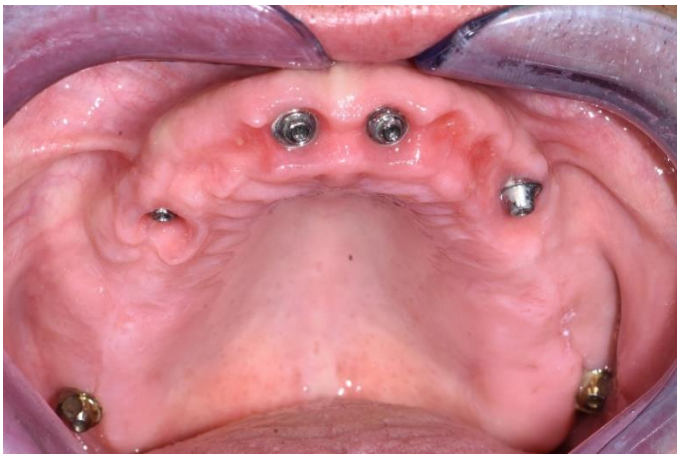

Fig. 23. *The healed upper jaw after a healing period of three months.*

Intraoral photogrammetry (AoralScan Shining Elite 3D, Hangzhou, China) also confirmed, in this second phase, its reliability and precision in detecting the distal pterygoid implant position. The final restoration envisages the use of angled screws (as shown by the red dots on the palatal aspect) (Fig. 24). A final RX scan confirmed the precision of the whole final restoration (Fig. 25, 26).

Fig. 24. *Occlusal aspect of the final prosthetic restoration with red dots for the angled screws.*

Fig. 25. *Intraoral frontal aspect after the delivery of the assembled restoration.*

Fig. 26. *Radiological evaluation of the final delivery.*

RESULTS

The precision of the prosthetic device exceeded expectations; it took no more than a few minutes in the chair to adjust some small details related to occlusal contact. There was a non-painful and soft contact between the "upper" surface of the prosthesis and the patient's sutured gums, which were still naturally healing. The patient reported no pain during the screwing/insertion phase of the prosthesis. The availability of professional hygiene products (such as interdental brushes and dental floss) was smooth, and he reported no food or liquids passing through the area in the following days.

He stated that he was satisfied (even though it was a temporary device) with the aesthetics of his smile, the width and depth of the smile, the interrelationships between the various teeth, the absence of palatal bulk, and no difficulty speaking. All clinical results are also summarized in Figure 22.

DISCUSSION

The Digital Flow represents an effective and disruptive ally in approaching clinical complexity. It is based on the almost daily introduction of new devices and technologies proposed for the market to address critical issues affecting dental practice.

It is essential to understand (especially in complex cases such as in an anthropic patient candidate to NZP® rehabilitation) which strategies to implement to maintain the vertical dimension (10-12). The palatal landmark could be the solution. This allows us to work on different STL files and then automatically match them because the scanner recognizes the landmark, which can be used both for analog impressions (accepting pick-up copying) and for digital impressions because it is structured to receive the scan abutment.

The technological evolution of materials to be used with 3D printers (13-16) will soon allow the realization of a provisional implants with direct connections (thus eliminating the need to insert metal tubes inside) and to proceed with the final product, avoiding the analog phase of gluing: it will no longer be necessary to take plaster impressions, create positioning keys for transfers with photo-curing acrylic material, and glue the tubes inside the structure on an analog model obtained from the traditional analog plaster impression. It will no longer be necessary to take plaster impressions, create positioning keys for transfers with photo-curing acrylic, and glue the tubes inside the structure on an analog model obtained from the traditional analog plaster impression. This anatomical reference (17-18) can also be used if one prefers to continue with the plaster impressions; it is inserted at zero time once the anesthesia is completed, the arches are scanned in vertical dimension, and the teeth are extracted. Then, if you prefer to proceed with a plaster impression, that anatomical reference has the MUA on top, you position a transfer or repositionable or pick-up (this we still have to build) in such a way that it is suitable for height, take the plaster impression (therefore, the transfer of that object remains in the impression). Next, you insert an analog of that scan body into the impression, so you have the anatomical reference that coincides with the initial scan, even on the plaster impression, and then you can couple them. We are closing a loop that speeds up the procedure and allows us to produce a provisional implant with the direct connections already printed; therefore, there is no need to glue the tubes, but we now need an appropriate material.

The palatal landmark is a newly developed device that enables precise, stable, reliable, and repeatable matching of initial STL files with post-surgical ones. Our research group recently introduced the use of palatal rugae in a similar manner, combined with analog plaster and polyvinyl-siloxane impressions.[6] It also serves as a stable, reliable, and precise mandibular and maxillary landmark thanks to its geometry, easily recognized by intraoral scanner reading software. After mounting in the digital articulator, the laboratory can use commercially available planning software (e.g., Exocad) to proceed with digital planning or confirm the initial diagnostic wax-up, then proceed with molding or milling the prosthetic restoration. There are now materials on the market that are printed for temporary restorations, eliminating the analog step of gluing the links. These materials can also print the MUA connections directly into the temporary material.

Photogrammetry exists in the extra-oral IBIC or Fast Map format (i.d.) mounted on X-Nav, and in intra-oral versions such as Shining Elite (used by us), which uses this dual-scanning system. The first ABT scans without flags, which stand out from the results, especially during surgery, and those with flags already pre-loaded into the software, are available. Once the black horizontal bar with white dots is recognized, the software converts it from red to green (this indicates that the impression has been recorded correctly). The software begins to recognize the three-dimensionality of implants compatible with all MUAs. Therefore, they are not associated with a single dental line; they are universal. Late on, the laboratory must then trace it back to the implant line to which it belongs, with the mathematical data loaded and acquired.

CONCLUSIONS

Despite the extremely limited number of patients at the moment (December 2025), in our opinion, there are no better techniques or devices that allow full-arch completion of complex cases in such a short time, with such satisfactory results reported by patients themselves. We hope this first article will serve as a starting point for sharing and further exploring this new technique.

Funding
This research received no funding from private or public agencies.

Conflicts of Interest
The authors declare no conflicts of interest.

Acknowledgments
We thank Biomax for its support, especially Dr. Roberto Riboldi.

REFERENCES

1. Joda T, Zarone F, Ferrari M. The complete digital workflow in fixed prosthodontics: a systematic review. *BMC Oral Health.* 2017 Sep 19;17(1):124. doi: 10.1186/s12903-017-0415-0.
2. Papaspyridakos P, De Souza A, Finkelman M, Sicilia E, Gotsis S, Chen YW, Vazouras K, Chochlidakis K. Digital vs Conventional Full-Arch Implant Impressions: A Retrospective Analysis of 36 Edentulous Jaws. *J Prosthodont*. 2023 Apr;32(4):325-330. doi: 10.1111/jopr.13536.
3. Venezia P, Torsello F, Santomauro V, Dibello V, Cavalcanti R. Full Digital Workflow for the Treatment of an Edentulous Patient with Guided Surgery, Immediate Loading and 3D-Printed Hybrid Prosthesis: The BARI Technique 2.0. A Case Report. *Int J Environ Res Public Health.* 2019 Dec 17;16(24):5160. doi: 10.3390/ijerph16245160.
4. Yang JW, Liu Q, Yue ZG, Hou JX, Afrashtehfar KI. Digital Workflow for Full-Arch Immediate Implant Placement Using a Stackable Surgical Guide Fabricated Using SLM Technology. *J Prosthodont.* 2021 Oct;30(8):645-650. doi: 10.1111/jopr.13375.
5. Roberts M, Shull F, Schiner B. Maxillary full-arch reconstruction using a sequenced digital workflow. *J Esthet Restor Dent.* 2020 Jun;32(4):336-356. doi: 10.1111/jerd.12582.
6. Tealdo T, Bevilacqua M, Scaglione L, Alberti C, Montagna P, Gelpi F. A fully digital planning and manufacturing of an aesthetically conceived and guided full-arch implant-supported rehabilitation. *European Journal of Musculoskeletal Diseases*. 2024;13(2):138-150.
7. Stanley M, Paz AG, Miguel I, Coachman C. Fully digital workflow, integrating dental scan, smile design and CAD-CAM: case report. *BMC Oral Health.* 2018 Aug 7;18(1):134.
8. Zhivago P, Turkyilmaz I, Yun S. Aesthetic and functional rehabilitation of collapsed occlusal vertical dimension using an advanced digital workflow. *Prim Dent J.* 2023 Mar;12(1):57-61.
9. 2.Gelpi F, Alberti C, Bevilacqua M, Montagna P, Santis D, Tealdo T. A novel classification and a chartmaking decision flow proposal for fixed fullarch implantsupported prosthesis. *European Journal of Musculoskeletal Diseases*. 2024;13(1):17-40.
10. Schierz O, Hirsch C, Krey KF, Ganss C, Kämmerer PW, Schlenz MA. Digital dentistry and its impact on oral health-related quality of life. *J Evid Based Dent Pract.* 2024 Jan;24(1S):101946. doi: 10.1016/j.jebdp.2023.101946.
11. Gittelson GL. Vertical dimension of occlusion in implant dentistry: significance and approach. *Implant Dent.* 2002;11(1):33-40.
12. Li J, Galli M, Chen Z, Venezia P, Mangano F, Lepidi L. A novel digital technique for maintaining maxillomandibular relations in fixed prosthetic rehabilitations. *J Dent.* 2021 Nov;114:103798.
13. Kihara H, Sugawara S, Yokota J, Takafuji K, Fukazawa S, Tamada A, Hatakeyama W, Kondo H. Applications of three-dimensional printers in prosthetic dentistry. *J Oral Sci.* 2021 Jun 29;63(3):212-216.
14. Nulty A. A comparison of trueness and precision of 12 3D printers used in dentistry. *BDJ Open*. 2022 May 26;8(1):14.
15. Mangano FG, Admakin O, Bonacina M, Biaggini F, Farronato D, Lerner H. Accuracy of 6 Desktop 3D Printers in Dentistry: A Comparative In Vitro Study. *Eur J Prosthodont Restor Dent.* 2020 May 28;28(2):75-85.
16. Hegedus T, Kreuter P, Kismarczi-Antalffy AA, Demeter T, Banyai D, Vegh A, Geczi Z, Hermann P, Payer M, Zsembery A, Al-Hassiny A, Mukaddam K, Herber V, Jakse N, Vegh D. User Experience and Sustainability of 3D Printing in Dentistry. *Int J Environ Res Public Health.* 2022 Feb 9;19(4):1921.
17. Cascales ÁF, Ballester MJM, Fernández-Navarro J, Oteo-Morilla C, Del Cacho-Salvador G, Burgos-Artizzu XP, Piedra-Cascón W. Clinical accuracy of three intraoral scanners for determining an increased vertical dimension of occlusion: A pilot study. *J Prosthet Dent*. 2025 Oct 14:S0022-3913(25)00763-2.
18. Sheppard IM, Sheppard SM. Vertical dimension measurements. *J Prosthet Dent.* 1975 Sep;34(3):269-77.