

AN “ON-THE-TABLE” RECONSTRUCTION TECHNIQUE TO TREAT A COMMUNATED ARTICULAR METACARPAL BONE FRACTURE. A CASE REPORT

M. Saracco¹, V. Circiello² and E. Jannelli³

¹Department of Public Health, Division of Orthopaedic Surgery, University of Naples “Federico II”, Naples, Italy;

²Orthopedics and Traumatology 1, Maria Vittoria Hospital, NHS City of Turin, Turin, Italy

³Department of Orthopaedics, Fondazione IRCCS Policlinico San Matteo, Pavia, Italy

Correspondence to:

Michela Saracco, MD
Department of Public Health,
Division of Orthopaedic Surgery,
University of Naples “Federico II”
Via Sergio Pansini, 5
Naples, Italy
e-mail: michelasaracco@gmail.com

ABSTRACT

Metacarpal bone fractures are the most common hand injuries. An “On-the-table” reconstruction is a reliable technique to treat comminuted articular fractures in non-weight-bearing bones. We report the case of a young polytraumatized patient with a complex fracture of the distal part of the second metacarpal bone treated with an “on-the-table” reconstruction since the general clinical conditions did not allow more complex or multistep conventional reconstructive techniques. This surgical procedure allowed us to obtain good clinical and radiographical results without bone resorption or complications. Case series could confirm the reliability of the proposed method.

KEYWORDS: *on-the-table reconstruction, hand injuries, metacarpal bone fractures, comminuted articular fractures*

INTRODUCTION

Metacarpal bone fractures are the most common hand injuries, accounting for 40% of all hand traumatic lesions. Men aged 15-30 have the highest incidence of metacarpal injuries due to road accidents or occupational injuries. Different mechanisms of injury are involved, but high-energy traumas may result in multiple or comminuted fractures.

Wounds may indicate open fractures or concomitant soft tissue injury, such as tendon laceration or neurovascular injury. Crash injuries or multiple fractures are associated with a higher risk of compartmental syndrome. So, complex metacarpal fractures can be functionally disabling. Pain, dorsal hand swelling, and loss of motion are typical symptoms of this pathological condition. X-rays are the first level diagnostic exams: anteroposterior (AP) or posteroanterior (PA), semi-pronation, and lateral views are mandatory to avoid false negativity of the diagnostic tool. In the case of articular/complex fractures that need surgical approaches, a CT-scan execution is essential to correctly plan the procedure (1).

In case of severe comminution, bone loss can be difficult to manage. Reconstructive techniques with microsurgical bone flaps or with simple cortico-cancellous bone grafts, for example, from the iliac crest, are known and

widely used. Cementless induced membrane technique is also described in case of destructive injuries, such as gunshot ones (2-4).

In other body districts, however, as in the case of the radial head or distal humerus, extreme reconstructive techniques have recently gained ground, such as “on-the-table” reconstruction and subsequent re-implantation and osteosynthesis of the fracture fragments. In non-load-bearing bones, these techniques have given good radiographic and functional results, postponing more complex techniques to possible failures (5-7).

We report the case of a young polytraumatized patient with a complex fracture of the distal part of the second metacarpal bone treated with an “on-the-table” reconstruction since the general clinical conditions did not allow more complex or multistep conventional reconstructive techniques. The patient provided written informed consent to allow the disclosure of his case. As far as the authors know, no other similar cases are described in the literature.

CASE REPORT

A 19-year-old Caucasian male patient polytraumatized in a motorcycle-to-car road accident reported a commotional head injury, abdominal injury, and deformity of the left hand with a wound in the volar and inter-digital space between the second and third finger. The patient's clinical history was collected with the help of family members. He was a student and an occasional manual worker. The dominant limb was reported to be the right. He was a smoker (20 cigarettes a day) and a habitual drinker of beer, wine, and spirits. No other diseases were reported.

Investigation and emergency treatment

Upon arrival in the emergency room, he underwent a total body computerized tomography (CT) scan, radiography in two projections of the left hand, and subsequent CT scan of the hand with three-dimensional (3D) reconstructions. Tests performed revealed a cerebral hematoma. He also reported a fragmentary articular fracture of the distal end of the second metacarpal bone (Fig. 1).

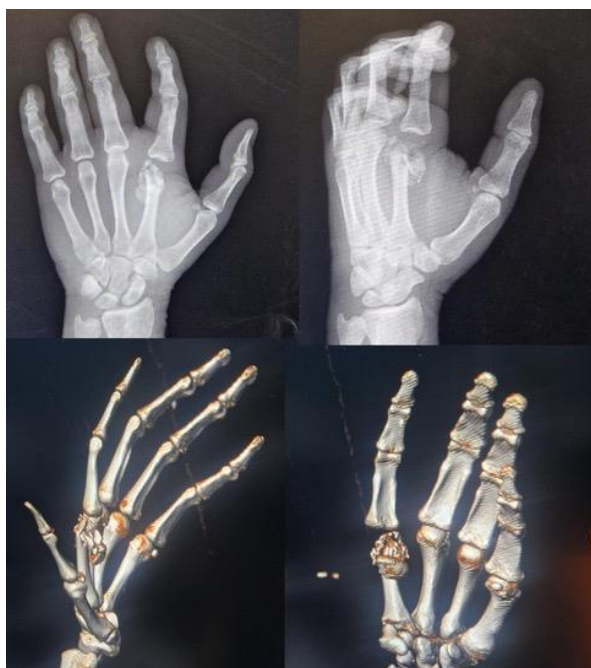

Fig. 1. Pre-operative X-rays and CT scan.

Exposure was localized in the volar and interdigital space between the second and the third finger with the injury of the inter-metacarpal ligament, classified as Gustilo IIIA. There was no appreciable major vascular-nerve damage. The hand injury was initially treated with abundant washing, debridement, skin closure as possible, and splint stabilization. Antibiotic prophylaxis was also administered with a first-generation cephalosporin (cefazolin 2 grams/8 hours) and an aminoglycoside (gentamycin 80 mg/12 hours) for five days after the trauma.

In consideration of the severity of the patient's neurological condition, an intensive care hospitalization lasting about two weeks followed. The patient also underwent splenectomy due to an active intra-abdominal bleeding 7 days after his arrival. Therefore, the orthopedic surgery was postponed.

Treatment

The orthopedic surgical procedure was performed 2 weeks after the trauma. Antibiotic prophylaxis with cefazolin 2g was performed 1 hour before surgery. In supine decubitus, under plexus anesthesia with the left upper limb on a radiolucent table and with a tourniquet at the root of the limb, a curvilinear dorsal skin incision of about 5 cm in length was

made at the second metacarpal bone. After the incision of the subcutaneous tissue, the lesion of the sagittal band and the intermetacarpal ligament, the severe comminution of the bone metaphysis, and the displaced and divided metacarpal head in 2 parts were highlighted (Fig. 2).

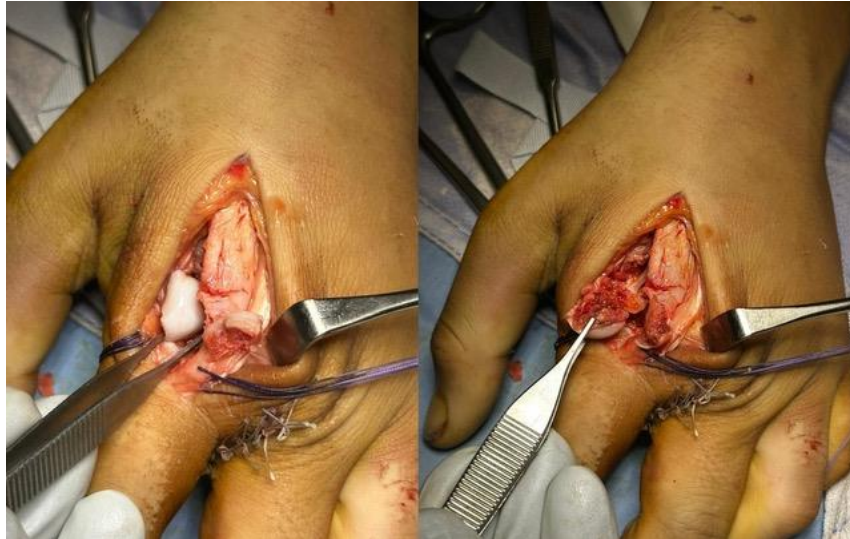

Fig. 2. *Damage assessment during surgery.*

The surgical procedure consisted of an “on-the-table” reconstruction of the metacarpal head, bone grafting with autologous bone to reconstruct the metaphysis using fracture fragments supporting the metacarpal head, and performing the ORIF (open reduction and internal fixation).

The bone surfaces were then bloodied and the bone graft was implanted, taking care to arrange the cortical anteriorly and trying to regain the physiological metacarpal bone length. Bone fragments were customized to fit at best the bone loss (Fig. 3). Then, the second metacarpal head was re-composed using micro-forceps and a temporary K-wire of small diameter (0.6mm) (Fig. 4).

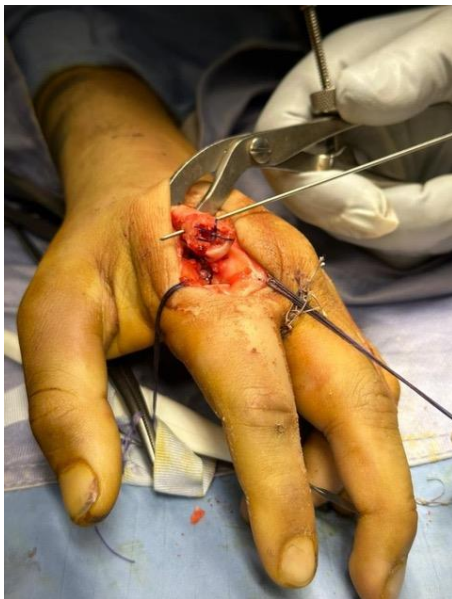

Fig. 3. *Metaphyseal reconstruction of the second metacarpal bone.*

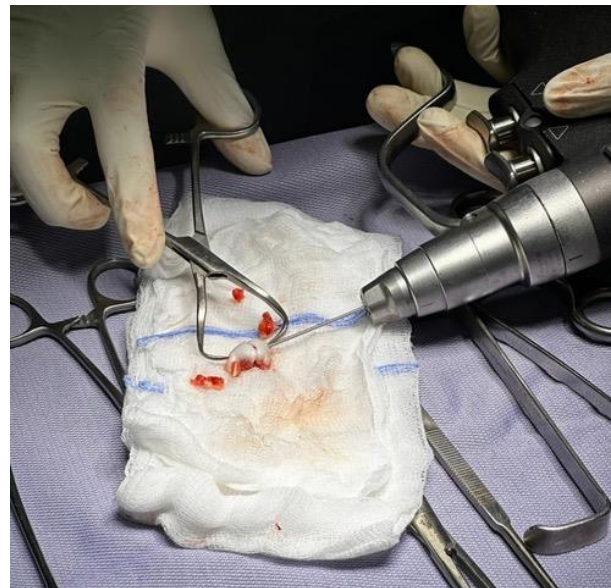

Fig. 4. *On-the-table reconstruction of the second metacarpal bone head.*

The reconstructed head was placed on the grafted second metacarpal metaphysis (Fig. 5). Finally, osteosynthesis was performed with Hofer (GMBH & CO KG Jahnstrasse, Fürstenfeld, Austria) INTEOS® Mini fragments metacarpal plate 2.0mm 4+4 holes and angular stability screws, under x-ray fluoroscopy control (Fig. 6).

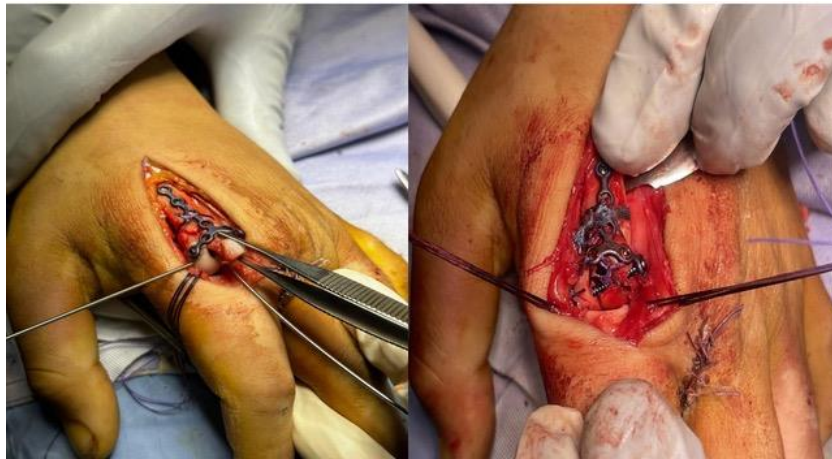

Fig. 5. *Joint surface reconstruction and ORIF.*

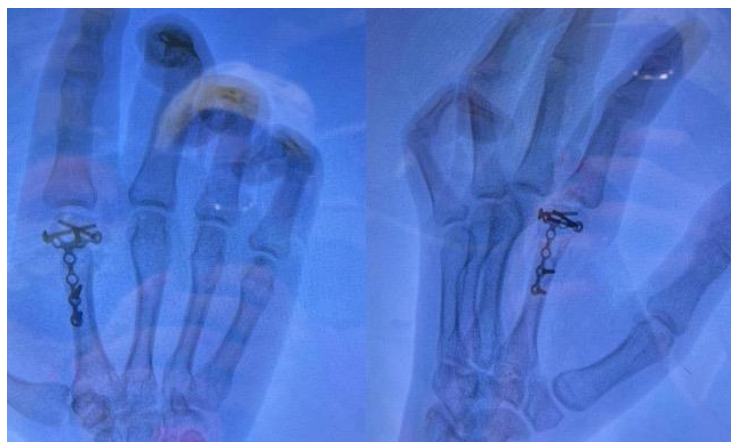

Fig. 6. *Post-operative X-rays.*

At the end of the procedure, the sagittal band and the intermetacarpal ligament were reconstructed as far as possible (Fig. 7). The tourniquet was released, and an accurate hemostasis was conducted before the skin suture.

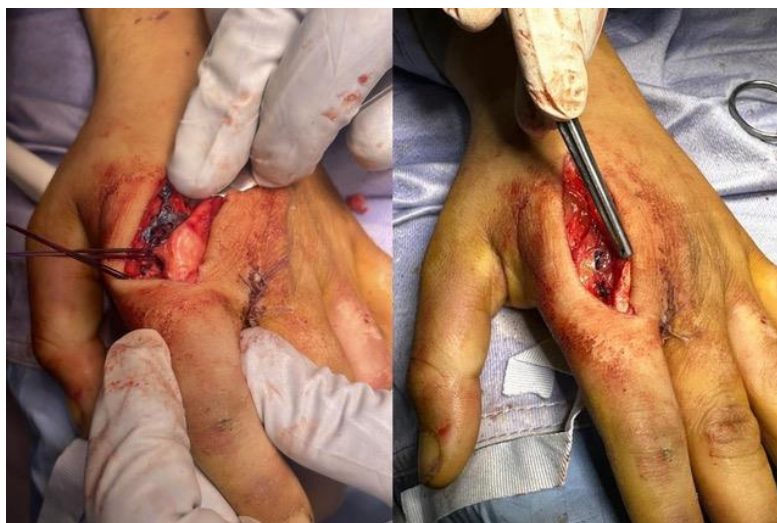

Fig. 7. *Sagittal band and extension system reconstruction.*

The postoperative course was regular, and the removal of the sutures took place about 2 weeks after the surgical procedure. A splint was used for the first 3 weeks, and then the patient was allowed to move his left hand actively.

Outcomes

At 1-month radiographical and clinical evaluations, tools used for osteosynthesis were intact and in place, even if there was a modest resorption of the autologous bone graft (Fig. 8). The patient did not complain of pain on mobilization despite having a second finger flexion-extension deficit. No signs of vasculo-nervous deficits or infection. Therefore, he began the physiotherapy treatment.

At the check-up 3 months after the surgical procedure, the plate and screws appeared in place with no more bone graft resorption. The patient reported no pain and improvement in the second finger's range of motion. Scars were in order. He returned to manual work. The DASH score was 47, VAS 5 under exertion, and 2 at rest. At 6-month follow-up, tools were in place with complete bone healing, without further resorption of the bone graft (Fig. 9).

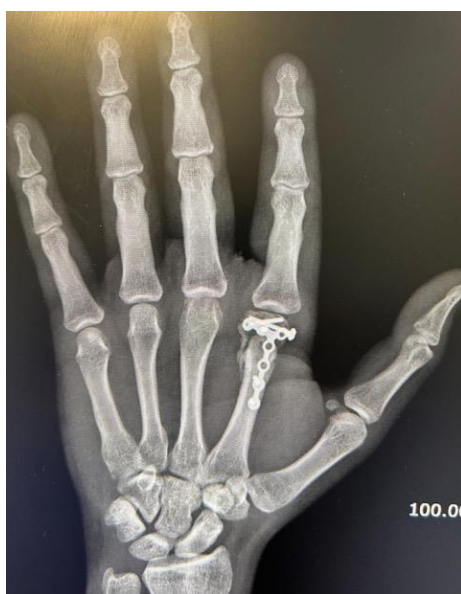

Fig. 8. X-ray at 1-month follow-up.

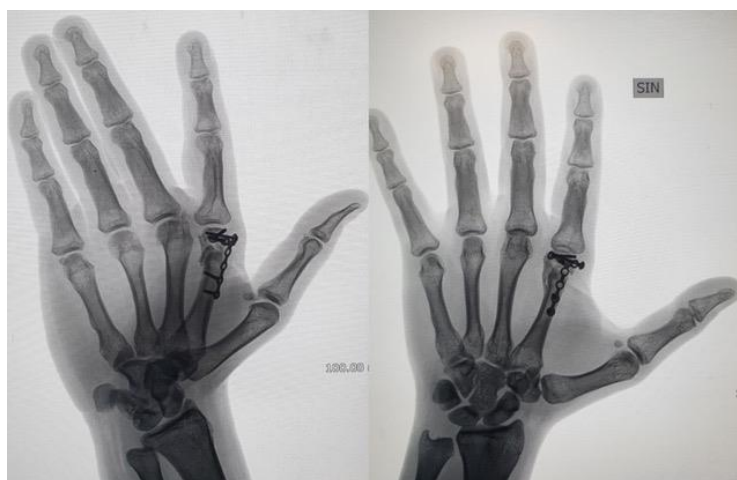


Fig. 9. X-rays at 6-month follow-up.

The second finger's length was satisfactory, with no rotation defects. The patient did not show any deficit of the second finger extension with a mild metacarpophalangeal joint flexion deficit, which was well tolerated (Fig. 10). He was then judged clinically and radiographically healed. The DASH score was 23, VAS 2 under exertion, 0 at rest. A strength test (JAMAR test) was also performed, and a force equal to 37 kg was generated with the grip.

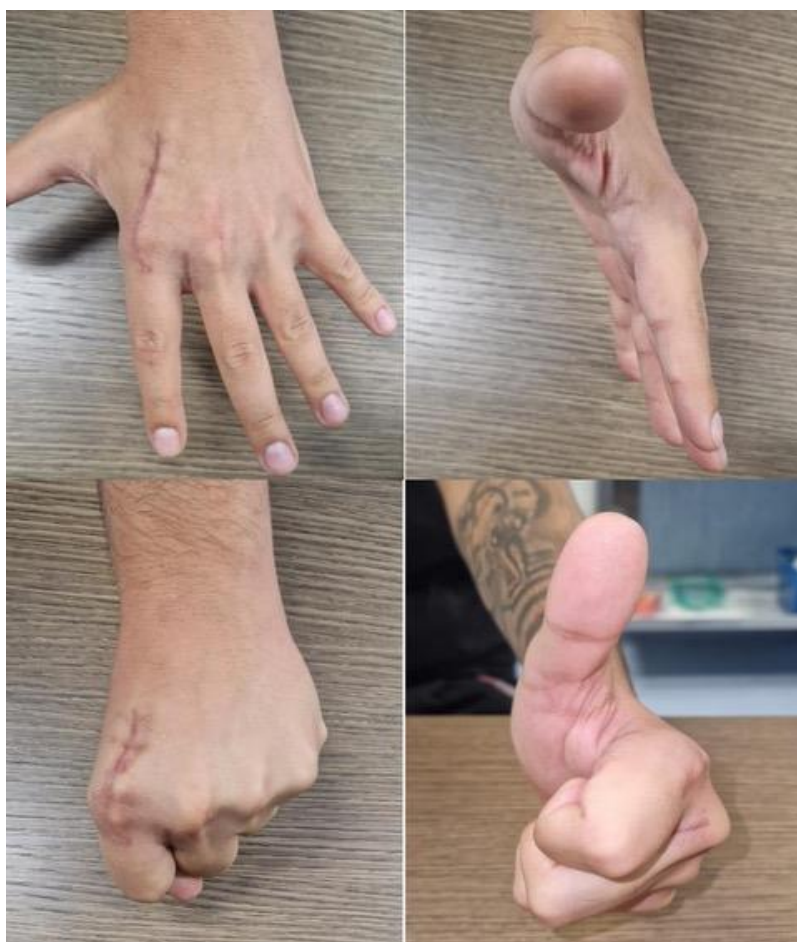

Fig. 10. *Clinical examination at 6-month follow-up.*

DISCUSSION

Hand injuries could be disabling, affecting the patient's quality of life. In addition, high-energy trauma often leads to soft tissue and bone loss. As said, bone autologous grafting or microsurgical bone flaps are the most commonly used surgical technique in this field.

Javier Zurriaga-Carda et al. reported a case of metacarpal head reconstruction for a comminuted fracture using a chondrocostal graft. This technique allows for stable fixation and optimal osteointegration, but it is a demanding procedure with few complications during its harvesting, only in the case of skilled surgeons (8).

Microsurgical bone flaps are more commonly used in the case of metacarpal non-union, as reported by Christen et al. These authors described the application of the periosteal medial femoral condyle free flap to treat five patients. Free flaps are long-lasting surgical procedures that require specific microsurgical skills and large teams (9). On the other hand, the use of non-vascularized bone grafts is widely used when it is necessary to fill bone losses, but they are not a guarantee of results since these grafts are non-vascularized bone and are challenging to apply if the bone loss affects the articular surface. Furthermore, the graft must be taken from another body area, e.g., the distal radius or iliac crest, which, in any case, requires two surgical steps (10).

More expensive techniques are also proposed in case of oncological resections or failures of previous reconstructive surgical procedures. They consist of 3D-printed custom-made prosthesis to repair the bone defect (11). However, there are conditions such as the one described in this case report in which it is impossible to subject the patient to prolonged interventions due to associated clinical conditions or when the articular surface is involved, and it is necessary to reconstruct it.

The “on-the-table” reconstruction we proposed was adapted from similar techniques proposed for other anatomical districts, mainly the elbow and, in any case, for unloaded bone segments. It consists of a faithful reproduction of the articular surface by recomposing the fracture fragments and their subsequent repositioning on the metaphysis.

In 2015, Kiran Kumar et al. described 6 cases of Mason III radial head fracture treated with this reconstruction, obtaining good clinical results without complications, which required a surgical revision. The reconstructed articular bone acts as a spacer (12).

Kastenberger et al. reported 14 patients treated with “on-the-table” reconstruction for Mason III and IV radial head fracture. Complete bone union was achieved in 9 cases, partial union in 4 cases, and non-union in one case. One patient needed a revision surgery due to the non-union and implant breakage. This is a reliable technique to restore joint alignment and maintain radial length with a low risk of complications (13). The same results are reported by Everding et al. in their paper (14).

To the authors' knowledge, no cases of metacarpal joint fractures were reconstructed using the same technique. The clinical and radiographic results of our patient at 6 months are optimal, and not only has there been no resorption, but, on the contrary, clear signs of bone healing are visible. Thus, this technique could be a viable option for treating complex cases because we can expect the same results as obtained in the case of radial head reconstruction. However, more cases are needed to confirm this. In any case, the proposed technique could be implemented, for example, using surgical glue, as reported by Chen et al. (15). Surgical glue could upgrade bone fragment coaptation, allowing better healing.

CONCLUSIONS

An “On-the-table” reconstruction in hand traumatology can give good clinical and functional results. It is an excellent option when it is not possible to perform more complex techniques or when it's necessary to postpone them to later times in case of failure. Case series could confirm the reliability of the method.

REFERENCES

1. Lambi AG, Rowland RJ, Brady NW, Rodriguez DE, Mercer DM. Metacarpal fractures. *J Hand Surg Eur.* 2023 Sep;48(2_suppl):42S-50S. doi: 10.1177/17531934231184119.
2. Dimitriou R, Jones E, McGonagle D, Giannoudis PV. Bone regeneration: current concepts and future directions. *BMC Med.* 2011 May 31;9:66. doi: 10.1186/1741-7015-9-66.
3. Kohlhauser M, Vasilyeva A, Kamolz LP, Bürger HK, Schintler M. Metacarpophalangeal Joint Reconstruction of a Complex Hand Injury with a Vascularized Lateral Femoral Condyle Flap Using an Individualized 3D Printed Model-A Case Report. *J Pers Med.* 2023 Nov 2;13(11):1570. doi: 10.3390/jpm13111570.
4. Murison JC, Pfister G, Amar S, Rigal S, Mathieu L. Metacarpal bone reconstruction by a cementless induced membrane technique. *Hand Surg Rehabil.* 2019 Apr;38(2):83-86. doi: 10.1016/j.hansur.2019.01.002
5. Koh IH, Hong JJ, Kang HJ, Choi YR, Kim JS. Minimum four-year clinical outcomes after on-table reconstruction technique for Dubberley type III in coronal shear fractures of the capitellum and trochlea: a report of 10 patients. *BMC Musculoskelet Disord.* 2024 Jul 3;25(1):514. doi: 10.1186/s12891-024-07628-2.
6. Kiran Kumar GN, Sharma G, Farooque K, Sharma V, Jain V, Singh R, Morey V. On-table reconstruction and fixation of Mason type III radial head fractures. *Chin J Traumatol.* 2015;18(5):288-92. doi: 10.1016/j.cjtee.2015.11.005.
7. Businger A, Ruedi TP, Sommer C. On-table reconstruction of comminuted fractures of the radial head. *Injury.* 2010 Jun;41(6):583-8. doi: 10.1016/j.injury.2009.10.026.
8. Zurriaga-Carda J, Rojas-Díaz R, Puertes-Almenar L, Silvestre-Muñoz A. Chondrocostal grafting for lateral osteochondral injury of the metacarpal head. *Orthop Traumatol Surg Res.* 2020 Apr;106(2):325-328. doi: 10.1016/j.otsr.2019.12.006.
9. Christen T, Krähenbühl SM, Müller CT, Durand S. Periosteal medial femoral condyle free flap for metacarpal nonunion. *Microsurgery.* 2022 Mar;42(3):226-230. doi: 10.1002/micr.30826.
10. Liodaki E, Kraemer R, Mailaender P, Stang F. The Use of Bone Graft Substitute in Hand Surgery: A Prospective Observational Study. *Medicine (Baltimore).* 2016 Jun;95(24):e3631. doi: 10.1097/MD.0000000000003631.

11. Xu L, Qin H, Cheng Z, Jiang WB, Tan J, Luo X, Huang W. 3D-printed personalised prostheses for bone defect repair and reconstruction following resection of metacarpal giant cell tumours. *Ann Transl Med.* 2021 Sep;9(18):1421. doi: 10.21037/atm-21-3400.
12. Kiran Kumar GN, Sharma G, Farooque K, Sharma V, Jain V, Singh R, Morey V. On-table reconstruction and fixation of Mason type III radial head fractures. *Chin J Traumatol.* 2015;18(5):288-92. doi: 10.1016/j.cjtee.2015.11.005.
13. Kastenberger T, Kaiser P, Spicher A, Stock K, Benedikt S, Schmidle G, Arora R. Clinical and radiological outcome of Mason-Johnston types III and IV radial head fractures treated by an on-table reconstruction. *J Orthop Surg Res.* 2022 Nov 19;17(1):503. doi: 10.1186/s13018-022-03394-w.
14. Everding J, Raschke MJ, Polgart P, Grüneweller N, Wähnert D, Schliemann B. Ex situ reconstruction of comminuted radial head fractures: is it truly worth a try? *Arch Orthop Trauma Surg.* 2019 Dec;139(12):1723-1729. doi: 10.1007/s00402-019-03250-3. Epub 2019 Aug 5. Erratum in: *Arch Orthop Trauma Surg.* 2020 Mar;140(3):441. doi: 10.1007/s00402-019-03330-4.
15. Chen DW, Hu WK, Zhou JQ. Use of surgical glue for Mason type III radial head fractures: A case report. *Medicine (Baltimore).* 2019 May;98(22):e15863. doi: 10.1097/MD.00000000000015863.